

**DATE PRESENTING CLINICAL SIGNS**

4/26/22 Vomiting, regurgitation for 1 week. Increased over previous periodic regurgitation. Also PU/PD. Appetite good, not lethargic. No diarrhea, stool normal. PE unremarkable except for 2 lb weight loss since 2019.

PATIENT

Noel Goble Current Medications: Cerenia 5 mg SC, Ondansetron 5 mg SC during appointment 4/21. Sent home on cerenia 6 mg Po SID, next due 4/22 in PM.

SPECIES

Feline

Radiographs: Lat abdominal xray--does not appear obstructed, stool in colon; decreased detail of SI, possible fluid or other contents in pylorus.

Date of Previous IntraPet Ultrasound: No previous.

Sedation: Not required to complete full diagnostic ultrasound.

Stat Report: Not requested.

BREED

DSH

ULTRASONOGRAPHIC EXAMINATION OF THE ABDOMEN**SEX**

Spayed Female

Urinary System

The urinary bladder is moderately distended with anechoic urine. The Bladder wall, trigone, ureteral papillae and visible urethra (to a depth of 2cm) appear normal with no evidence of wall thickening, mucosal irregularities, masses or cystic calculi.

AGE

10/31/07

The left kidney has a normal shape and size (3.79 cm) with pyelectasia at 0.36 cm. Overall echogenicity is slightly hyperechoic with mildly reduced corticomedullary distinction and a typical 1:3 cortex:medulla ratio. There is no evidence of perinephric inflammation or effusion. There is no evidence of nephroliths, infarcts or hydroureter. Renal vasculature is normal.

WEIGHT

13 lb 2 oz

The right kidney has a normal shape and size (3.31 cm) with mild pyelectasia at 0.23 cm. Overall echogenicity is slightly hyperechoic with poor corticomedullary distinction and a typical 1:3 cortex:medulla ratio. There is no evidence of perinephric inflammation or effusion. There is no evidence of nephroliths, infarcts or hydroureter. Renal vasculature is normal.

INTERPRETED BY

Kathleen Sennello DVM,
MS, Diplomate ACVIM
(Small Animal Internal
Medicine)

Adrenal Glands

The left adrenal gland is normal in size measuring 0.37 cm at the caudal pole. It is observed in its normal position cranial to the left renal artery. It is normal in appearance (uniformly hypoechoic) and shape with no evidence of a mass effect.

IMAGING PERFORMED BY

Rachel Brilhart RDMS

The right adrenal gland is normal in size measuring 0.33 cm at the caudal pole. It is observed in its normal position between the cranial aspect of the right kidney and the caudal vena cava. It is normal in appearance (uniformly hypoechoic) and shape with no evidence of a mass effect.

HOSPITAL NAME

Cat Sense Feline
Hospital

Spleen

The spleen is subjectively normal in size, echotexture is homogenous, and the splenic capsule is smooth with no irregularities. The blood flow through the hilus and splenic parenchyma appears normal. No focal parenchymal abnormalities are visualized.

REFERRING VET

Dr. Tuzo

Liver

The liver is subjectively normal in size, and echogenicity with smooth peripheral margins. The parenchyma is homogenous echotexture. The visible portions of the vasculature and biliary tract appear normal. No focal nodules or cystic lesions are observed.

INVOICE

37158

The gallbladder lumen is moderately distended. The wall of the gall bladder is not thickened and has a smooth mucosal surface. Luminal contents are primarily anechoic. The cystic and common bile ducts are normal/not visible.

Gastrointestinal

The stomach is mildly fluid distended. It measures at a normal thickness of <0.36cm with some variability due to the presence of rugal folds. The distinction of the gastric wall layers is adequate and there is no impression of reduced peristaltic activity. No masses or focal lesions were observed.

The visualized areas of duodenum, jejunum and ileum have a relatively uniform diameter with minimal fluid distension. Wall thickness is normal. Bowel loops follow a curvilinear path with distinct wall layering maintaining the typical 1:3 muscularis:mucosa layer ratio. Jejunum wall measured 0.27 cm. Visualized peristalsis appears appropriate. There were no focal lesions consistent with obstruction or a mass effect observed.

The ileocecal junction was visualized and exhibited normal intact wall layering and is subjectively of normal thickness. Sections of colon are visualized with formed fecal material and gas shadowing distally. There is no observed focal or generalized colon wall thickening or loss of layering.

Pancreas

The pancreas is normal and isoechoic to surrounding mesentery. There is no evidence of nodules or cystic lesions. There is no evidence of regional mesenteric inflammation or fluid.

Free Abdomen

Evaluation of the peritoneal cavity did not reveal any evidence of effusion, or subjective lymphadenomegaly. The Medial iliac nodes appear normal and there was no evidence of a caudal aortic thrombus at the bifurcation. The omentum is of normal uniform echogenicity.

ULTRASONOGRAPHIC FINDINGS

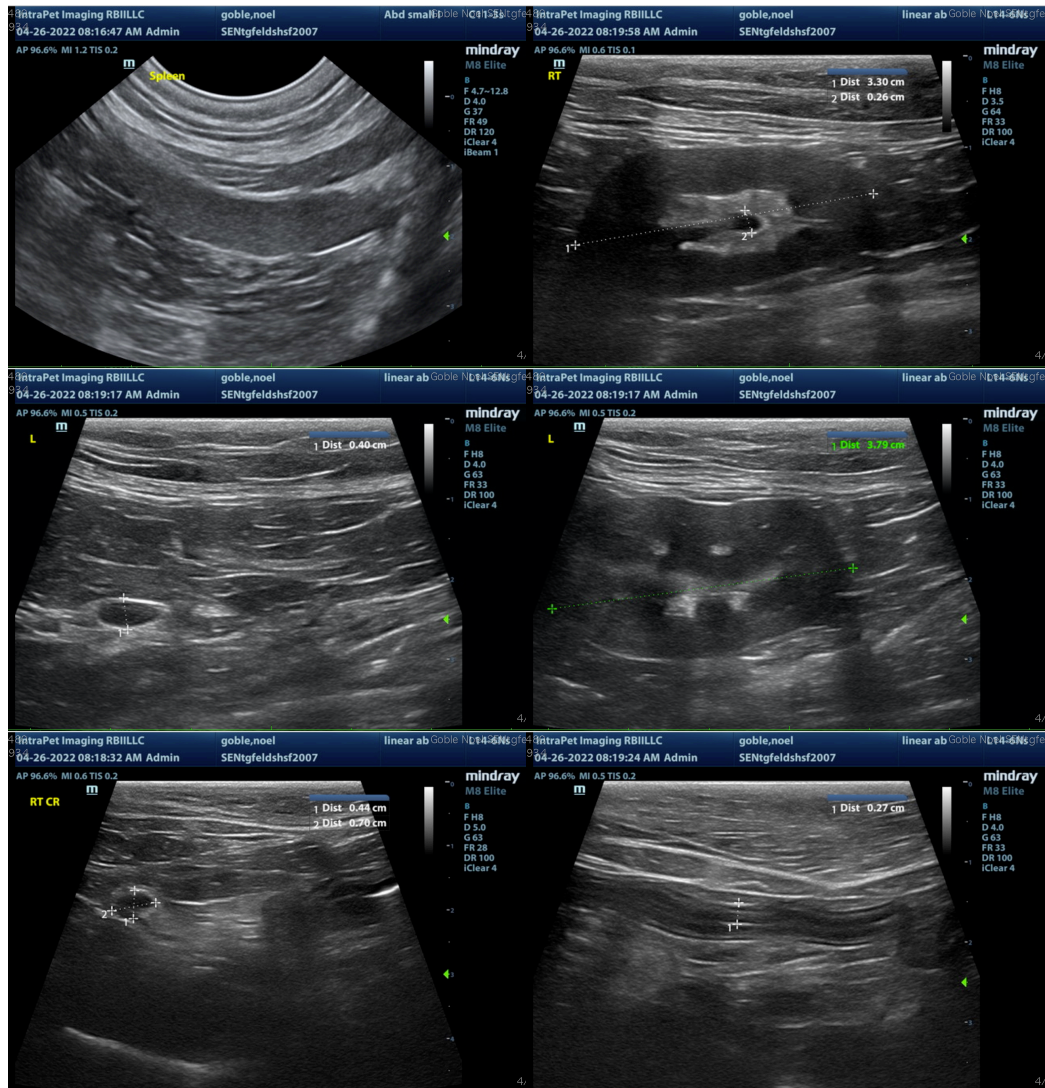
- Decreased corticomedullary distinction in both kidneys with mild bilateral pyelectasia – The bilateral renal findings are consistent with age-related change. Pyelectasia of the left/right kidney could be consistent with pyelonephritis, chronic renal disease, secondary to PU/PD or fluid therapy (if applicable), other.
- Mild fluid distention of the stomach – This is minimal and likely within normal limits, but given the vomiting history, this could be consistent with delayed gastric emptying or less likely a partial outflow tract obstruction (none observed).

INTERPRETATION OF THE FINDINGS & FURTHER RECOMMENDATIONS

An obvious cause for the vomiting and regurgitation noted is not observed. Unfortunately, there are many differentials vomiting that cannot be diagnosed by ultrasound alone. Consider such differentials as food allergy/dietary intolerance, GI parasitism, dietary indiscretion (ingested foreign material), pancreatitis, IBD, and less likely intestinal neoplasia.

- Consider a GI panel to Texas A&M for a qualitative fPLI, TLI, cobalamin and folate to further evaluate the pancreas and small intestine.
- Consider a novel protein/hydrolyzed protein prescription diet.
- Consider symptomatic treatment for gastritis/pancreatitis.
- Recommend thoracic radiographs to evaluate the thoracic esophagus +/- barium swallow to evaluate the stomach, the esophagus, and gastric emptying.
- If symptoms persist, consider an upper GI endoscopy to further evaluate the esophagus, stomach

and small intestine.



The information and recommendations provided are based on the images presented by the referring veterinarian/sonographer. No evaluation can be communicated regarding pathology that was not visible in the image/video clips provided.

Thank you for this referral. If the clinical or image interpretation does not parallel your findings or if I can be of any further assistance please contact me.

Kathleen Sennello DVM,MS, Diplomate ACVIM (Small animal Internal Medicine)
kathleen.sennello@sonopath.com