



PATIENT PRESENTING CLINICAL SIGNS

Oscar Collins Patient has been straining to urinate the last few days and now is unable to urinate at all.

SPECIES

Canine

Abnormal PE/Chem/CBC/UA Results: CBC: Neutrophilia COMP: glucose 149, ggt 15 EPOC: pCO2 27.6, pH 7.478, glucose 149, HCT 56.

BREED

Dachshund

ULTRASONOGRAPHIC EXAMINATION OF THE ABDOMEN

Urinary System

SEX

Male

The urinary bladder is moderately distended with anechoic urine. The Bladder wall is diffusely mildly thickened, and the mucosa is mildly irregular. The trigone, ureteral papillae, and urinary catheter is visualized within the urethra. Findings are most consistent with bacterial cystitis or lack of urine distension. Recommend urinalysis and culture.

AGE

12 yr

The prostate is large, mottled, cystic, and irregular. There is a central area of mottled tissue visualized most consistent with a prostate. This tissue has an intraparenchymal cyst and measures at 4.3 cm x 2.7 cm. Adjacent to the prostatic tissue are two large cystic structures, most consistent with prostatic or pair of prostatic cysts. The more cranial cyst roughly measures at 2.6 cm x 2.04 cm. The more caudal cystic is greater than 3.6 cm x 4 cm. A urinary catheter is visualized within the prostatic urethra and there is surrounding inflammation.

WEIGHT

9.5kg

INTERPRETED BY

Kathleen Sennello DVM,
MS, Diplomate ACVIM
(Small Animal Internal
Medicine)

The left kidney has a normal shape and size (5.34 cm). Overall echogenicity is normal with adequate corticomedullary distinction and a typical 1:3 cortex: medulla ratio. There is no evidence of focal perinephric inflammation or effusion. There is no evidence of pyelectasia, nephroliths, infarcts or hydroureter. Renal vasculature is normal.

The right kidney has a normal shape and size (5.26 cm). Overall echogenicity is normal with adequate corticomedullary distinction and a typical 1:3 cortex: medulla ratio. There is no evidence of focal perinephric inflammation or effusion. There is no evidence of pyelectasia, nephroliths, infarcts or hydroureter. Renal vasculature is normal.

IMAGING PERFORMED BY

Dr. Kuzimski

Adrenal Glands

HOSPITAL NAME

Animal Emergency
Hospital Deland

The region of left adrenal (Cranial to left renal artery) is unremarkable but the adrenal is not distinctly visualized. No evidence of a mass effect.

REFERRING VET

Dr. Kuzimski

The region of the right adrenal (between right cranial kidney and vena cava) is unremarkable, but the adrenal is not distinctly visualized. No evidence of a mass effect.

INVOICE

10191

Spleen

The spleen is subjectively normal in size, echotexture is homogenous, and the splenic capsule is smooth with no irregularities. The blood flow through the hilus and splenic parenchyma appears normal. No focal parenchymal abnormalities are visualized.

DATE

4/25/23

Liver

The liver is subjectively normal in size, and echogenicity with smooth peripheral margins. The parenchyma is homogenous echotexture. The visible portions of the vasculature and biliary tract appear normal. No focal nodules or cystic lesions are observed.



PATIENT

Oscar Collins

The gallbladder lumen is moderately distended. The wall of the gall bladder is not thickened and has a smooth mucosal surface. Luminal contents are mild and primarily anechoic. The cystic and common bile ducts are normal/not visible.

SPECIES

Gastrointestinal

Canine

The stomach contains moderate fluid. It measures at a normal thickness of <0.7cm with some variability due to the presence of rugal folds. The distinction of the gastric wall layers is adequate and there is no impression of reduced peristaltic activity. No masses or focal lesions were observed.

BREED

Dachshund

The visualized areas of duodenum, jejunum and ileum have a relatively uniform diameter with minimal fluid distension. Wall thickness is normal. Bowel loops follow a curvilinear path with distinct wall layering maintaining the typical 1:3 muscularis: mucosa layer ratio. The duodenum measured as normal (0.29 cm), and the jejunum measured as normal (0.25 cm.) Visualized peristalsis appears appropriate.

SEX

Male

There were no focal lesions consistent with obstruction or a mass effect observed.

AGE

12 yr

The ileocecal junction was visualized and exhibited normal intact wall layering and is subjectively of normal thickness. Sections of colon are visualized with formed fecal material and gas shadowing distally. There is no observed focal or generalized colon wall thickening or loss of layering.

WEIGHT

9.5kg

Pancreas

The pancreas is normal and isoechoic to surrounding mesentery. There is no evidence of nodules or cystic lesions. There is no evidence of regional mesenteric inflammation or fluid.

INTERPRETED BY

Kathleen Sennello DVM,
MS, Diplomate ACVIM
(Small Animal Internal
Medicine)

Free Abdomen

Evaluation of the peritoneal cavity did not reveal any evidence of effusion. No lymphadenopathy was noted. The Medial iliac nodes appear normal and there was no evidence of a caudal aortic thrombus at the bifurcation. The omentum is hyperechoic in the caudal abdomen.

IMAGING

PERFORMED BY

Dr. Kuzimski

Other

Both testicles are visualized and appear within normal limits.

PRIMARY FINDINGS

- Large hyperechoic heterogeneous irregular prostate with intraparenchymal and periprostatic cysts. Findings are most consistent with BPH, +/- prostatitis, and prostatic cysts/abscesses (underlying prostatic neoplasia cannot be definitively ruled out).
- Thickened urinary bladder wall. The bladder mucosal changes could be consistent with cystitis or artifactual due to lack of adequate luminal distension. Bladder neoplasia cannot be ruled out but is considered unlikely in this patient.

HOSPITAL NAME

Animal Emergency
Hospital Deland

REFERRING VET

Dr. Kuzimski

INVOICE

10191

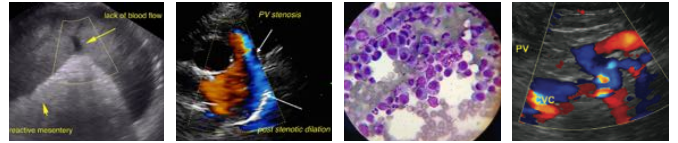
INTERPRETATION OF THE FINDINGS & FURTHER RECOMMENDATIONS

DATE

4/25/23

This patient's inability to urinate is due to the enlargement of the prostate and the periprostatic cyst structures. Recommend a urinalysis and culture as well as percutaneous drainage of the cysts for fluid analysis, cytology, and cultures.

Additionally, consider a fine needle aspirate of the prostatic tissue itself to rule out the possibility of underlying neoplastic disease. If the fluid appears infectious in nature, consider infusion of Baytril to help resolve the lesions. This process will not resolve without discontinuing the presence of testosterone by ideally neutering or less ideally administering a testosterone blocker. Continued



PATIENT

Oscar Collins

monitoring of these lesions is recommended if there is recurrence or lack of resolution. Surgery may be necessary with omentalization of the cystic structures.

SPECIES

Canine

BREED

Dachshund

SEX

Male

AGE

12 yr

WEIGHT

9.5kg

INTERPRETED BY

Kathleen Sennello DVM,
MS, Diplomate ACVIM
(Small Animal Internal
Medicine)

IMAGING PERFORMED BY

Dr. Kuzimski

HOSPITAL NAME

Animal Emergency
Hospital Deland

REFERRING VET

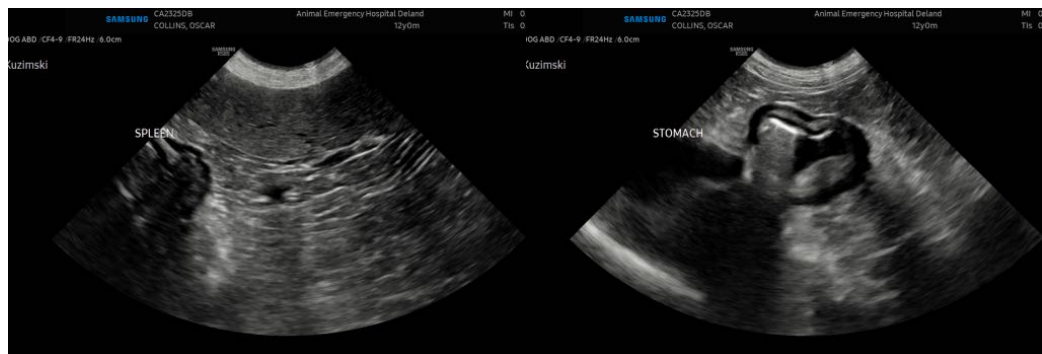
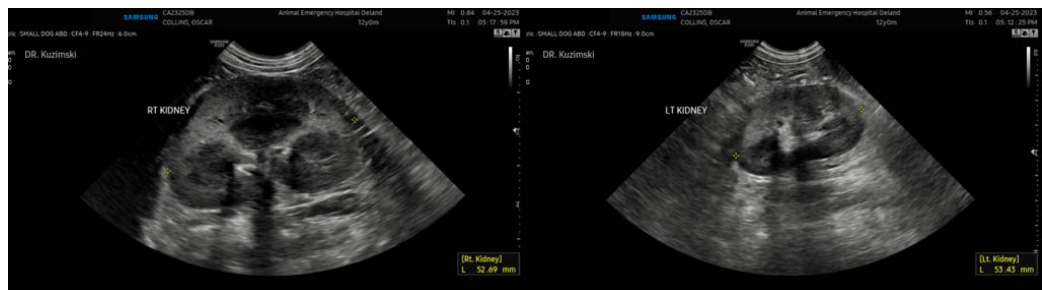
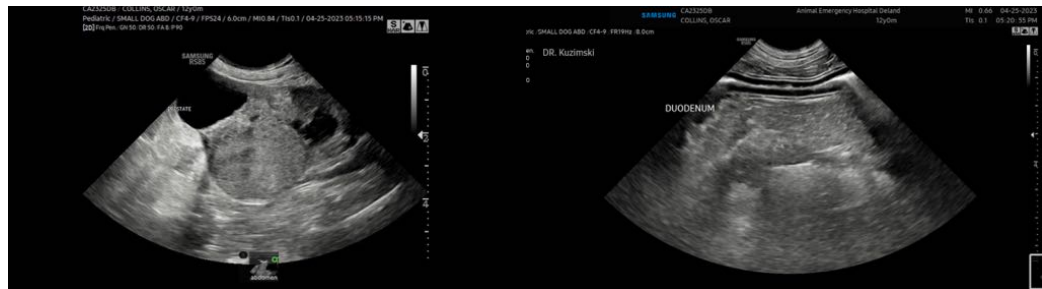
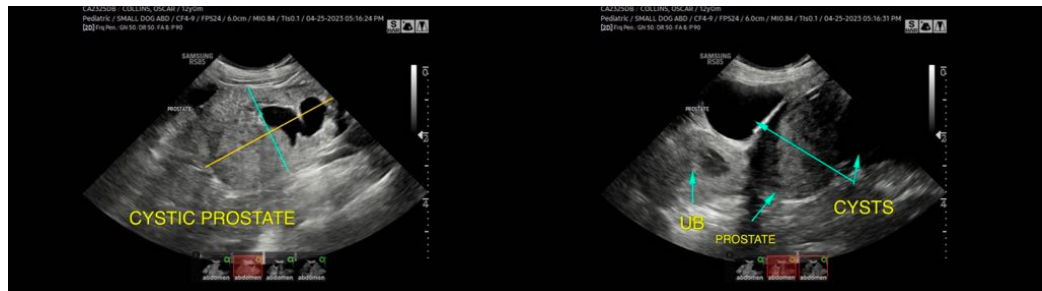
Dr. Kuzimski

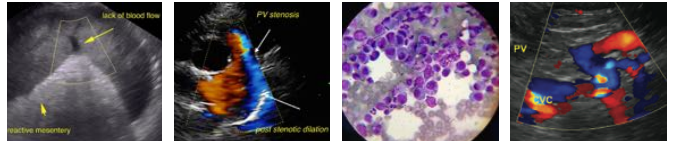
INVOICE

10191

DATE

4/25/23





PATIENT

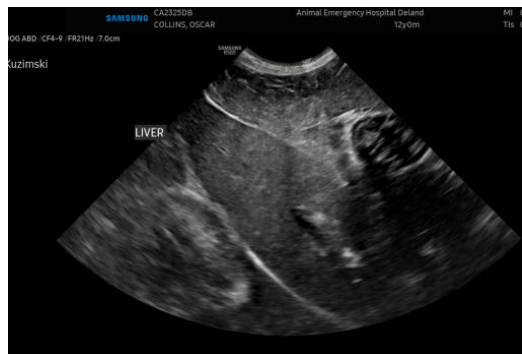Oscar Collins

SPECIES

Canine

BREED

Dachshund



SEX

Male

AGE

12 yr

WEIGHT

9.5kg

The information and recommendations provided are based on the images presented by the referring veterinarian/sonographer. No evaluation can be communicated regarding pathology that was not visible in the image/video clips provided.

Thank you for this referral. If the clinical or image interpretation does not parallel your findings or if I can be of any further assistance, please contact me.

Kathleen Sennello DVM, MS, Diplomate ACVIM (Small animal Internal Medicine)

kathleen.sennello@sonopath.com

INTERPRETED BY

Kathleen Sennello DVM,
MS, Diplomate ACVIM
(Small Animal Internal
Medicine)

**IMAGING
PERFORMED BY**

Dr. Kuzimski

HOSPITAL NAME

Animal Emergency
Hospital Deland

REFERRING VET

Dr. Kuzimski

INVOICE

10191

DATE

4/25/23