

DATE PRESENTING CLINICAL SIGNS

4/25/22 Decreased appetite, lethargy, drinking more water, pale gum color (normal day of scan). Hunched back when going to food bowl, seems interested but walks away.

PATIENT

Teddy Langhans-Lindstadt
Current Medications: Rimadyl 75mg BID, Gabapentin 300mg BID.
Date of Previous IntraPet Ultrasound: No previous.
Sedation: Not required to complete full diagnostic ultrasound.
Stat Report: Not requested.

SPECIES

Canine

BREED

Labradore Retriever

SEX

Neutered Male

AGE

5/15/09

WEIGHT

98 Pounds

INTERPRETED BY

Kathleen Sennello DVM,
MS, Diplomate ACVIM
(Small Animal Internal
Medicine)

IMAGING PERFORMED BY

Andi Parkinson RDMS

HOSPITAL NAME

Nexus Vet Specialists

REFERRING VET

Dr. Dycus

INVOICE

37147

ULTRASONOGRAPHIC EXAMINATION OF THE ABDOMEN

Urinary System

The urinary bladder is moderately distended with anechoic urine. The Bladder wall, trigone, ureteral papillae and visible urethra (to a depth of 2cm) appear normal with no evidence of wall thickening, mucosal irregularities, masses or cystic calculi.

The visualized areas of prostate and surrounding tissue appear normal. Unfortunately, the prostate is not fully visualized likely due to its intrapelvic location. Correlate with rectal exam findings.

The left kidney has a normal shape and size (7.48 cm). Overall echogenicity is normal with adequate corticomedullary distinction and a typical 1:3 cortex:medulla ratio. There is no evidence of perinephric inflammation or effusion. There is no evidence of pyelectasia, nephroliths, infarcts or hydroureter. Renal vasculature is normal.

The right kidney is normal in size (7.83 cm), but mildly irregular in shape, likely due to a previous infarct. Overall echogenicity is normal with adequate corticomedullary distinction and a typical 1:3 cortex:medulla ratio. There is no evidence of perinephric inflammation or effusion. There is no evidence of pyelectasia, nephroliths or hydroureter. Renal vasculature is normal.

Adrenal Glands

The left adrenal gland is normal in size measuring 0.84 cm at the caudal pole. It is observed in its normal position cranial to the left renal artery. It is normal in appearance (uniformly hypoechoic) and shape with no evidence of a mass effect.

The right adrenal gland is normal in size measuring 0.98 cm at the caudal pole. It is observed in its normal position between the cranial aspect of the right kidney and the caudal vena cava. It is normal in appearance (uniformly hypoechoic) and shape with no evidence of a mass effect.

Spleen

The spleen is subjectively normal in size. The spleen echotexture is heterogenous and mottled, the splenic capsule is smooth with no irregularities. The blood flow through the hilus and splenic parenchyma appears normal. The head of the spleen is particularly mottled with ill-defined, coalescing, hypoechoic nodules. Additionally, there is a more focal hypoechoic nodule with a more hyperechoic structure measuring at 0.98 cm. The ill-defined mottling/hypoechoic nodules vary in size from approximately 0.5-1.5 cm.

Liver

The liver is subjectively normal in size and mildly hyperechoic. The parenchyma is heterogenous in echotexture with subtle, indistinct focal mottling. The visible portions of the vasculature and biliary tract appear normal. No focal nodules or cystic lesions are observed.

The gallbladder lumen is moderately distended. The wall of the gall bladder is not thickened and has a smooth mucosal surface. Luminal contents are primarily anechoic. The cystic and common bile ducts are normal/not visible.

Gastrointestinal

The stomach contains mild to moderate fluid. It measures at a normal thickness of <0.7cm with some variability due to the presence of rugal folds. The distinction of the gastric wall layers is adequate and there is no impression of reduced peristaltic activity. No masses or focal lesions were observed.

The visualized areas of duodenum, jejunum and ileum have a relatively uniform diameter with minimal fluid distension. Wall thickness is normal. Bowel loops follow a curvilinear path with distinct wall layering maintaining the typical 1:3 muscularis:mucosa layer ratio. The duodenum measured as normal (between 0.3-0.5cm in wall thickness) and the jejunum measured as normal (between 0.2-0.47cm.) Visualized peristalsis appears appropriate. There were no focal lesions consistent with obstruction or a mass effect observed.

The ileocecal junction was visualized and exhibited normal intact wall layering and is subjectively of normal thickness. Sections of colon are visualized with formed fecal material and gas shadowing distally. There is no observed focal or generalized colon wall thickening or loss of layering.

Pancreas

The pancreas is prominent and mottled compared to the surrounding isoechoic mesentery. There is no evidence of nodules or cystic lesions. There is no evidence of regional mesenteric inflammation or fluid.

Free Abdomen

Evaluation of the peritoneal cavity did not reveal any evidence of effusion, or subjective lymphadenomegaly. The Medial iliac nodes appear normal and there was no evidence of a caudal aortic thrombus at the bifurcation. The omentum is of normal uniform echogenicity.

Other

A brief view of the heart was submitted. No significant pericardial effusion was seen.

PRIMARY FINDINGS

- Focal mottling of the spleen with a hypoechoic nodule with a hyperechoic center – The diffuse splenic changes are non-specific and could be consistent with lymphoid hyperplasia, extramedullary hematopoiesis, infiltrative neoplasia, inflammation, other. Cytology or histopathology would be necessary to get a definitive diagnosis.
- Prominent, mottled pancreas – The pancreatic changes are most consistent with age-related parenchymal remodeling, potentially secondary to a prior inflammatory episode, early fibrosis or chronic pancreatitis.
- Hyperechoic, heterogeneous liver – The diffuse hepatic changes are non-specific and could be consistent with vacuolar hepatopathy, nodular hyperplasia, inflammatory/immune-mediated disease, fibrosis, extramedullary hematopoiesis, toxic hepatopathy (e.g., copper), infiltrative neoplasia (less likely) or other hepatopathy.

SECONDARY FINDINGS

- Mild fluid distention of the gastric lumen – correlate with feeding/drinking history and abdominal radiographs. If adequately fasted, differentials could include delayed gastric emptying, gastritis, or partial outflow tract obstruction (none observed).

- Mildly irregular right kidney - most consistent with previous chronic infarct.

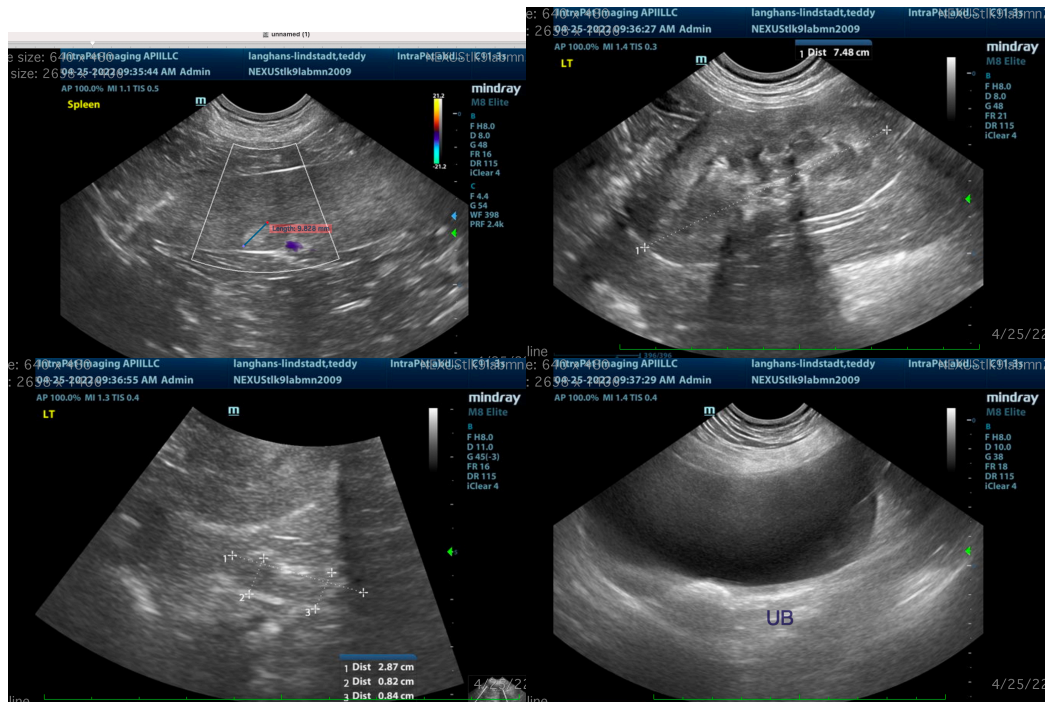
INTERPRETATION OF THE FINDINGS & FURTHER RECOMMENDATIONS

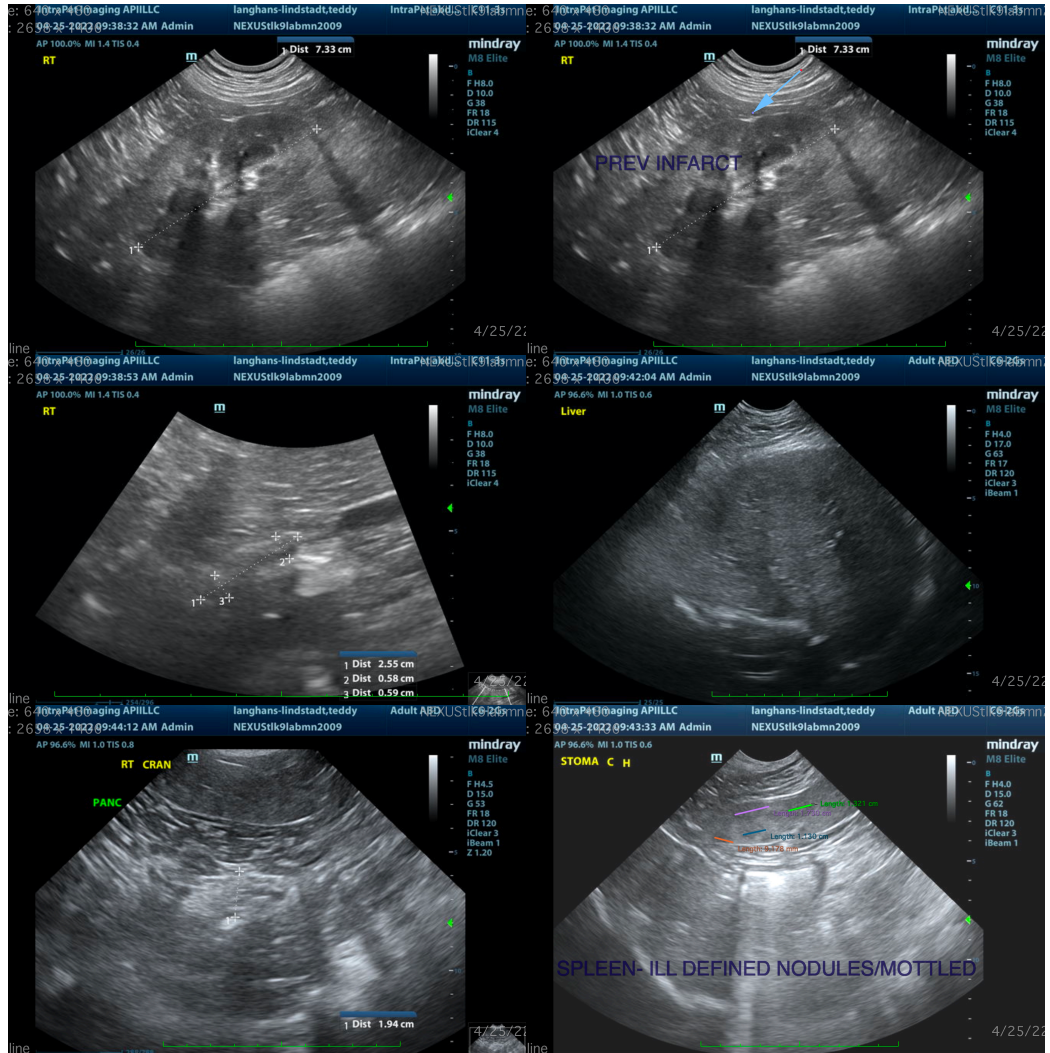
No large, focal masses/lesions are observed to explain the symptoms described. The spleen does appear mottled, particularly in the cranial portion/head of the spleen, where there are coalescing, very ill-defined, hypoechoic nodules. Additionally, there is a more defined hypoechoic nodule with a hyperechoic center. Consider a fine needle aspirate of the head of the spleen in these areas to rule out an atypical mass effect.

The changes in the liver could be consistent with a primary hepatopathy, but if there is a lack of liver enzyme elevation, this could represent age related remodeling. Correlate with bloodwork findings. If liver values are elevated, consider such diagnostics as liver function testing, fine needle aspiration, or adrenal function testing if appropriate.

The pancreas is mildly prominent and there is some visualized within the gastric lumen. If primary GI disease is suspected, you could consider a quantitative PLI level to further evaluate the pancreas, as ultrasonographic changes do not always correlate with clinical symptoms. Additionally, ingested foreign material/dietary indiscretion could be considered.

Consider three view thoracic radiographs to rule out concurrent thoracic disease/involvement.





The information and recommendations provided are based on the images presented by the referring veterinarian/sonographer. No evaluation can be communicated regarding pathology that was not visible in the image/video clips provided.

Thank you for this referral. If the clinical or image interpretation does not parallel your findings or if I can be of any further assistance please contact me.

Kathleen Sennello DVM,MS, Diplomate ACVIM (Small animal Internal Medicine)
 kathleen.sennello@sonopath.com