



PATIENT

Bailey Simon

SPECIES

Canine

BREED

Chihuahua x

SEX

Neutered Male

AGE

13 Years

WEIGHT

11.7 lbs

INTERPRETED BY

Kathleen Sennello DVM,
MS, Diplomate ACVIM
(Small Animal Internal
Medicine)

IMAGING PERFORMED BY

Jessica Milligan, DVM

HOSPITAL NAME

Dockside Veterinary
Imaging

REFERRING VET

Claire Hefner, DVM

INVOICE

74655

DATE

4/21/26

PRESENTING CLINICAL SIGNS

In-house bloodwork revealed azotemia (elevated BUN and Cr).
Abnormal PE/Chem/CBC/UA Results: See attached records.

ULTRASONOGRAPHIC EXAMINATION OF THE ABDOMEN

Urinary System

The urinary bladder is moderately distended with anechoic urine. The Bladder wall, trigone, ureteral papillae and visible urethra (to a depth of 2cm) appear normal with no evidence of wall thickening, mucosal irregularities, masses or cystic calculi.

Prostate is normal in size (0.65 cm), echotexture and echogenicity for a neutered male.

The left kidney has a normal shape and size (3.47 cm) with mild pyelectasia at 0.20 cm. Overall echogenicity is slightly hyperechoic with poor corticomedullary distinction and a typical 1:3 cortex:medulla ratio. There is no evidence of focal perinephric inflammation or effusion. There is no evidence of nephroliths, infarcts or hydroureter. Renal vasculature is normal.

The right kidney has a normal shape and size (3.2 cm) with mild pyelectasia at 0.25 cm. Overall echogenicity is slightly hyperechoic with poor corticomedullary distinction and a typical 1:3 cortex:medulla ratio. There is no evidence of focal perinephric inflammation or effusion. There is no evidence of nephroliths, infarcts or hydroureter. Renal vasculature is normal.

Adrenal Glands

The left adrenal gland is normal in size measuring 0.39 cm at the cranial pole and 0.44 cm at the caudal pole. It is observed in its normal position cranial to the left renal artery. It is normal in appearance (uniformly hypoechoic) and shape with no evidence of a mass effect.

The right adrenal gland is normal in size measuring 0.44 cm at the cranial pole and 0.49 cm at the caudal pole. It is observed in its normal position between the cranial aspect of the right kidney and the caudal vena cava. It is normal in appearance (uniformly hypoechoic) and shape with no evidence of a mass effect.

Spleen

The spleen is subjectively normal in size (0.68 cm), echotexture is homogenous, and the splenic capsule is smooth with no irregularities. The blood flow through the hilus and splenic parenchyma appears normal. No focal parenchymal abnormalities are visualized.

Liver

The liver is subjectively normal in size with smooth peripheral margins. The parenchyma is subjectively hyperechoic and homogenous in echotexture. The visible portions of the vasculature and biliary tract appear normal. No focal nodules or cystic lesions are observed.

The gall bladder lumen is significantly distended. Some areas of the wall appear mildly thickened with adherent debris. There is a large amount of primarily non-organized echogenic debris. There is no evidence of bile duct dilation.



PATIENT

Bailey Simon

SPECIES

Canine

BREED

Chihuahua x

SEX

Neutered Male

AGE

13 Years

WEIGHT

11.7 lbs

INTERPRETED BY

Kathleen Sennello DVM,
MS, Diplomate ACVIM
(Small Animal Internal
Medicine)

IMAGING PERFORMED BY

Jessica Milligan, DVM

HOSPITAL NAME

Dockside Veterinary
Imaging

REFERRING VET

Claire Hefner, DVM

INVOICE

74655

DATE

4/21/26

Gastrointestinal

The stomach contains minimal luminal contents. It measures at a normal thickness of <0.7cm with some variability due to the presence of rugal folds. The distinction of the gastric wall layers is adequate and there is no impression of reduced peristaltic activity. No masses or focal lesions were observed.

The visualized areas of duodenum, jejunum and ileum have a relatively uniform diameter with minimal fluid distension. Wall thickness is normal. Bowel loops follow a curvilinear path with distinct wall layering maintaining the typical 1:3 muscularis:mucosa layer ratio. Duodenum wall measures 0.40 cm. Jejunum wall measures 0.27 cm. Visualized peristalsis appears appropriate. There were no focal lesions consistent with obstruction or a mass effect observed.

Sections of colon are visualized with formed fecal material and gas shadowing distally. There is no observed focal or generalized colon wall thickening or loss of layering.

Pancreas

The pancreas is visible/mildly mottled in the right limb. There is no evidence of nodules or cystic lesions. There is no evidence of regional mesenteric inflammation or fluid.

Free Abdomen

Evaluation of the peritoneal cavity did not reveal any evidence of effusion, or subjective lymphadenomegaly. The Medial iliac nodes appear normal and there was no evidence of a caudal aortic thrombus at the bifurcation. The omentum is of normal uniform echogenicity.

ULTRASONOGRAPHIC FINDINGS

- Mildly/moderately decreased corticomedullary distinction in both kidneys with mild bilateral pyelectasia – Mild loss of corticomedullary distinction in both kidneys could be consistent with chronic degenerative disease or interstitial nephrosis. Pyelectasia of the kidneys could be consistent with pyelonephritis, chronic renal disease, secondary to PU/PD or fluid therapy (if applicable), other.
- Pancreatic changes most consistent with chronic pancreatic remodeling.
- Mildly hyperechoic liver – The diffuse hepatic changes are non-specific and can be seen with vacuolar hepatopathy, reactive change, nodular hyperplasia or, less likely, inflammatory/immune-mediated disease, infiltrative neoplasia, or other hepatopathy. The significance of this in the absence of liver enzyme elevations is uncertain.
- Large gallbladder debris – A large amount of debris is evident in the gall bladder with no evidence of a mucocele or associated inflammation at this time. This could represent an early mucocele or cholestasis, with minimal evidence of associated inflammation at this time. Continued monitoring of labwork and ultrasound are warranted for progression of this lesion. Ursodiol therapy could be considered.

INTERPRETATION OF THE FINDINGS & FURTHER RECOMMENDATIONS

There are mild changes visualized associated with both kidneys, consistent with age related renal changes. Unfortunately, the appearance of the kidneys does not always correlate with renal function. Recommend a blood pressure, urinalysis, culture, and a urine protein to creatinine ratio as well as either



PATIENT

Bailey Simon

diuresis or subcutaneous fluid therapy to try to correct any dehydration that may be present, contributing to the azotemia reported. Empirical treatment for uremia (nausea medications +/- anti-ulcer therapy, etc.) should be considered if patient is clinical.

SPECIES

Canine

There is a large amount of debris visualized in the gallbladder with no evidence of surrounding inflammation. Once the patient is eating better and feeling better, you could consider chronic Ursodiol therapy and continued monitoring.

BREED

Chihuahua x

SEX

Neutered Male

AGE

13 Years

WEIGHT

11.7 lbs

INTERPRETED BY

Kathleen Sennello DVM, MS, Diplomate ACVIM (Small Animal Internal Medicine)

IMAGING PERFORMED BY

Jessica Milligan, DVM

HOSPITAL NAME

Dockside Veterinary Imaging

REFERRING VET

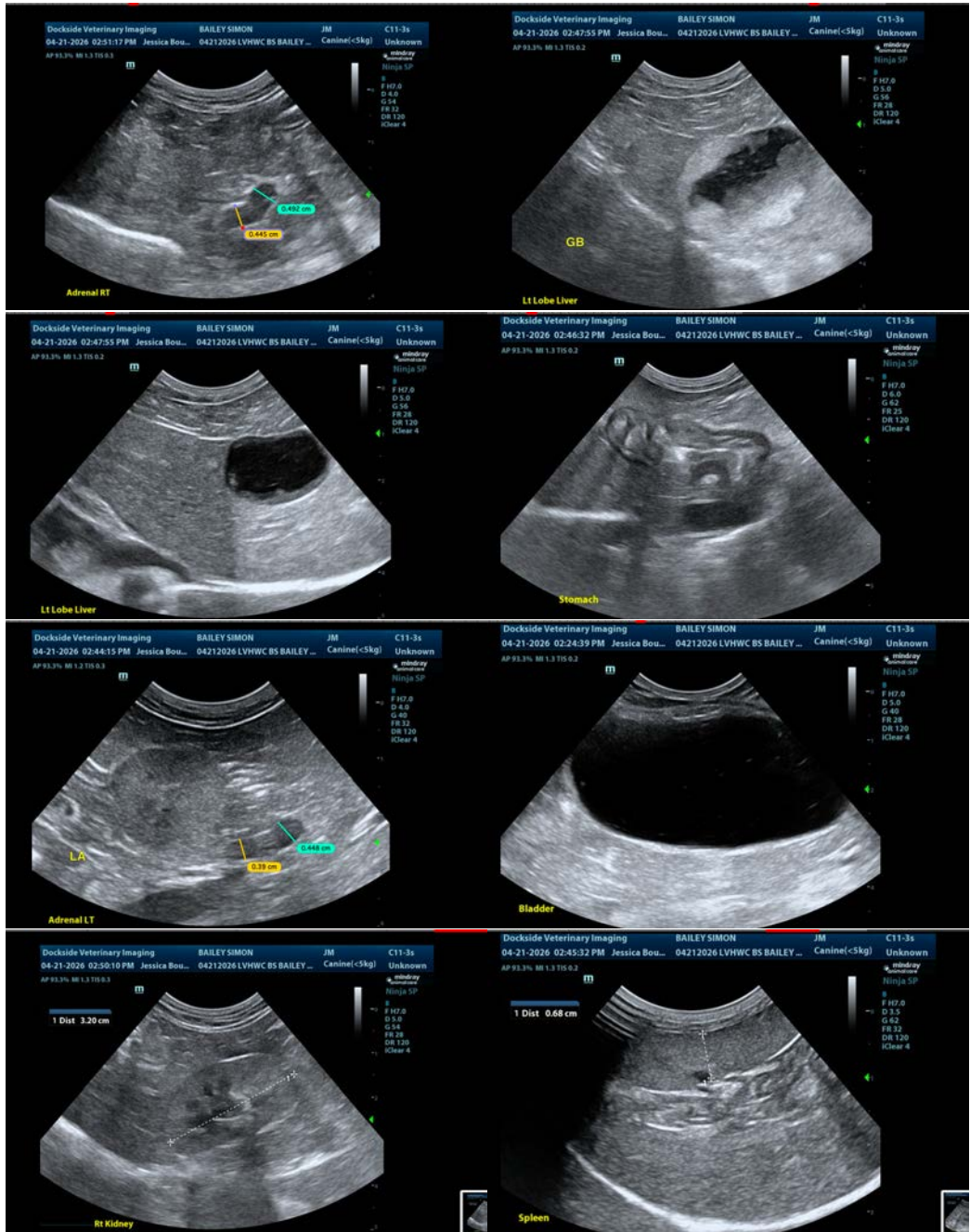
Claire Hefner, DVM

INVOICE

74655

DATE

4/21/26





PATIENT

Bailey Simon

SPECIES

Canine

BREED

Chihuahua x

SEX

Neutered Male

AGE

13 Years

WEIGHT

11.7 lbs

INTERPRETED BY

Kathleen Sennello DVM,
MS, Diplomate ACVIM
(Small Animal Internal
Medicine)

IMAGING PERFORMED BY

Jessica Milligan, DVM

HOSPITAL NAME

Dockside Veterinary
Imaging

REFERRING VET

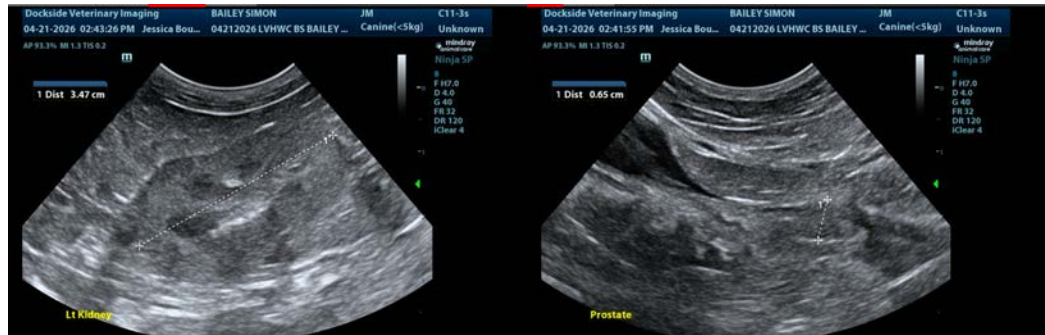
Claire Hefner, DVM

INVOICE

74655

DATE

4/21/26



The information and recommendations provided are based on the images presented by the referring veterinarian/sonographer. No evaluation can be communicated regarding pathology that was not visible in the image/video clips provided.

Thank you for this referral. If the clinical or image interpretation does not parallel your findings or if I can be of any further assistance please contact me.

Kathleen Sennello DVM,MS, Diplomate ACVIM (Small animal Internal Medicine)

info@sonopath.com