

IMAGING PERFORMED BY

IntraPet.com



**SonoPath**

Clinical Sonography & Telecytology

EDUCATIONAL TELECONSULTATION SERVICES™

1-800-838-4268 info@sonopath.com SonoPath.com

**DATE PRESENTING CLINICAL SIGNS**

4/21/22 Hx of progressive hyporexia, weight loss, muscle wasting. Hx of intermittent VPCs with unknown etiology.

**PATIENT** Current Medications: Sotalol 40mg SID.

Shamus Dipasquali

Lab Results: Pre renal azotemia with hypersthenuria.

Radiographs: TXR 3 view WNL.

Date of Previous IntraPet Ultrasound: No previous.

Sedation: Not required to complete full diagnostic ultrasound.

Stat Report: Not requested.

**SPECIES**

Canine

**ULTRASONOGRAPHIC EXAMINATION OF THE ABDOMEN**

**BREED**

Labradoodle

**Urinary System**

The urinary bladder is moderately distended with anechoic urine. The Bladder wall, trigone, ureteral papillae and visible urethra (to a depth of 2cm) appear normal with no evidence of wall thickening, mucosal irregularities, masses or cystic calculi.

**SEX**

Neutered Male

The visualized areas of prostate and surrounding tissue appear normal. Unfortunately, the prostate is not fully visualized likely due to its intrapelvic location. Correlate with rectal exam findings.

**AGE**

11/12/11

The left kidney has a normal shape and size (7.3 cm) Overall echogenicity is normal with adequate corticomedullary distinction and a typical 1:3 cortex:medulla ratio. There is no evidence of perinephric inflammation or effusion. There is no evidence of pyelectasia, nephroliths, infarcts or hydroureter. Renal vasculature is normal.

**WEIGHT**

74 Pounds

The right kidney has a normal shape and size (7.56 cm). Overall echogenicity is normal with adequate corticomedullary distinction and a typical 1:3 cortex:medulla ratio. There is no evidence of perinephric inflammation or effusion. There is no evidence of pyelectasia, nephroliths, infarcts or hydroureter. Renal vasculature is normal.

**INTERPRETED BY**

Kathleen Sennello DVM,  
MS, Diplomate ACVIM  
(Small Animal Internal  
Medicine)

**Adrenal Glands**

The left adrenal gland is normal/borderline large in size measuring 0.93 cm at the caudal pole. It is observed in its normal position cranial to the left renal artery. It is normal in appearance (uniformly hypoechoic) and shape with no evidence of a mass effect.

**IMAGING PERFORMED BY**

Andi Parkinson RDMS

The right adrenal gland is normal/borderline large in size measuring 0.87 cm at the caudal pole. It is observed in its normal position between the cranial aspect of the right kidney and the caudal vena cava. It is normal in appearance (uniformly hypoechoic) and shape with no evidence of a mass effect.

**HOSPITAL NAME**

Timonium AH

**Spleen**

The spleen is subjectively normal in size. The spleen echotexture is heterogenous and mottled, the splenic capsule is smooth with no irregularities. The blood flow through the hilus and splenic parenchyma appears normal. No focal parenchymal abnormalities are visualized.

**REFERRING VET**

Dr. McIntyre

**Liver**

The liver is large in size, and normal in echogenicity with smooth peripheral margins. The parenchyma is mildly heterogenous in echotexture with subtle, indistinct focal mottling. The visible portions of the vasculature and biliary tract appear normal. No focal nodules or cystic lesions are observed.

**INVOICE**

37059

The gallbladder lumen is moderately distended. The wall of the gall bladder is not thickened and has a smooth mucosal surface. Luminal contents are primarily anechoic. The cystic and common bile ducts are normal/not visible.

### ***Gastrointestinal***

The stomach contains minimal luminal contents. It measures at a normal thickness of <0.7cm with some variability due to the presence of rugal folds. The distinction of the gastric wall layers is adequate and there is no impression of reduced peristaltic activity. No masses or focal lesions were observed.

The visualized areas of duodenum, jejunum and ileum have a relatively uniform diameter with minimal fluid distension. Wall thickness is normal. Bowel loops follow a curvilinear path with distinct wall layering maintaining the typical 1:3 muscularis:mucosa layer ratio. Jejunum wall measured 0.25 cm. Visualized peristalsis appears appropriate. There were no focal lesions consistent with obstruction or a mass effect observed.

The ileocecal junction was visualized and exhibited normal intact wall layering and is subjectively of normal thickness. Sections of colon are visualized with formed fecal material and gas shadowing distally. There is no observed focal or generalized colon wall thickening or loss of layering.

### ***Pancreas***

The pancreas is normal and isoechoic to surrounding mesentery. There is no evidence of nodules or cystic lesions. There is no evidence of regional mesenteric inflammation or fluid.

### ***Free Abdomen***

Evaluation of the peritoneal cavity did not reveal any evidence of effusion, or subjective lymphadenomegaly. The Medial iliac nodes appear normal and there was no evidence of a caudal aortic thrombus at the bifurcation. The omentum is of normal uniform echogenicity.

### ***Other***

A brief view of the heart was submitted. No significant pericardial effusion was seen.

Ringdowns are visualized at the level of the diaphragm, indicating possible pulmonary parenchymal disease. Recommend 3-view thoracic radiographs (already done).

## **ULTRASONOGRAPHIC FINDINGS**

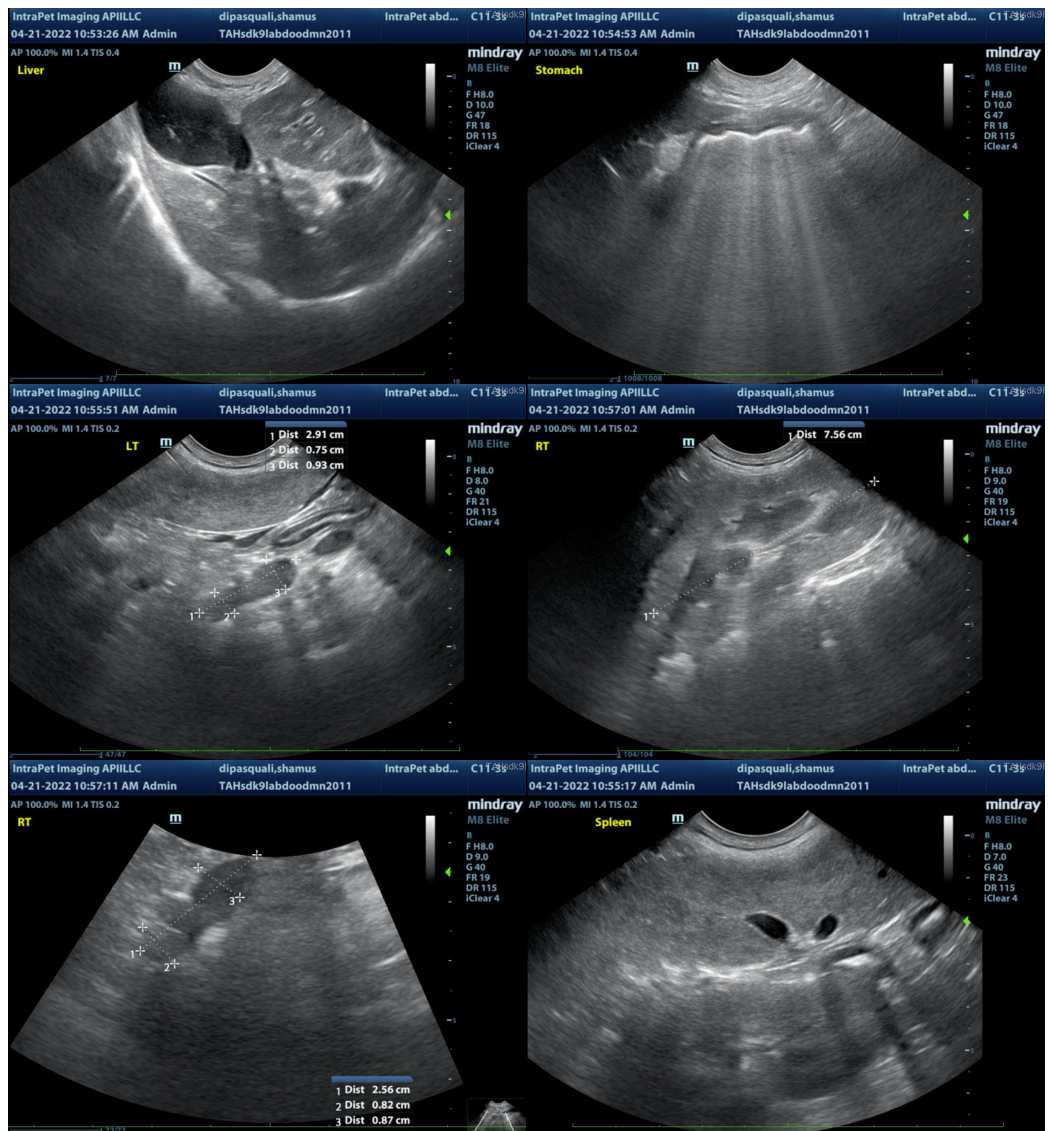
- Mildly mottled spleen – The diffuse splenic changes are non-specific and could be consistent with lymphoid hyperplasia, extramedullary hematopoiesis, infiltrative neoplasia, inflammation, other. Cytology or histopathology would be necessary to get a definitive diagnosis.
- Large, mildly heterogeneous liver – The diffuse hepatic changes are non-specific and could be consistent with vacuolar hepatopathy, nodular hyperplasia, inflammatory/immune-mediated disease, fibrosis, extramedullary hematopoiesis, toxic hepatopathy (e.g., copper), infiltrative neoplasia (less likely) or other hepatopathy.
- Borderline bilateral adrenomegaly – The bilateral adrenomegaly could be consistent with bilateral hyperplasia (e.g., secondary to pituitary-dependent hyperadrenocorticism), bilateral infiltrative neoplasia, inflammatory adrenal disease, other. Correlation with clinical findings is recommended.

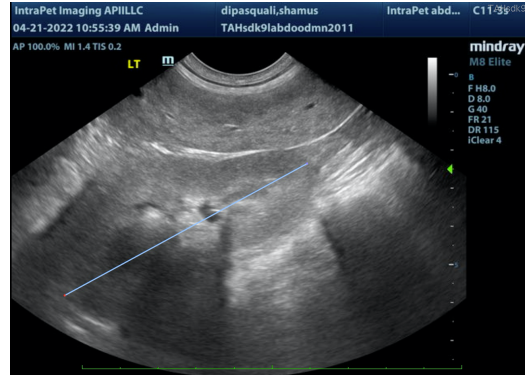
## **INTERPRETATION OF THE FINDINGS & FURTHER RECOMMENDATIONS**

Today's scan is relatively normal. There is mild mottling of the spleen, and the liver appears somewhat prominent in size and slightly heterogeneous. Some of this could be age related remodeling. Recommend a fine needle aspirate of the spleen, and if there are liver enzyme elevations present or indications of liver dysfunction, you could consider a fine needle aspirate.

Both adrenal glands appear somewhat “plump”, but are not overtly enlarged and are normal in shape and size. Seeing as the symptoms reported are not consistent with a cortisol excess, I would recommend continued monitoring.

If cytology of the spleen is uneventful, and other potential causes are not identified, consider the possibility of underlying gastrointestinal disease, which can often be present without significant ultrasonographic lesions.





**The information and recommendations provided are based on the images presented by the referring veterinarian/sonographer. No evaluation can be communicated regarding pathology that was not visible in the image/video clips provided.**

Thank you for this referral. If the clinical or image interpretation does not parallel your findings or if I can be of any further assistance please contact me.

Kathleen Sennello DVM,MS, Diplomate ACVIM (Small animal Internal Medicine)  
kathleen.sennello@sonopath.com