



PATIENT PRESENTING CLINICAL SIGNS

Marley Sharpe
Enlarged liver on rads, increased ALP, no polyuria.

SPECIES ULTRASONOGRAPHIC EXAMINATION OF THE ABDOMEN

Canine

Urinary System

BREED

Poodle X

The urinary bladder is moderately distended with anechoic urine. The Bladder wall, trigone, ureteral papillae and visible urethra (to a depth of 2cm) appear normal with no evidence of wall thickening, mucosal irregularities, masses or cystic calculi.

SEX

Spayed Female

The prostate is normal in size (XXcm) and shape for this neutered male dog. The parenchyma is homogenous and the external margins are smooth. The prostatic urethra appears normal with no evidence of irregularity, invasion, mass effect or calculi.

AGE

9 Years

The left kidney has a normal shape and size (4.64 cm). Overall echogenicity is normal with adequate corticomedullary distinction and a typical 1:3 cortex:medulla ratio. There is no evidence of focal perinephric inflammation or effusion. There is no evidence of pyelectasia, nephroliths, infarcts or hydroureter. Renal vasculature is normal.

WEIGHT

7 kg

The right kidney has a normal shape and size (4.92 cm). Overall echogenicity is normal with adequate corticomedullary distinction and a typical 1:3 cortex:medulla ratio. There is no evidence of focal perinephric inflammation or effusion. There is no evidence of pyelectasia, nephroliths, infarcts or hydroureter. Renal vasculature is normal.

INTERPRETED BY

Kathleen Sennello DVM,
MS, Diplomate ACVIM
(Small Animal Internal
Medicine)

Adrenal Glands

The left adrenal gland is normal in size measuring 0.66 cm at the caudal pole. It is observed in its normal position cranial to the left renal artery. It is normal in appearance (uniformly hypoechoic) and shape with no evidence of a mass effect.

IMAGING PERFORMED BY

Kelly Reschny

The right adrenal gland is normal in size measuring 0.49 cm at the caudal pole. It is observed in its normal position between the cranial aspect of the right kidney and the caudal vena cava. It is normal in appearance (uniformly hypoechoic) and shape with no evidence of a mass effect.

HOSPITAL NAME

Headon Forest AH

Spleen

The spleen is subjectively normal in size, echotexture is homogenous, and the splenic capsule is smooth with no irregularities. The blood flow through the hilus and splenic parenchyma appears normal. No focal parenchymal abnormalities are visualized.

REFERRING VET

Dr. Noonan

INVOICE

46810

Liver

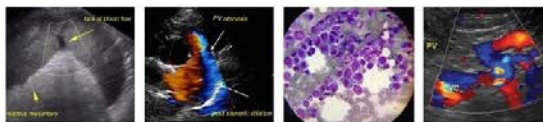
The liver is large in size, and normal in echogenicity with smooth peripheral margins. The parenchyma is heterogenous in echotexture with subtle, indistinct focal mottling. The visible portions of the vasculature and biliary tract appear normal. No focal nodules or cystic lesions are observed.

DATE

4/20/23

The gallbladder lumen is moderately distended. The wall of the gall bladder is not thickened and has a smooth mucosal surface. Luminal contents are mild and primarily anechoic. The cystic and common bile ducts are normal/not visible.

Gastrointestinal



PATIENT

Marley Sharpe

The stomach contains minimal luminal contents. It measures at a normal thickness of <0.7cm with some variability due to the presence of rugal folds. The distinction of the gastric wall layers is adequate and there is no impression of reduced peristaltic activity. No masses or focal lesions were observed.

SPECIES

Canine

The visualized areas of duodenum, jejunum and ileum have a relatively uniform diameter with minimal fluid distension. Wall thickness is normal. Bowel loops follow a curvilinear path with distinct wall layering maintaining the typical 1:3 muscularis:mucosa layer ratio. Duodenum wall measures 0.37 cm. Jejunum wall measures 0.30 cm. Visualized peristalsis appears appropriate. There were no focal lesions consistent with obstruction or a mass effect observed.

BREED

Poodle X

The ileocecal junction was visualized and exhibited normal intact wall layering and is subjectively of normal thickness. Sections of colon are visualized with formed fecal material and gas shadowing distally. There is no observed focal or generalized colon wall thickening or loss of layering.

SEX

Spayed Female

Pancreas

AGE

9 Years

The area of the pancreas is normal and isoechoic to surrounding mesentery. There is no evidence of nodules or cystic lesions. There is no evidence of regional mesenteric inflammation or fluid.

WEIGHT

7 kg

Free Abdomen

Evaluation of the peritoneal cavity did not reveal any evidence of effusion, or subjective lymphadenomegaly. The Medial iliac nodes appear normal and there was no evidence of a caudal aortic thrombus at the bifurcation. The omentum is of normal uniform echogenicity.

INTERPRETED BY

Kathleen Sennello DVM,
MS, Diplomate ACVIM
(Small Animal Internal
Medicine)

ULTRASONOGRAPHIC FINDINGS

- Large, heterogeneous liver – The diffuse hepatic changes are non-specific and could be consistent with vacuolar hepatopathy, nodular hyperplasia, inflammatory/immune-mediated disease, fibrosis, extramedullary hematopoiesis, toxic hepatopathy (e.g., copper), infiltrative neoplasia (less likely) or other hepatopathy.

IMAGING PERFORMED BY

Kelly Reschny

INTERPRETATION OF THE FINDINGS & FURTHER RECOMMENDATIONS

No focal lesions are visualized associated with the liver to explain the large size and the heterogeneous parenchyma. These changes are non-specific. These are my recommendations for further evaluation of a primary ALP elevation.

HOSPITAL NAME

Headon Forest AH

- Induction phenomena are the most common cause for an elevation in ALP. These are systemic illnesses that 'turn on' the liver enzyme. Causes of this include Cushing's disease, dental disease, arthritis, and numerous others. In many cases the exact cause is unclear but as long as ultrasound and bile acids tests are normal most patients do not have progressive changes in their liver. While liver biopsy is not routinely performed, vacuolar hepatopathy, is noted on most biopsies. This is often non-progressive but in rare cases can be more severe and lead to liver failure.

REFERRING VET

Dr. Noonan

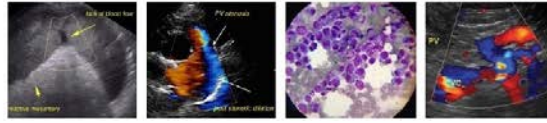
INVOICE

46810

DATE

4/20/23

- If signs of cushings disease are present recommend endocrine function testing to evaluate for cushings disease.
- Consider fine needle aspirate to rule out round cell neoplasia -if this is a concern.
- If a cause for the ALP elevation is not identified: I recommend recheck general blood work every 6 months, ultrasound once per year, and bile acids test every 1-2 years based on other results. If the ALP continues to climb a biopsy could be considered.
- Consider long term use of denamarin, and monitoring for the signs of cushings developing.



PATIENT

Marley Sharpe

- A primary vacuolar hepatopathy can be breed related and is seen in Scottish Terriers, Schnauzers, Cocker spaniels etc..

SPECIES

Canine

BREED

Poodle X

SEX

Spayed Female

AGE

9 Years

WEIGHT

7 kg

INTERPRETED BY

Kathleen Sennello DVM,
MS, Diplomate ACVIM
(Small Animal Internal
Medicine)

**IMAGING
PERFORMED BY**

Kelly Reschny

HOSPITAL NAME

Headon Forest AH

REFERRING VET

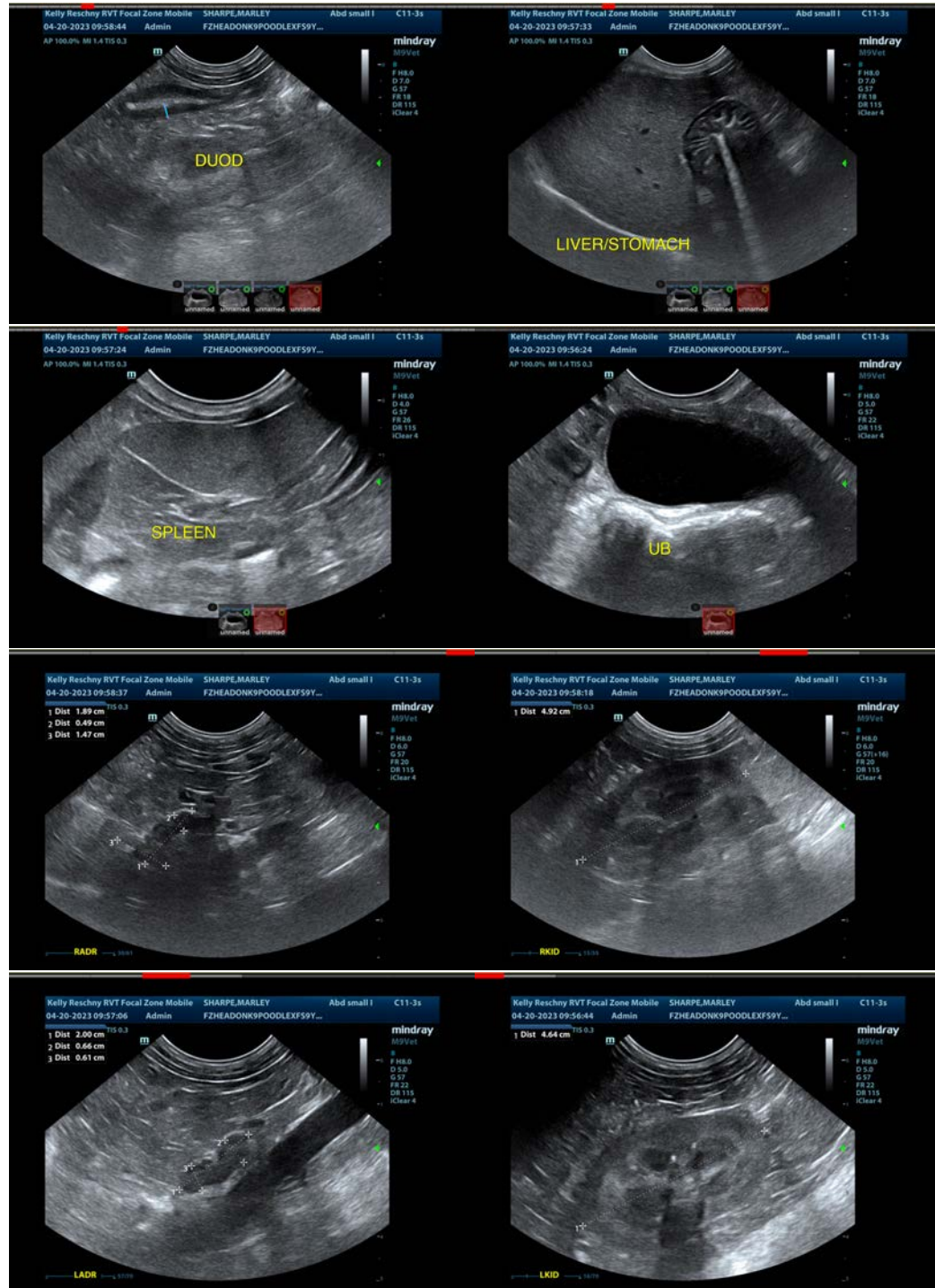
Dr. Noonan

INVOICE

46810

DATE

4/20/23





PATIENT

Marley Sharpe

The information and recommendations provided are based on the images presented by the referring veterinarian/sonographer. No evaluation can be communicated regarding pathology that was not visible in the image/video clips provided.

SPECIES

Canine

Thank you for this referral. If the clinical or image interpretation does not parallel your findings or if I can be of any further assistance please contact me.

BREED

Poodle X

Kathleen Sennello DVM,MS, Diplomate ACVIM (Small animal Internal Medicine)

SEX

Spayed Female

kathleen.sennello@sonopath.com

AGE

9 Years

WEIGHT

7 kg

INTERPRETED BY

Kathleen Sennello DVM,
MS, Diplomate ACVIM
(Small Animal Internal
Medicine)

**IMAGING
PERFORMED BY**

Kelly Reschny

HOSPITAL NAME

Headon Forest AH

REFERRING VET

Dr. Noonan

INVOICE

46810

DATE

4/20/23