



PATIENT

Mike Ramalhoso-Zimmerman

SPECIES

Canine

BREED

Doberman

SEX

Male

AGE

8 Years

WEIGHT

82.6 Pounds

INTERPRETED BY

Kathleen Sennello DVM, MS, Diplomate ACVIM (Small Animal Internal Medicine)

IMAGING PERFORMED BY

Jessica Miller

HOSPITAL NAME

Cresskill AH

REFERRING VET

Dr. Khodari

INVOICE

37034

DATE

4/20/22

PRESENTING CLINICAL SIGNS

Hematuria, intermittent. No LUTS. Intact male. R/o prostatic disease vs trigone disease vs other. No current meds.

Abnormal PE/Chem/CBC/UA Results: WNL UA SG: 1.025

ULTRASONOGRAPHIC EXAMINATION OF THE ABDOMEN

Urinary System

The urinary bladder is moderately distended with anechoic urine. The Bladder wall, trigone, ureteral papillae and visible urethra (to a depth of 2cm) appear normal with no evidence of wall thickening, mucosal irregularities, masses or cystic calculi.

The prostate is large in size (5.39 cm in width) but has a regular shape with smooth external margins. The parenchyma is hyperechoic and heterogenous. There are numerous small, hypoechoic cysts visualized throughout the parenchyma. The prostatic urethra appears normal with no evidence of irregularity, invasion, mass effect or calculi.

The left kidney has a normal shape and size (7.86 cm) with small, non-obstructive nephroliths. Overall echogenicity is normal with adequate corticomedullary distinction and a typical 1:3 cortex:medulla ratio. There is no evidence of perinephric inflammation or effusion. There is no evidence of pyelectasia, infarcts or hydroureter. Renal vasculature is normal.

The right kidney has a normal shape and size (7.61 cm) with small, pinpoint non-obstructive nephroliths. Overall echogenicity is normal with adequate corticomedullary distinction and a typical 1:3 cortex:medulla ratio. There is no evidence of perinephric inflammation or effusion. There is no evidence of pyelectasia, nephroliths, infarcts or hydroureter. Renal vasculature is normal.

Adrenal Glands

The left adrenal gland is normal in size measuring 0.66 cm at the caudal pole. It is observed in its normal position cranial to the left renal artery. It is normal in appearance (uniformly hypoechoic) and shape with no evidence of a mass effect.

The right adrenal gland is normal in size measuring 0.69 cm at the caudal pole. It is observed in its normal position between the cranial aspect of the right kidney and the caudal vena cava. It is normal in appearance (uniformly hypoechoic) and shape with no evidence of a mass effect.

Spleen

The spleen is subjectively normal in size, echotexture is homogenous, and the splenic capsule is smooth with no irregularities. The blood flow through the hilus and splenic parenchyma appears normal. No focal parenchymal abnormalities are visualized.

Liver

The liver is subjectively normal in size, and echogenicity with smooth peripheral margins. The parenchyma is homogenous echotexture. The visible portions of the vasculature and biliary tract appear normal. No focal nodules or cystic lesions are observed.

The gall bladder lumen is moderately distended. The wall of the gall bladder is not thickened and has a smooth mucosal surface. There is a mild to moderate amount of non-organized echogenic debris. The cystic and common bile ducts are normal/not visible.



PATIENT

Mike Ramalhoso-Zimmerman

SPECIES

Canine

BREED

Doberman

SEX

Male

AGE

8 Years

WEIGHT

82.6 Pounds

INTERPRETED BY

Kathleen Sennello DVM,
MS, Diplomate ACVIM
(Small Animal Internal
Medicine)

IMAGING PERFORMED BY

Jessica Miller

HOSPITAL NAME

Cresskill AH

REFERRING VET

Dr. Khodari

INVOICE

37034

DATE

4/20/22

Gastrointestinal

The stomach contains minimal luminal contents. It measures at a normal thickness of <0.7cm with some variability due to the presence of rugal folds. The distinction of the gastric wall layers is adequate and there is no impression of reduced peristaltic activity. No masses or focal lesions were observed.

The visualized areas of duodenum, jejunum and ileum have a relatively uniform diameter with minimal fluid distension. Wall thickness is normal. Bowel loops follow a curvilinear path with distinct wall layering maintaining the typical 1:3 muscularis:mucosa layer ratio. The duodenum measured as normal (between 0.3-0.5cm in wall thickness) and the jejunum measured as normal (between 0.2-0.47cm.) Visualized peristalsis appears appropriate. There were no focal lesions consistent with obstruction or a mass effect observed.

The ileocecal junction was visualized and exhibited normal intact wall layering and is subjectively of normal thickness. Sections of colon are visualized with formed fecal material and gas shadowing distally. There is no observed focal or generalized colon wall thickening or loss of layering.

Pancreas

The pancreas is normal and isoechoic to surrounding mesentery. There is no evidence of nodules or cystic lesions. There is no evidence of regional mesenteric inflammation or fluid.

Free Abdomen

Evaluation of the peritoneal cavity did not reveal any evidence of effusion, or subjective lymphadenomegaly. The Medial iliac nodes appear normal and there was no evidence of a caudal aortic thrombus at the bifurcation. The omentum is of normal uniform echogenicity.

Other

Both testicles are visualized and appear within normal limits.

ULTRASONOGRAPHIC FINDINGS

- Large, heterogeneous prostate with small intraparenchymal cysts – most consistent with benign prostatic hypertrophy +/- prostatitis. Underlying neoplasia cannot be excluded as a possibility (unlikely).
- Rare, non-obstructive nephroliths in both kidneys – The hyperechoic mineralized foci observed at the corticomedullary junction of the left/right kidney are consistent with small, non-obstructive nephroliths.

INTERPRETATION OF THE FINDINGS & FURTHER RECOMMENDATIONS

The prostate is large and heterogeneous with small intraparenchymal cysts. These changes are most consistent with benign prostatic hypertrophy +/- prostatitis and are the likely cause for the hematuria reported. An underlying neoplastic process cannot be excluded as a possibility, but is unlikely. If there are concerns about this, you could consider a fine needle aspirate of the prostate. Recommend urinalysis and culture (if not already done) and neutering.



PATIENT

Mike Ramalhos-Zimmerman

SPECIES

Canine

BREED

Doberman

SEX

Male

AGE

8 Years

WEIGHT

82.6 Pounds

INTERPRETED BY

Kathleen Sennello DVM, MS, Diplomate ACVIM (Small Animal Internal Medicine)

IMAGING PERFORMED BY

Jessica Miller

HOSPITAL NAME

Cresskill AH

REFERRING VET

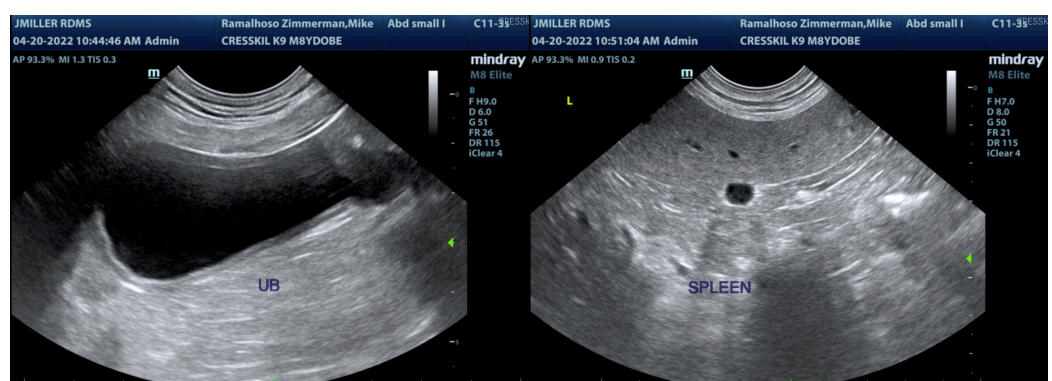
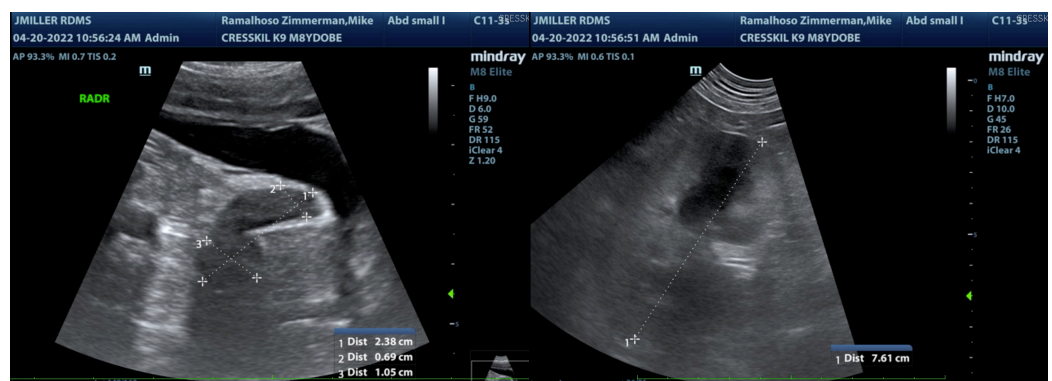
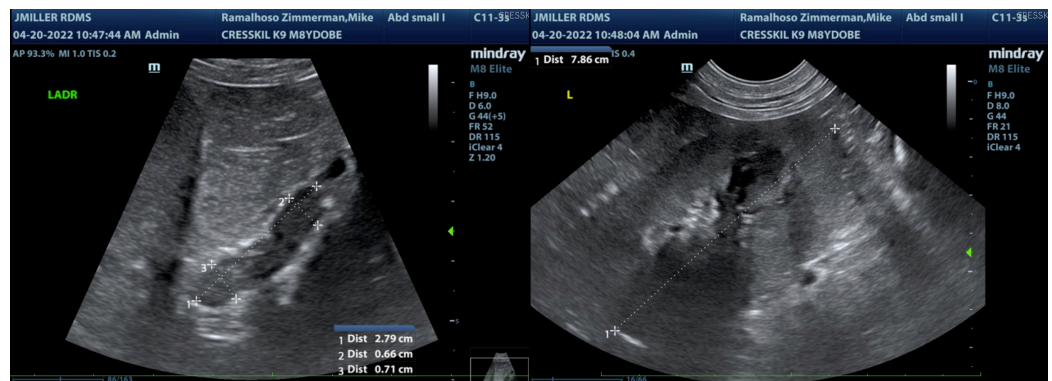
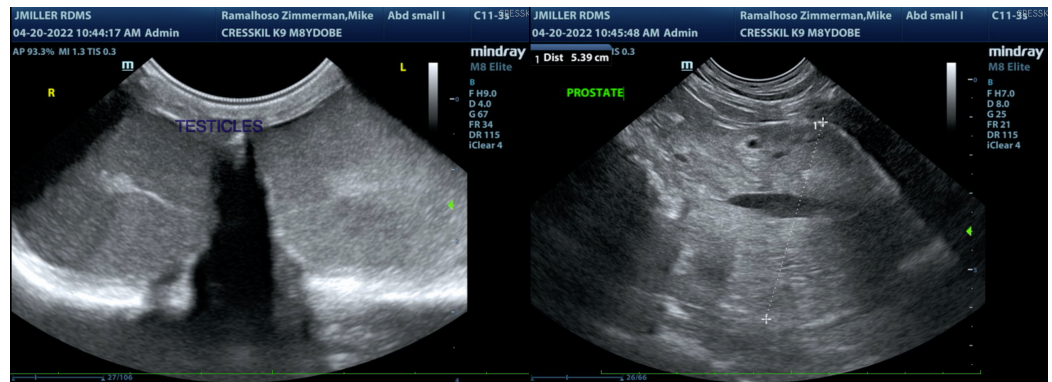
Dr. Khodari

INVOICE

37034

DATE

4/20/22





PATIENT

Mike Ramalhoso-Zimmerman

SPECIES

Canine

BREED

Doberman

SEX

Male

AGE

8 Years

WEIGHT

82.6 Pounds

INTERPRETED BY

Kathleen Sennello DVM,
MS, Diplomate ACVIM
(Small Animal Internal
Medicine)

**IMAGING
PERFORMED BY**

Jessica Miller

HOSPITAL NAME

Cresskill AH

REFERRING VET

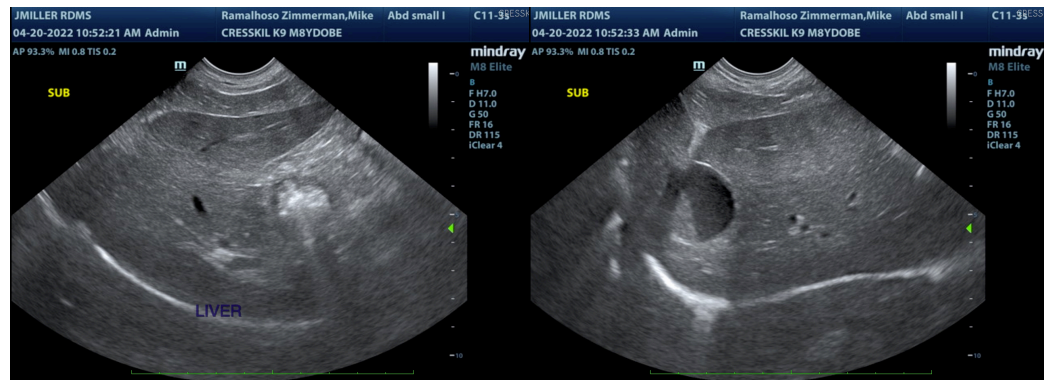
Dr. Khodari

INVOICE

37034

DATE

4/20/22



The information and recommendations provided are based on the images presented by the referring veterinarian/sonographer. No evaluation can be communicated regarding pathology that was not visible in the image/video clips provided.

Thank you for this referral. If the clinical or image interpretation does not parallel your findings or if I can be of any further assistance please contact me.

Kathleen Sennello DVM,MS, Diplomate ACVIM (Small animal Internal Medicine)

kathleen.sennello@sonopath.com