



**PATIENT PRESENTING CLINICAL SIGNS**

Jip Streach  
chronic hematuria meds: meloxyn q 24  
Abnormal PE/Chem/CBC/UA Results: please see attached labs

**SPECIES ULTRASONOGRAPHIC EXAMINATION OF THE ABDOMEN**

Canine

**Urinary System**

**BREED**

The urinary bladder is mildly distended with echogenic urine. The Bladder wall appears subjectively thickened, measuring 0.54 cm near the apex, and slightly irregular along the mucosa. No focal mass effects are visualized, but the urine is very echogenic. The area of the trigone, proximal urethra, and ureteral papillae appear free of any calculi or mass lesions.

Lab X

**SEX**

The prostate is normal in size (1.1 cm) and shape for this neutered male dog. The parenchyma is homogenous and the external margins are smooth. The prostatic urethra appears normal with no evidence of irregularity, invasion, mass effect or calculi.

Neutered Male

**AGE**

The left kidney has a normal shape and size (6.71 cm). Overall echogenicity is slightly hyperechoic with poor corticomedullary distinction and a typical 1:3 cortex:medulla ratio. There is no evidence of perinephric inflammation or effusion. There is no evidence of pyelectasia, nephroliths, infarcts or hydroureter. Renal vasculature is normal.

12 Years

**WEIGHT**

The right kidney has a normal shape and size (7.37 cm). Overall echogenicity is slightly hyperechoic with poor corticomedullary distinction and a typical 1:3 cortex:medulla ratio. There is no evidence of perinephric inflammation or effusion. There is no evidence of pyelectasia, nephroliths, infarcts or hydroureter. Renal vasculature is normal.

47.5 kg

**INTERPRETED BY**

**Adrenal Glands**

Kathleen Sennello DVM,  
MS, Diplomate ACVIM  
(Small Animal Internal  
Medicine)

The left adrenal gland is large in size measuring 2.6 cm at the cranial pole, 2.49 cm at the caudal pole, and 4.06 cm in length. It is observed in its normal position cranial to the left renal artery. It is somewhat irregular in appearance in that it is ovoid and hypoechoic, and large. There is no distinct vascular invasion, but on one video, there is questionable material within an adjacent vessel. This is not apparent in all images.

**IMAGING PERFORMED BY**

The right adrenal gland is normal in size measuring 0.91 cm at the caudal pole. It is observed in its normal position between the cranial aspect of the right kidney and the caudal vena cava. It is normal in appearance (uniformly hypoechoic) and shape with no evidence of a mass effect.

Kelly Reschny

**HOSPITAL NAME**

**Spleen**

Wellington AH

The spleen is subjectively normal in size, echotexture is homogenous, and the splenic capsule is smooth with no irregularities. The blood flow through the hilus and splenic parenchyma appears normal. No focal parenchymal abnormalities are visualized.

**REFERRING VET**

**Liver**

Dr. Dennis

The liver is subjectively normal in size, and echogenicity with smooth peripheral margins. The parenchyma is homogenous echotexture. The visible portions of the vasculature and biliary tract appear normal. No focal nodules or cystic lesions are observed.

**INVOICE**

37038

**DATE**

The gallbladder lumen is moderately distended. The wall of the gall bladder is not thickened and has a smooth mucosal surface. Luminal contents are primarily anechoic. The cystic and common bile ducts are normal/not visible.

4/20/22



**PATIENT** *Gastrointestinal*

Jip Streach The stomach contains minimal luminal contents. It measures at a normal thickness of <0.7cm with some variability due to the presence of rugal folds. The distinction of the gastric wall layers is adequate and there is no impression of reduced peristaltic activity. No masses or focal lesions were observed.

**SPECIES**

Canine

The visualized areas of duodenum, jejunum and ileum have a relatively uniform diameter with minimal fluid distension. Wall thickness is normal. Bowel loops follow a curvilinear path with distinct wall layering maintaining the typical 1:3 muscularis:mucosa layer ratio. The duodenum measured as normal (between 0.3-0.5cm in wall thickness) and the jejunum measured as normal (between 0.2-0.47cm.) Visualized peristalsis appears appropriate. There were no focal lesions consistent with obstruction or a mass effect observed.

**BREED**

Lab X

**SEX**

Neutered Male

The ileocecal junction was visualized and exhibited normal intact wall layering and is subjectively of normal thickness. Sections of colon are visualized with formed fecal material and gas shadowing distally. There is no observed focal or generalized colon wall thickening or loss of layering.

**Pancreas**

**AGE**

12 Years

The pancreas is normal and isoechoic to surrounding mesentery. There is no evidence of nodules or cystic lesions. There is no evidence of regional mesenteric inflammation or fluid.

**Free Abdomen**

**WEIGHT**

47.5 kg

Evaluation of the peritoneal cavity did not reveal any evidence of effusion, or subjective lymphadenomegaly. The Medial iliac nodes appear normal and there was no evidence of a caudal aortic thrombus at the bifurcation. The omentum is of normal uniform echogenicity.

**PRIMARY FINDINGS**

- Echogenic debris in the urinary bladder with questionable urinary bladder wall thickening and mucosal irregularity – findings are most consistent with bacterial cystitis, as no significant mass lesions or calculi are visualized. Recommend urinalysis and culture.
- Large, irregular left adrenal gland – Left adrenomegaly could be consistent with neoplasia (e.g., adenoma, carcinoma, pheochromocytoma), hyperplasia, inflammation, other.

**SECONDARY FINDINGS**

- Decreased corticomedullary distinction in both kidneys – The bilateral renal findings are consistent with age-related change.

**INTERPRETATION OF THE FINDINGS & FURTHER RECOMMENDATIONS**

There are no focal mass lesions or calculi visualized within the bladder or proximal urethra. There is echogenic urine, which I suspect is associated with the hematuria reported. Recommend urinalysis and culture. If this has already been done, and the urine is sterile, then consider other sources for the hematuria. The prostate appears grossly normal. You could consider a urine BRAF test to test for the mutation associated with the transitional cell carcinoma. If this test result was positive, I would be concerned about a small mass effect that we cannot visualized at this time. If this test is negative, it is a non-diagnostic test and further evaluation would be needed.

Alternately, occasionally you'll have benign essential hematuria arising from the kidneys. This is typically diagnosed based on excluding other sources and visualizing hemorrhage from the ureters either at surgery or with cystoscopy. Continued monitoring of the prostate is warranted in case there are early changes not visible with ultrasound.

**INTERPRETED BY**

Kathleen Sennello DVM,  
MS, Diplomate ACVIM  
(Small Animal Internal  
Medicine)

**IMAGING PERFORMED BY**

Kelly Reschny

**HOSPITAL NAME**

Wellington AH

**REFERRING VET**

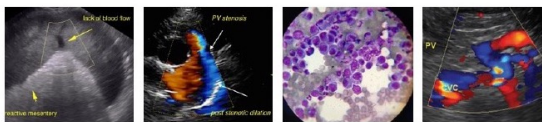
Dr. Dennis

**INVOICE**

37038

**DATE**

4/20/22



## PATIENT

Jip Stretch

Additionally, there is a mass effect involving the left adrenal gland. These lesions can be benign or malignant and can secrete hormones or be non-secretory. These are my recommendations for an adrenal mass:

## SPECIES

Canine

- If signs of cushings are present, consider adrenal function testing. I prefer an ACTH stimulation test combined with an adrenal panel to the University of Tennessee's endocrine lab to look for atypical adrenal hormones as well as cortisol. (other testing can suffice)

## BREED

Lab X

- If adrenal dependent cushings is suspected and supported by adrenal function testing consider medical therapy with lysodren or trilostane and/or consider surgical removal (recommend referral to a board certified veterinary surgeon and possible pre op CT)-This can be a challenging surgery with significant risk for complication

## SEX

Neutered Male

- Recommend blood pressure evaluation-if hypertensive consider testing catecholamine levels for a possible pheochromocytoma

## AGE

12 Years

- Due to the invasive nature of these masses a CT scan is recommended to evaluate for metastasis and vascular invasion.

## WEIGHT

47.5 kg

- If no symptoms of cushings are present, consider either referral for surgery or if surgery is not an option consultation with a veterinary oncologist regarding chemotherapeutic options and continued monitoring with ultrasound (in 4-6 weeks) can be considered.

- Some aggressive adrenal tumors can grow quickly and there is risk for acute hemorrhage from vascular invasion.

Consider three view thoracic radiographs to rule out concurrent thoracic disease/involvement

## INTERPRETED BY

Kathleen Sennello DVM,  
MS, Diplomate ACVIM  
(Small Animal Internal  
Medicine)

## IMAGING PERFORMED BY

Kelly Reschny

## HOSPITAL NAME

Wellington AH

## REFERRING VET

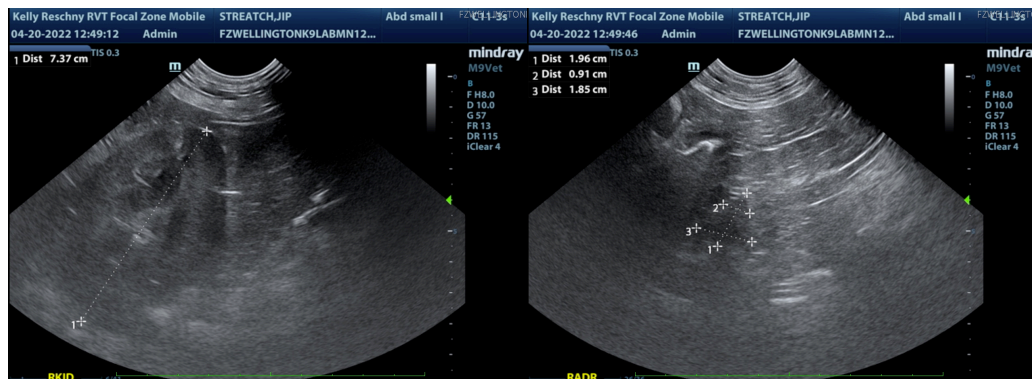
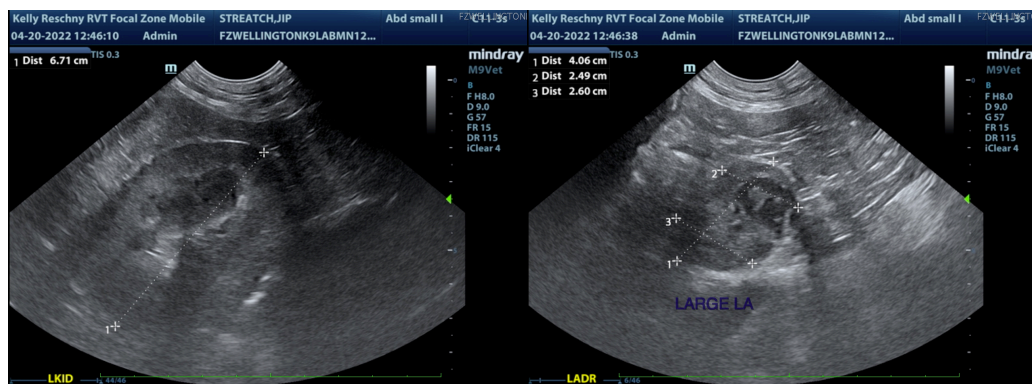
Dr. Dennis

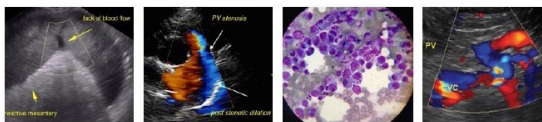
## INVOICE

37038

## DATE

4/20/22





**PATIENT**

Jip Stretch

**SPECIES**

Canine

**BREED**

Lab X

**SEX**

Neutered Male

**AGE**

12 Years

**WEIGHT**

47.5 kg

**INTERPRETED BY**

Kathleen Sennello DVM,  
MS, Diplomate ACVIM  
(Small Animal Internal  
Medicine)

**IMAGING  
PERFORMED BY**

Kelly Reschny

**HOSPITAL NAME**

Wellington AH

**REFERRING VET**

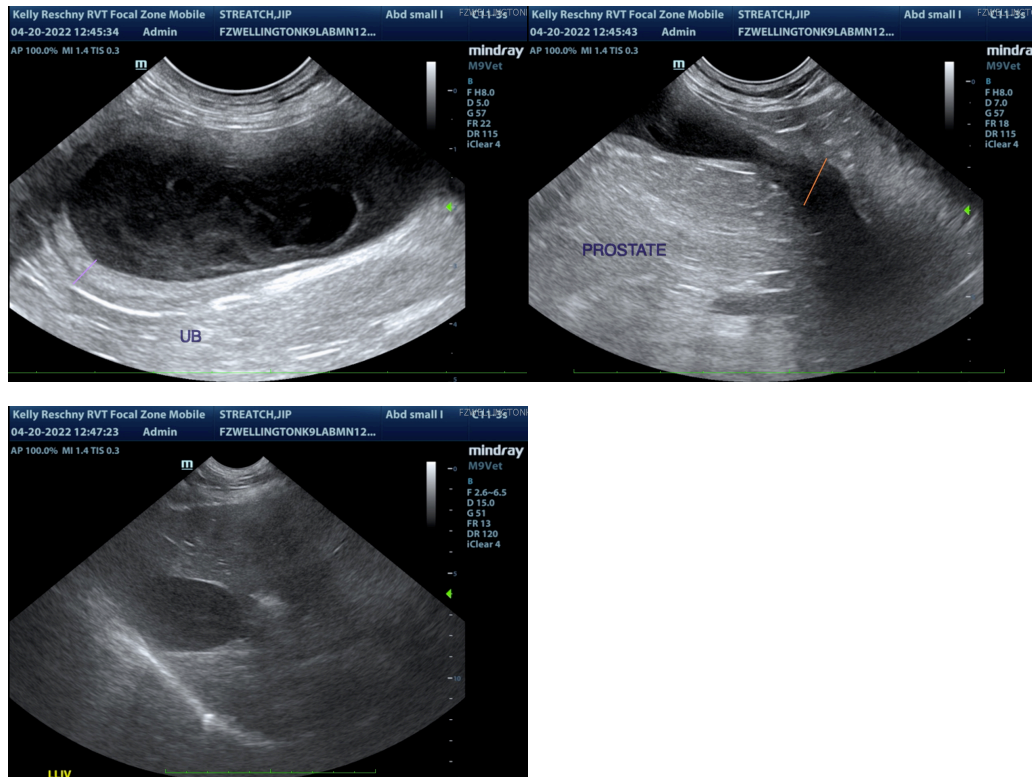
Dr. Dennis

**INVOICE**

37038

**DATE**

4/20/22



The information and recommendations provided are based on the images presented by the referring veterinarian/sonographer. No evaluation can be communicated regarding pathology that was not visible in the image/video clips provided.

Thank you for this referral. If the clinical or image interpretation does not parallel your findings or if I can be of any further assistance please contact me.

Kathleen Sennello DVM,MS, Diplomate ACVIM (Small animal Internal Medicine)

kathleen.sennello@sonopath.com