



PATIENT

Jack Brown

SPECIES

Canine

BREED

Lab Retriever

SEX

Spayed Female

AGE

12 Years

WEIGHT

48 lbs

INTERPRETED BY

Kathleen Sennello DVM,
 MS, Diplomate ACVIM
 (Small Animal Internal
 Medicine)

IMAGING PERFORMED BY

Kathleen Byrnes

HOSPITAL NAME

Shallowford Animal
 Hospital

REFERRING VET

Dr. Eads

INVOICE

74156

DATE

4/2/26

PRESENTING CLINICAL SIGNS

3/10/26- Annual exam, vaccines, librela Sr panel- Glob 4.5, ALKP 228, PSL 152. 3/19/26- trouble standing, not eating, large hot spots developed on back, mammary masses ruptured, started entyce, fluids, mirtazapine, Bloodwork BUN 175, CRea 8.7, Phos 13.3, SDMA 94.5, PSL 398, Tx for CRF. 3/26/26 kidney values improving now ALT(956), ALKP(2401) GGT 63). HCT 30, WBC 18.1, Neu 15,000, Mono 1448, usg 1.012, Pro 1+. Concern for Librela reaction (2nd injection), neoplasia, infectious, Ileus

ULTRASONOGRAPHIC EXAMINATION OF THE ABDOMEN

Urinary System

The urinary bladder is moderately distended with anechoic urine. The Bladder wall, trigone, ureteral papillae and visible urethra (to a depth of 2cm) appear normal with no evidence of wall thickening, mucosal irregularities, masses or cystic calculi.

The left kidney is borderline small in size and irregular in shape, measuring 6.11 cm, with irregular margins and occasional hyperechoic foci in the cortex most consistent with previous infarcts and areas of mineralization. There is a large cystic structure at the caudal pole measuring 1.75 cm in diameter, and pyelectasia at 0.29 cm. Overall echogenicity is normal with adequate corticomedullary distinction and a typical 1:3 cortex:medulla ratio. There is no evidence of focal perinephric inflammation or effusion. There is no evidence of hydroureter. Renal vasculature is normal.

The right kidney is borderline small in size, measuring 6.03 cm, with occasional cortical irregularities consistent with previous infarcts. Overall echogenicity is slightly hyperechoic with poor corticomedullary distinction and a typical 1:3 cortex:medulla ratio. There is no evidence of focal perinephric inflammation or effusion. There is no evidence of pyelectasia, nephroliths or hydroureter. Renal vasculature is normal.

Adrenal Glands

The left adrenal gland is normal in size measuring 0.54 cm at the cranial pole and 0.63 cm at the caudal pole. It is observed in its normal position cranial to the left renal artery. It is normal in appearance (uniformly hypoechoic) and shape with no evidence of a mass effect.

The right adrenal gland is normal in size measuring 0.91 cm at the cranial pole and 0.70 cm at the caudal pole. It is observed in its normal position between the cranial aspect of the right kidney and the caudal vena cava. It is normal in appearance (uniformly hypoechoic) and shape with no evidence of a mass effect.

Spleen

The spleen is subjectively normal in size (1.63 cm), echotexture is homogenous, and the splenic capsule is smooth with no irregularities. The blood flow through the hilus and splenic parenchyma appears normal. No focal parenchymal abnormalities are visualized.

Liver

The liver is subjectively normal in size, and echogenicity with smooth peripheral margins. The parenchyma is heterogenous in echotexture with subtle, indistinct focal mottling. The visible portions of the vasculature and biliary tract appear normal. There are occasional ill-defined hypoechoic nodules in the parenchyma. An example measures 1.23 cm.



PATIENT

Jack Brown

The gall bladder is large and distended, measuring approximately 6.0 cm x 4.0 cm. The bile duct is visualized and is mildly dilated, measuring at 0.33 cm. No evidence of a focal obstruction is visualized.

Gastrointestinal

SPECIES

Canine

The stomach contains a moderate amount of fluid. It measures at a normal thickness of <0.7cm with some variability due to the presence of rugal folds. The distinction of the gastric wall layers is adequate and there is no impression of reduced peristaltic activity. No masses or focal lesions were observed.

BREED

Lab Retriever

The visualized areas of duodenum, jejunum and ileum have a relatively uniform diameter with minimal fluid distension. Wall thickness is normal. Bowel loops follow a curvilinear path with distinct wall layering maintaining the typical 1:3 muscularis:mucosa layer ratio. Duodenum wall measures 0.45 cm. Jejunum wall measures 0.29 cm. Visualized peristalsis appears appropriate. There were no focal lesions consistent with obstruction or a mass effect observed.

SEX

Spayed Female

Sections of colon are visualized with formed fecal material and gas shadowing distally. There is no observed focal or generalized colon wall thickening or loss of layering.

AGE

12 Years

Pancreas

The pancreas is visible/mildly mottled in both limbs. There is no evidence of nodules or cystic lesions. There is no evidence of regional mesenteric inflammation or fluid.

WEIGHT

48 lbs

Free Abdomen

There is scant free fluid present. No lymphadenopathy noted. The omentum is generally of normal echogenicity.

INTERPRETED BY

Kathleen Sennello DVM,
 MS, Diplomate ACVIM
 (Small Animal Internal
 Medicine)

ULTRASONOGRAPHIC FINDINGS

- Bilateral renal changes consistent with chronic renal disease and left-sided pyelectasia – Pyelectasia of the left kidney could be consistent with pyelonephritis, chronic renal disease, secondary to PU/PD or fluid therapy (if applicable), other.
- Pancreatic changes most consistent with chronic pancreatic remodeling.
- Heterogeneous liver with ill-defined hypoechoic nodules – The diffuse hepatic changes are non-specific and could be consistent with vacuolar hepatopathy, nodular hyperplasia, inflammatory/immune-mediated disease, fibrosis, extramedullary hematopoiesis, toxic hepatopathy (e.g., copper), infiltrative neoplasia (less likely) or other hepatopathy. The nodules observed trend toward a more benign process, but underlying neoplasia cannot be ruled out.
- Large, distended gallbladder with a dilated bile duct – Findings could be consistent with a fasted patient, inflammation, an unseen obstruction, etc. Continued monitoring is recommended.
- Moderate fluid distention of the stomach – Correlate with the feeding history. If the patient was adequately fasted this could represent delayed gastric emptying or a partial outflow tract obstruction (none visualized).

IMAGING PERFORMED BY

Kathleen Byrnes

HOSPITAL NAME

Shallowford Animal
 Hospital

REFERRING VET

Dr. Eads

INVOICE

74156

DATE

4/2/26



PATIENT

Jack Brown

SPECIES

Canine

BREED

Lab Retriever

SEX

Spayed Female

AGE

12 Years

WEIGHT

48 lbs

INTERPRETATION OF THE FINDINGS & FURTHER RECOMMENDATIONS

Both kidneys have significant changes consistent with chronic renal disease. The described event sounds like an acute on chronic crisis. Correlate with a blood pressure, urinalysis and culture, and continued diuresis.

The liver is subjectively heterogeneous with occasional ill-defined hypoechoic nodules. The nodules generally have a somewhat benign appearance, but an early neoplastic lesion cannot be ruled out. An acute rise in liver enzymes could be due to infection, drug reaction, hypotensive episode, trauma, acute inflammation, etc. Recommend continued care for acute liver injury with supportive care, Ursodiol, Denamarin, antibiotics, etc., and close continued monitoring.

The stomach is moderately fluid distended. I suspect this is secondary to ileus. If fluid distention is persistent, reevaluation could be considered.

The gallbladder and the bile duct appear moderately distended. This could be normal for a fasted patient. Recommend continued monitoring of the bilirubin levels. If they continue to rise, consider repeat evaluation, looking for progressive distention.

If liver enzymes continue to rise despite aggressive supportive therapy with time for response to therapy, then consider a fine needle aspirate of the liver +/- biopsies with samples for histopathology, culture and copper levels (provided coagulation parameters are normal). Additionally, you could consider screening for Leptospirosis (if clinically appropriate).

INTERPRETED BY

Kathleen Sennello DVM,
 MS, Diplomate ACVIM
 (Small Animal Internal
 Medicine)

IMAGING PERFORMED BY

Kathleen Byrnes

HOSPITAL NAME

Shallowford Animal
 Hospital

REFERRING VET

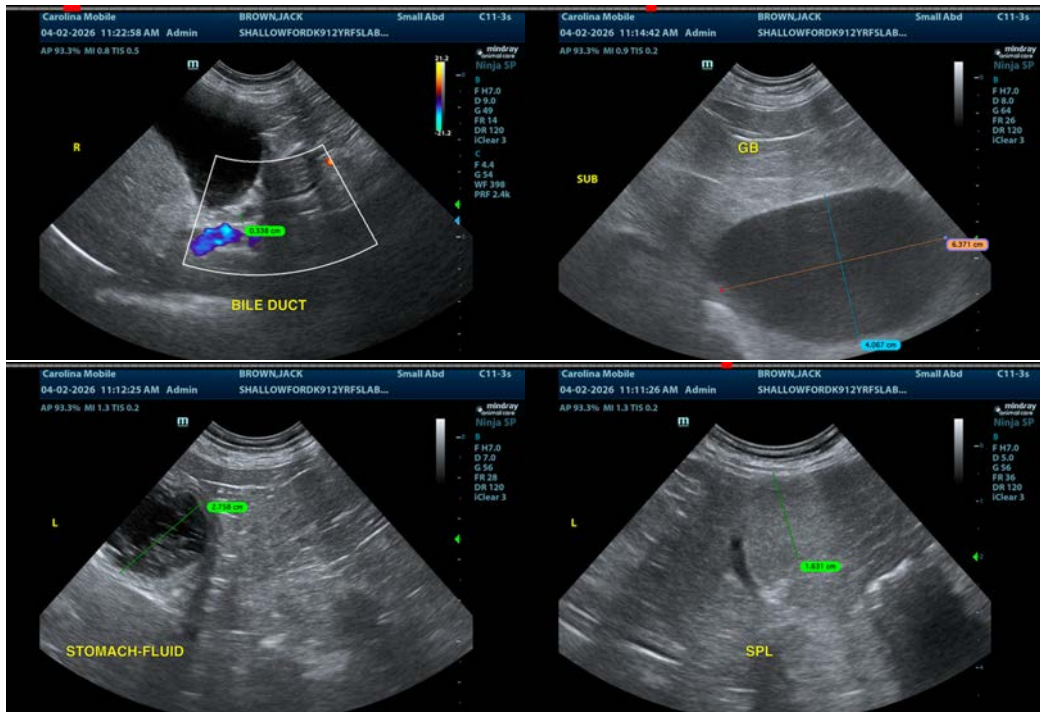
Dr. Eads

INVOICE

74156

DATE

4/2/26





PATIENT

Jack Brown

SPECIES

Canine

BREED

Lab Retriever

SEX

Spayed Female

AGE

12 Years

WEIGHT

48 lbs

INTERPRETED BY

Kathleen Sennello DVM,
 MS, Diplomate ACVIM
 (Small Animal Internal
 Medicine)

**IMAGING
 PERFORMED BY**

Kathleen Byrnes

HOSPITAL NAME

Shallowford Animal
 Hospital

REFERRING VET

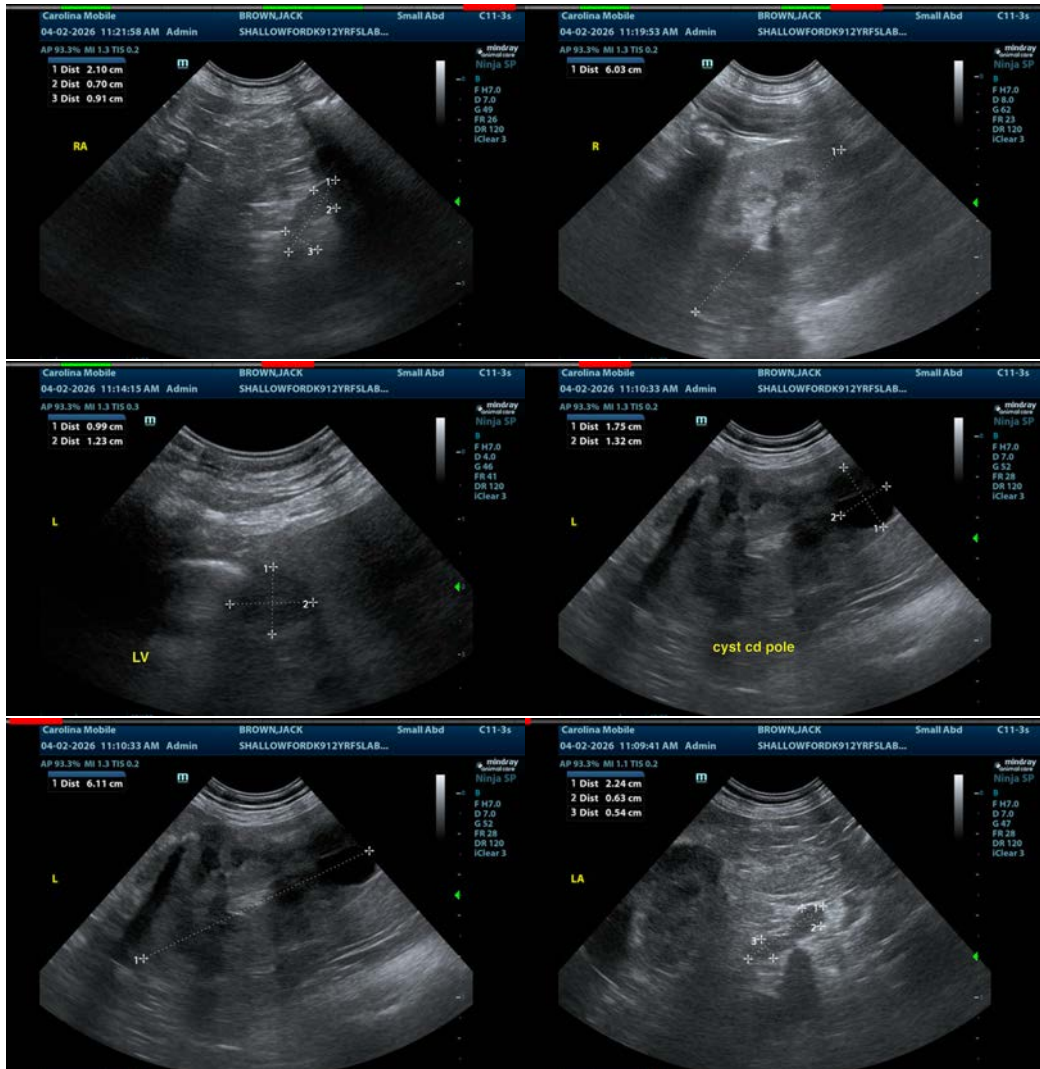
Dr. Eads

INVOICE

74156

DATE

4/2/26



The information and recommendations provided are based on the images presented by the referring veterinarian/sonographer. No evaluation can be communicated regarding pathology that was not visible in the image/video clips provided.

Thank you for this referral. If the clinical or image interpretation does not parallel your findings or if I can be of any further assistance please contact me.

Kathleen Sennello DVM,MS, Diplomate ACVIM (Small animal Internal Medicine)

info@sonopath.com