



PATIENT

Duke Naisani

SPECIES

Canine

BREED

Labradoodle

SEX

Neutered Male

AGE

7.5 Years

WEIGHT

38.0 kg

INTERPRETED BY

Kathleen Sennello DVM,
 MS, Diplomate ACVIM
 (Small Animal Internal
 Medicine)

IMAGING PERFORMED BY

Crystal Hill

HOSPITAL NAME

Headon Forest Animal
 Hospital

REFERRING VET

Dr. Gibson

INVOICE

74186

DATE

4/2/26

PRESENTING CLINICAL SIGNS

Healthy on PE, history of elbow dysplasia. Had been on Metacam but switched to Galliprant recently due to elevation in liver values, have not come down since switch. US to rule out structural liver disease

Galliprant 100mg SID. Gave low dose Torb and Alfaxan for scan.

Abnormal PE/Chem/CBC/UA Results: Milt increase in ALT showing steady increase, now at 280U/L.

ULTRASONOGRAPHIC EXAMINATION OF THE ABDOMEN

Urinary System

The urinary bladder is moderately distended with anechoic urine. The Bladder wall, trigone, ureteral papillae and visible urethra (to a depth of 2cm) appear normal with no evidence of wall thickening, mucosal irregularities, masses or cystic calculi.

The prostate is normal in size (0.83 cm) and shape for this neutered male dog. The parenchyma is homogenous and the external margins are smooth. The prostatic urethra appears normal with no evidence of irregularity, invasion, mass effect or calculi.

The left kidney has a normal shape and size (6.26 cm). Overall echogenicity is normal with adequate corticomedullary distinction and a typical 1:3 cortex:medulla ratio. There is no evidence of focal perinephric inflammation or effusion. There is no evidence of pyelectasia, nephroliths, infarcts or hydroureter. Renal vasculature is normal.

The right kidney has a normal shape and size (5.8 cm). Overall echogenicity is normal with adequate corticomedullary distinction and a typical 1:3 cortex:medulla ratio. There is no evidence of focal perinephric inflammation or effusion. There is no evidence of pyelectasia, nephroliths, infarcts or hydroureter. Renal vasculature is normal.

Adrenal Glands

The region of left adrenal (Cranial to left renal artery) is unremarkable but the adrenal is not distinctly visualized. No evidence of a mass effect is visualized.

The region of the right adrenal (between right cranial kidney and vena cava) is unremarkable, but the adrenal is not distinctly visualized. No evidence of a mass effect is visualized.

Spleen

The spleen is subjectively normal in size (2.26 cm), echotexture is homogenous, and the splenic capsule is smooth with no irregularities. The blood flow through the hilus and splenic parenchyma appears normal. No focal parenchymal abnormalities are visualized.

Liver

The liver is subjectively normal in size, and echogenicity with smooth peripheral margins. The parenchyma is homogenous echotexture. The visible portions of the vasculature and biliary tract appear normal. No focal nodules or cystic lesions are observed.



PATIENT

Duke Naisani

The gall bladder lumen is moderately distended. The wall of the gall bladder is not thickened and has a smooth mucosal surface. Luminal contents are mild and likely incidental at this time. The cystic and common bile ducts are normal/not visible.

SPECIES

Canine

Gastrointestinal

The stomach contains mild shadowing ingesta and fluid. It measures at a normal thickness of <0.7cm with some variability due to the presence of rugal folds. The distinction of the gastric wall layers is adequate and there is no impression of reduced peristaltic activity. There is a moderate amount of fluid and shadowing ingesta visualized within the stomach. If the patient was adequately fasted, consider such differentials as delayed gastric emptying or retained ingesta/foreign material. No evidence of an obstruction is visualized at this time.

BREED

Labradoodle

SEX

Neutered Male

The visualized areas of duodenum, jejunum and ileum have a relatively uniform diameter with minimal fluid distension. Wall thickness is normal. Bowel loops follow a curvilinear path with distinct wall layering maintaining the typical 1:3 muscularis:mucosa layer ratio. Duodenum wall measures 0.37 cm. Jejunum wall measures 0.32 cm. Visualized peristalsis appears appropriate. There were no focal lesions consistent with obstruction or a mass effect observed.

AGE

7.5 Years

Sections of colon are visualized with formed fecal material and gas shadowing distally. There is no observed focal or generalized colon wall thickening or loss of layering.

WEIGHT

38.0 kg

Pancreas

The pancreas is normal and isoechoic to surrounding mesentery. There is no evidence of nodules or cystic lesions. There is no evidence of regional mesenteric inflammation or fluid.

INTERPRETED BY

Kathleen Sennello DVM,
 MS, Diplomate ACVIM
 (Small Animal Internal
 Medicine)

Free Abdomen

Evaluation of the peritoneal cavity did not reveal any evidence of effusion, or subjective lymphadenomegaly. The Medial iliac nodes appear normal and there was no evidence of a caudal aortic thrombus at the bifurcation. The omentum is of normal uniform echogenicity.

IMAGING PERFORMED BY

Crystal Hill

ULTRASONOGRAPHIC FINDINGS

- No significant ultrasonographic lesions visualized.

HOSPITAL NAME

Headon Forest Animal
 Hospital

INTERPRETATION OF THE FINDINGS & FURTHER RECOMMENDATIONS

No structural abnormalities were visualized associated with the liver on today's exam. The gallbladder appears normal, most indicative of a primary hepatopathy. Consider the following:

REFERRING VET

Dr. Gibson

- Recommend pre- and post-prandial bile acids to assess liver function.
- If clinically appropriate, consider Leptospirosis testing.
- If acute liver injury is suspected, you could consider empirical treatment with a course of Ursodiol, Denamarin, +/- antibiotics.

INVOICE

74186

DATE

4/2/26

If liver enzymes are persistently elevated and/or liver function is abnormal, biopsies of the liver are likely necessary for further evaluation (histopathology, culture and copper levels).



PATIENT

Duke Naisani

SPECIES

Canine

BREED

Labradoodle

SEX

Neutered Male

AGE

7.5 Years

WEIGHT

38.0 kg

INTERPRETED BY

Kathleen Sennello DVM,
 MS, Diplomate ACVIM
 (Small Animal Internal
 Medicine)

**IMAGING
 PERFORMED BY**

Crystal Hill

HOSPITAL NAME

Headon Forest Animal
 Hospital

REFERRING VET

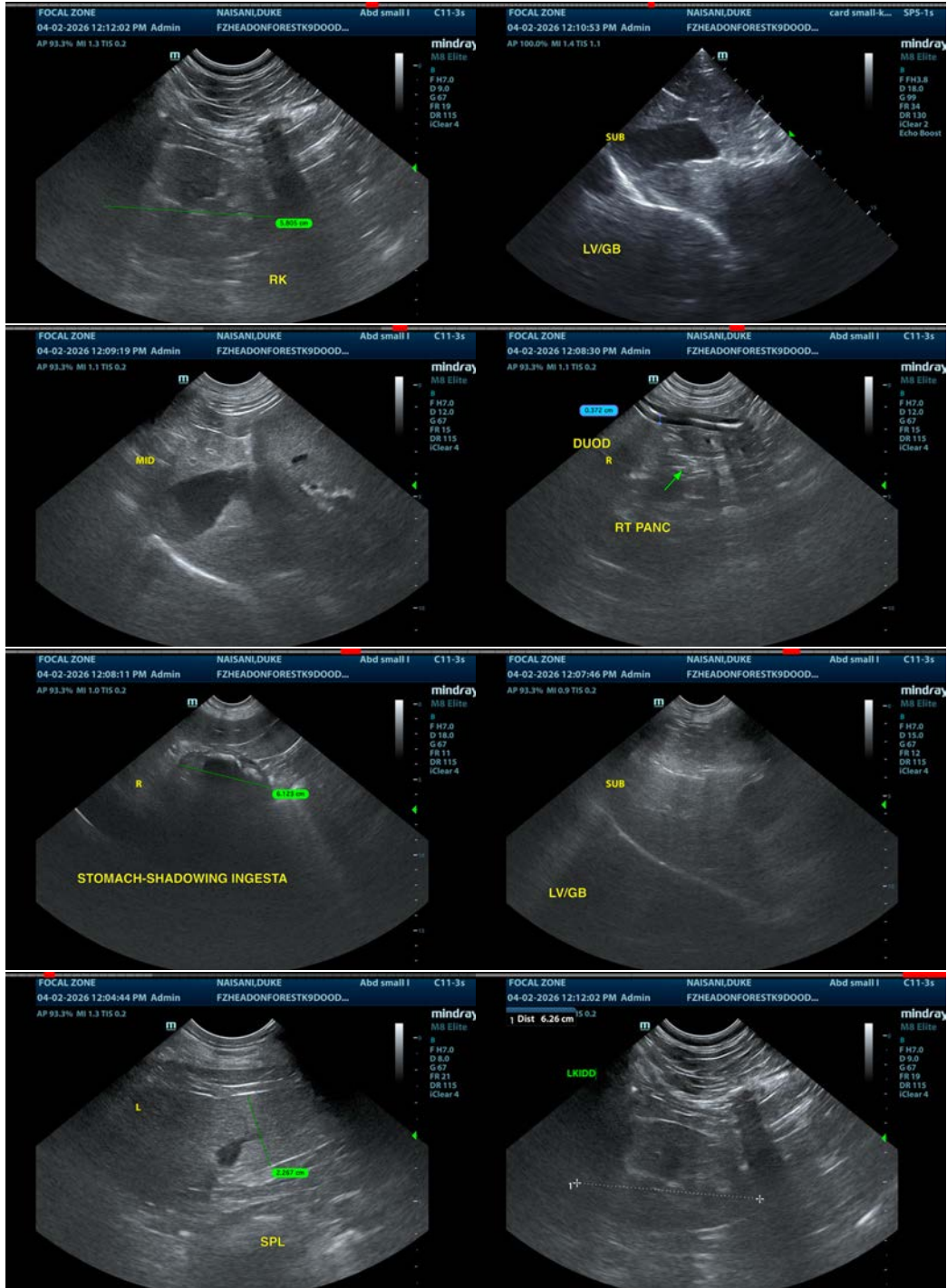
Dr. Gibson

INVOICE

74186

DATE

4/2/26





PATIENT

Duke Naisani

SPECIES

Canine

BREED

Labradoodle

SEX

Neutered Male

AGE

7.5 Years

WEIGHT

38.0 kg

INTERPRETED BY

Kathleen Sennello DVM,
MS, Diplomate ACVIM
(Small Animal Internal
Medicine)

**IMAGING
PERFORMED BY**

Crystal Hill

HOSPITAL NAME

Headon Forest Animal
Hospital

REFERRING VET

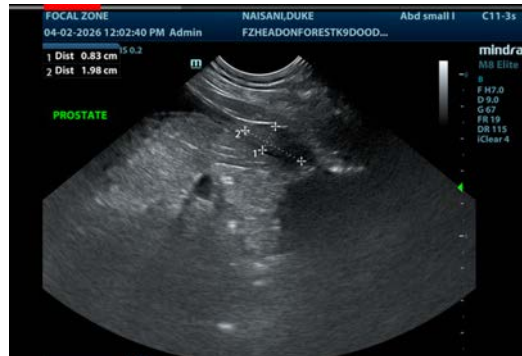Dr. Gibson

INVOICE

74186

DATE

4/2/26



The information and recommendations provided are based on the images presented by the referring veterinarian/sonographer. No evaluation can be communicated regarding pathology that was not visible in the image/video clips provided.

Thank you for this referral. If the clinical or image interpretation does not parallel your findings or if I can be of any further assistance please contact me.

Kathleen Sennello DVM,MS, Diplomate ACVIM (Small animal Internal Medicine)

info@sonopath.com