

PATIENT PRESENTING CLINICAL SIGNS

Stella Jaggard

History: lethargic, panting a lot, bloated abd

SPECIES

Canine

ULTRASONOGRAPHIC EXAMINATION OF THE ABDOMEN

BREED

G. Retr

Urinary System

The urinary bladder is moderately distended with anechoic urine. The Bladder wall, trigone, ureteral papillae, and visible urethra (to a depth of 2cm) appear normal with no evidence of wall thickening, mucosal irregularities, masses, or cystic calculi.

SEX

Spayed Female

The left kidney has a normal shape and size (6.93 cm). Overall echogenicity is normal with adequate corticomedullary distinction and a typical 1:3 cortex: medulla ratio. There is no evidence of focal perinephric inflammation or effusion. There is no evidence of pyelectasia, nephroliths, infarcts, or hydroureter. Renal vasculature is normal.

AGE

10yrs

The right kidney has a normal shape and size (6.03 cm). Overall echogenicity is normal with adequate corticomedullary distinction and a typical 1:3 cortex: medulla ratio. There is no evidence of focal perinephric inflammation or effusion. There is no evidence of pyelectasia, nephroliths, infarcts or hydroureter. Renal vasculature is normal.

WEIGHT

63lbs

Adrenal Glands

INTERPRETED BY

Kathleen Sennello DVM,
MS, Diplomate ACVIM
(Small Animal Internal
Medicine)

The left adrenal gland is normal in size measuring 0.59 cm at the caudal pole. It is observed in its normal position cranial to the left renal artery. It is normal in appearance (uniformly hypoechoic) and shape with no evidence of a mass effect.

The right adrenal gland is normal in size measuring 0.57 cm at the caudal pole. It is observed in its normal position between the cranial aspect of the right kidney and the caudal vena cava. It is normal in appearance (uniformly hypoechoic) and shape with no evidence of a mass effect.

IMAGING PERFORMED BY

Kelly Reschny

Spleen

HOSPITAL NAME

Maples AH

The spleen is subjectively normal in size, echotexture is homogenous, and the splenic capsule is smooth with no irregularities. The blood flow through the hilus and splenic parenchyma appears normal. No focal parenchymal abnormalities are visualized.

REFERRING VET

Dr. Kazienko

Liver

The liver is subjectively normal in size and echogenicity with smooth peripheral margins. The parenchyma is heterogenous in echotexture with subtle, indistinct focal mottling. The visible portions of the vasculature and biliary tract appear normal. No focal nodules or cystic lesions are observed.

INVOICE

10184

The gall bladder lumen is moderately distended. The wall of the gall bladder is not thickened and has a smooth mucosal surface. There is a moderate to large amount of non-organized echogenic debris. The cystic and common bile ducts are normal/not visible.

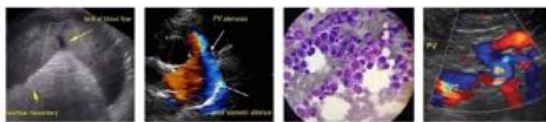
DATE

4-19-2023

Gastrointestinal

The stomach contains large shadowing ingesta. It measures at a normal thickness of <0.7cm with some variability due to the presence of rugal folds. The distinction of the gastric wall layers is adequate and there is no impression of reduced peristaltic activity. No masses or focal lesions were observed.

The visualized areas of duodenum, jejunum and ileum have a relatively uniform diameter with minimal fluid distension. Wall thickness is normal. Bowel loops follow a curvilinear path with distinct wall



PATIENT

Stella Jaggard

layering maintaining the typical 1:3 muscularis: mucosa layer ratio. The duodenum measured as normal (0.5 cm), and the jejunum measured as normal (0.36 cm.) Visualized peristalsis appears appropriate. There were no focal lesions consistent with obstruction or a mass effect observed.

SPECIES

Canine

The ileocecal junction was visualized and exhibited normal intact wall layering and is subjectively of normal thickness. Sections of colon are visualized with formed fecal material and gas shadowing distally. There is no observed focal or generalized colon wall thickening or loss of layering.

BREED

Pancreas

G. Retr

The pancreas is normal and isoechoic to surrounding mesentery. There is no evidence of nodules or cystic lesions. There is no evidence of regional mesenteric inflammation or fluid.

SEX

Spayed Female

Free Abdomen

Evaluation of the peritoneal cavity did not reveal any evidence of effusion, or subjective lymphadenomegaly. The Medial iliac nodes appear normal and there was no evidence of a caudal aortic thrombus at the bifurcation. The omentum is of normal uniform echogenicity.

AGE

10yrs

PRIMARY FINDINGS

WEIGHT

63lbs

- Heterogenous liver. The diffuse hepatic changes are non-specific and could be consistent with vacuolar hepatopathy, nodular hyperplasia, inflammatory/immune-mediated disease, fibrosis, extramedullary hematopoiesis, toxic hepatopathy (e.g., copper), infiltrative neoplasia (less likely) or other hepatopathy. Correlate with bloodwork if there are no significant liver enzyme elevations, this could be within normal limits for this individual.
- Large gallbladder debris. The significance of the aggregated large gallbladder debris is unclear. This could represent an early mucocele, cholestasis, or may be secondary to fasting but seems unlikely to be causing a current issue. Recommend continued monitoring.
- Large shadowing ingesta visualized within the gastric lumen. Correlate with the feeding history and abdominal radiographs. If the patient was adequately fasted consider such differentials as delayed gastric emptying, a partial outflow tract obstruction (none seen) or ingested foreign material.

INTERPRETED BY

Kathleen Sennello DVM,
MS, Diplomate ACVIM
(Small Animal Internal
Medicine)

**IMAGING
PERFORMED BY**

Kelly Reschny

HOSPITAL NAME

Maples AH

INTERPRETATION OF THE FINDINGS & FURTHER RECOMMENDATIONS

REFERRING VET

Dr. Kazienko

The changes observed on today's scan are relatively mild and non-specific. The liver appears somewhat heterogenous, this could be consistent with age-related remodeling or with a primary hepatopathy if liver enzyme elevations are present.

INVOICE

10184

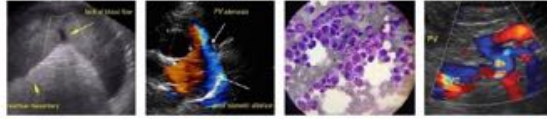
Additionally, there is a large amount of hyperechoic debris visualized within the gallbladder lumen but the gallbladder wall appears relatively normal with no surrounding inflammation. If significant cholestatic enzymes elevations are present you could consider starting ursodiol and continuing to monitor the gallbladder, but I suspect this is not a clinical problem at this time.

DATE

4-19-2023

The stomach is significantly distended with what appears to be shadowing ingesta. If the patient was adequately fasted, then consider reevaluation after fasting. Correlate with abdominal radiographs etc.

An obvious cause for the abdominal distention is not observed. Recommend 3-view thoracic radiographs, +/- cardiac evaluation, and close continued monitoring.



PATIENT

Stella Jaggard

SPECIES

Canine

BREED

G. Retr

SEX

Spayed Female

AGE

10yrs

WEIGHT

63lbs

INTERPRETED BY

Kathleen Sennello DVM,
MS, Diplomate ACVIM
(Small Animal Internal
Medicine)

**IMAGING
PERFORMED BY**

Kelly Reschny

HOSPITAL NAME

Maples AH

REFERRING VET

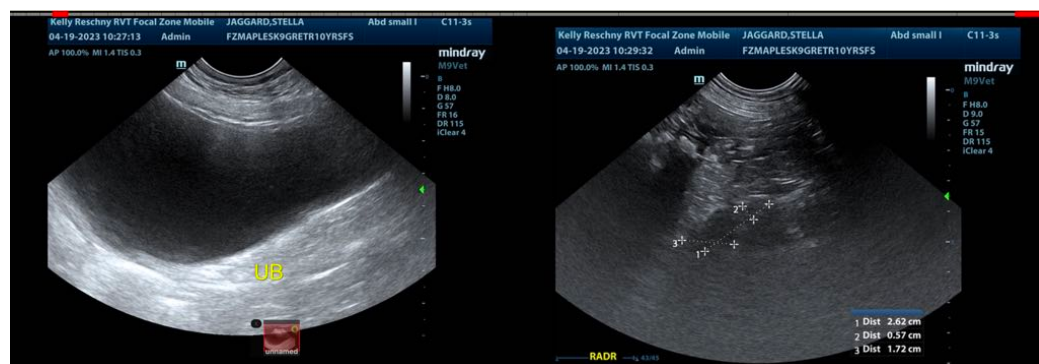
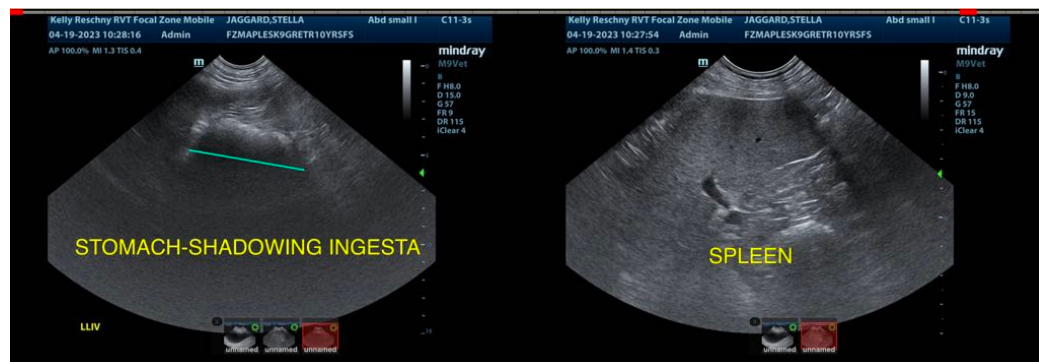
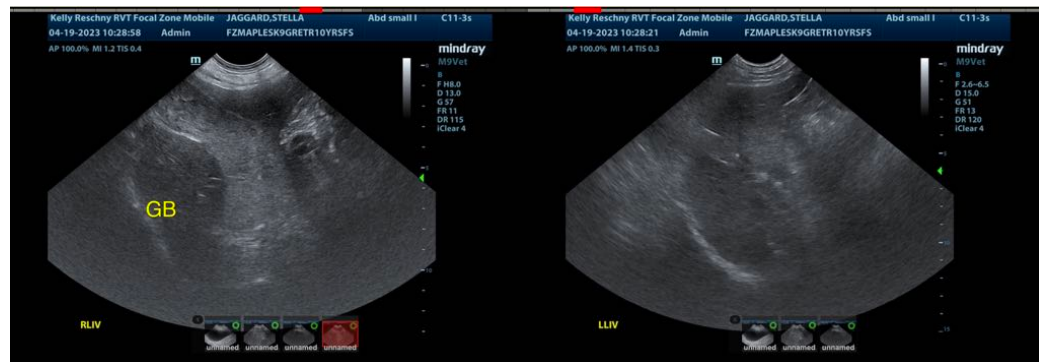
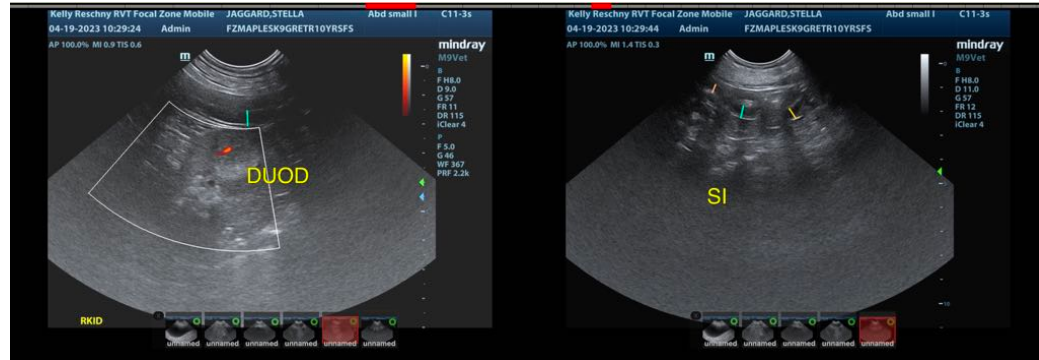
Dr. Kazienko

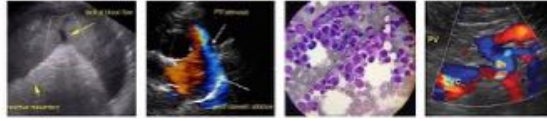
INVOICE

10184

DATE

4-19-2023





PATIENT

Stella Jaggard

SPECIES

Canine

BREED

G. Retr

SEX

Spayed Female

AGE

10yrs

WEIGHT

63lbs

INTERPRETED BY

Kathleen Sennello DVM,
MS, Diplomate ACVIM
(Small Animal Internal
Medicine)

**IMAGING
PERFORMED BY**

Kelly Reschny

HOSPITAL NAME

Maples AH

REFERRING VET

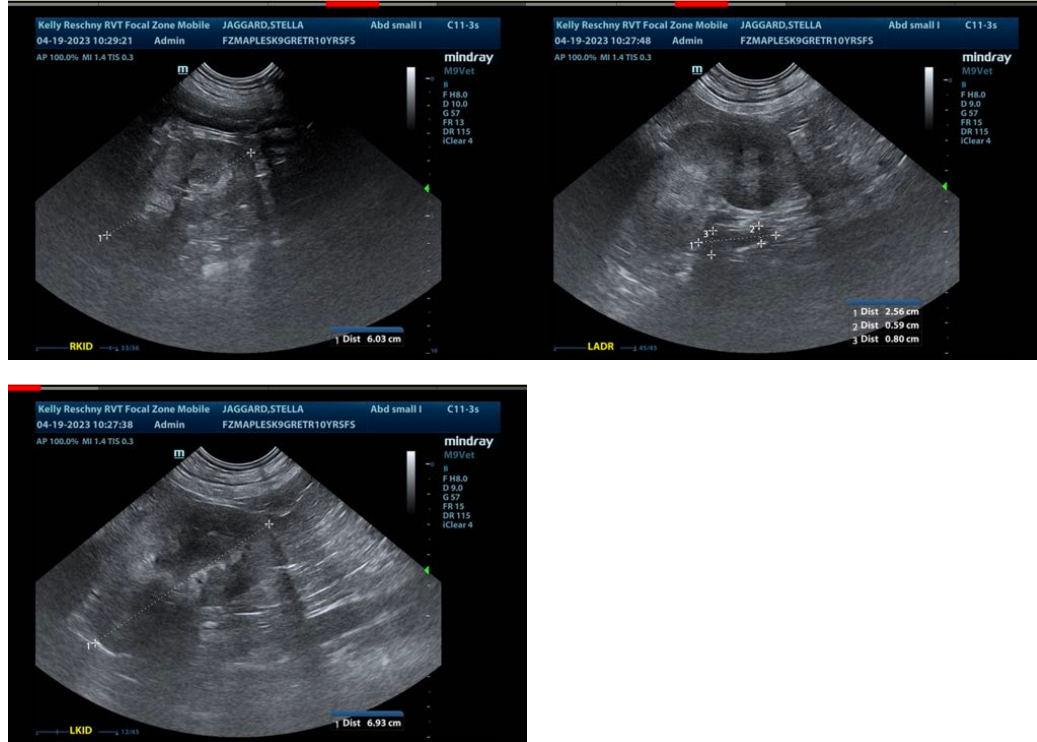
Dr. Kazienko

INVOICE

10184

DATE

4-19-2023



The information and recommendations provided are based on the images presented by the referring veterinarian/sonographer. No evaluation can be communicated regarding pathology that was not visible in the image/video clips provided.

Thank you for this referral. If the clinical or image interpretation does not parallel your findings or if I can be of any further assistance, please contact me.

Kathleen Sennello DVM, MS, Diplomate ACVIM (Small animal Internal Medicine)

kathleen.sennello@sonopath.com