

**PATIENT PRESENTING CLINICAL SIGNS**

Meesha Cortright History \* history of splenic nodules- monitoring via AUS- recheck.

**SPECIES**

Canine

**BREED**

Husky Mix

**SEX**

Spayed Female

**AGE**

7y8m

**WEIGHT**

29.8kg

**INTERPRETED BY**

Kathleen Sennello DVM,  
MS, Diplomate ACVIM  
(Small Animal Internal  
Medicine)

**IMAGING PERFORMED BY**

Loetitia Saint-Jacques,  
LVT

**HOSPITAL NAME**

Grass Valley Veterinary  
Hospital

**REFERRING VET**

Dr. Kristi Cortright

**INVOICE**

10186

**DATE**

4/19/2023

Abnormal PE/Chem/CBC/UA Results: Labs done in 12/2022, WNL.

**ULTRASONOGRAPHIC EXAMINATION OF THE ABDOMEN**

**Urinary System**

The urinary bladder is moderately distended with anechoic urine. The Bladder wall, trigone, ureteral papillae, and visible urethra (to a depth of 2cm) appear normal with no evidence of wall thickening, mucosal irregularities, masses, or cystic calculi.

The left kidney has a normal shape and size (6 cm). Overall echogenicity is normal with adequate corticomedullary distinction and a typical 1:3 cortex: medulla ratio. There is no evidence of focal perinephric inflammation or effusion. There is no evidence of pyelectasia, nephroliths, infarcts or hydroureter. Renal vasculature is normal.

The right kidney has a normal shape and size (5.99 cm). Overall echogenicity is normal with adequate corticomedullary distinction and a typical 1:3 cortex: medulla ratio. There is no evidence of focal perinephric inflammation or effusion. There is no evidence of pyelectasia, nephroliths, infarcts or hydroureter. Renal vasculature is normal.

**Adrenal Glands**

The left adrenal gland is normal in size measuring 0.72 cm at the caudal pole. It is observed in its normal position cranial to the left renal artery. It is normal in appearance (uniformly hypoechoic) and shape with no evidence of a mass effect.

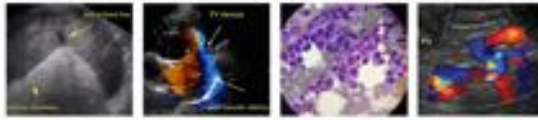
The right adrenal gland is normal in size measuring 0.68 cm at the caudal pole. It is observed in its normal position between the cranial aspect of the right kidney and the caudal vena cava. It is normal in appearance (uniformly hypoechoic) and shape with no evidence of a mass effect.

**Spleen**

The spleen is normal in size, with mildly mottled parenchyma. There are numerous irregular, somewhat ill-defined hypoechoic moth-eaten regions in the spleen. Due to the nature of the spleen (freely movable in the abdomen) and the irregular nature of these lesions, it is difficult to follow them with specific measurements over time. Examples of measurements obtained today include lesions measuring 1.8 cm, 0.67 cm, 1.7 cm, 1.65 cm, and 0.86 cm in diameter. The most prominent specific lesion visible in the tip of the tail of the spleen measuring 1.03 cm x 2.06 cm. These measurements trend towards slightly larger than the previous scan, but not significantly so as all nodules remain generally below 2 cm in size.

**Liver**

The liver is subjectively normal in size and echogenicity with smooth peripheral margins. The parenchyma is heterogenous in echotexture with subtle, indistinct focal mottling. The visible portions of the vasculature and biliary tract appear normal. There are numerous nodules visualized in the liver,



**PATIENT**

Meesha Cortright

**SPECIES**

Canine

**BREED**

Husky Mix

**SEX**

Spayed Female

**AGE**

7y8m

**WEIGHT**

29.8kg

**INTERPRETED BY**

Kathleen Sennello DVM,  
MS, Diplomate ACVIM  
(Small Animal Internal  
Medicine)

**IMAGING  
PERFORMED BY**

Loetitia Saint-Jacques,  
LVT

**HOSPITAL NAME**

Grass Valley Veterinary  
Hospital

**REFERRING VET**

Dr. Kristi Cortright

**INVOICE**

10186

**DATE**

4/19/2023

some are hyperechoic, and some are hypoechoic. An example of a hyperechoic nodule measures 1.32 cm. Two ill-defined hypoechoic nodules measure 1.16 cm x 1.18 cm.

The gallbladder lumen is moderately distended. The wall of the gall bladder is not thickened and has a smooth mucosal surface. Luminal contents are mild and primarily anechoic. The cystic and common bile ducts are normal/not visible.

**Gastrointestinal**

The stomach contains minimal luminal contents. It measures at a normal thickness of <0.7cm with some variability due to the presence of rugal folds. The distinction of the gastric wall layers is adequate and there is no impression of reduced peristaltic activity. No masses or focal lesions were observed.

The visualized areas of duodenum, jejunum and ileum have a relatively uniform diameter with minimal fluid distension. Wall thickness is normal. Bowel loops follow a curvilinear path with distinct wall layering maintaining the typical 1:3 muscularis: mucosa layer ratio. The duodenum measured as normal (0.47 cm), and the jejunum measured as normal (0.4 cm.) Visualized peristalsis appears appropriate. There were no focal lesions consistent with obstruction or a mass effect observed.

The ileocecal junction was visualized and exhibited normal intact wall layering and is subjectively of normal thickness. Sections of colon are visualized with formed fecal material and gas shadowing distally. There is no observed focal or generalized colon wall thickening or loss of layering.

**Pancreas**

The pancreas is normal and isoechoic to surrounding mesentery. There is no evidence of nodules or cystic lesions. There is no evidence of regional mesenteric inflammation or fluid.

**Free Abdomen**

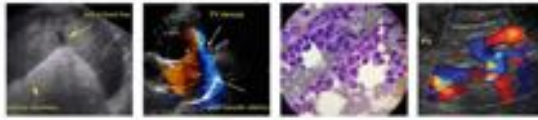
Evaluation of the peritoneal cavity did not reveal any evidence of effusion. There are visible/slightly prominent mesenteric lymph nodes. The pancreaticoduodenal lymph node measures 0.83 cm in diameter (previous measurement 0.74 cm). A mesenteric lymph node is measured at 0.37 cm. These lymph nodes appear similar to the previous scan. The omentum is generally of normal echogenicity but there is a very ill-defined patchy hypoechoic region caudal to the left kidney measuring approximately 1.22 cm x 2.6 cm.

**Other**

The right auricle and pericardium were visualized and were unremarkable. No obvious pathology is visualized. If cardiac function evaluation is desired a full echocardiogram is warranted.

**PRIMARY FINDINGS**

- Numerous ill-defined irregular moth-eaten lesions visualized within the splenic parenchyma. These lesions appear relatively stable/slightly larger than the previous scan.
- Hyper and hypoechoic nodules visualized in the liver. All of these lesions are relatively small in size and subtle in nature. The appearance of the hyperechoic nodules trends towards benign ideology as do the hypoechoic nodules but continued monitoring is warranted.
- Slightly prominent/stable mesenteric lymph nodes. The prominent abdominal lymph nodes



**PATIENT**

Meesha Cortright

**SPECIES**

Canine

**BREED**

Husky Mix

**SEX**

Spayed Female

**AGE**

7y8m

**WEIGHT**

29.8kg

**INTERPRETED BY**

Kathleen Sennello DVM,  
MS, Diplomate ACVIM  
(Small Animal Internal  
Medicine)

**IMAGING PERFORMED BY**

Loetitia Saint-Jacques,  
LVT

**HOSPITAL NAME**

Grass Valley Veterinary  
Hospital

**REFERRING VET**

Dr. Kristi Cortright

**INVOICE**

10186

**DATE**

4/19/2023

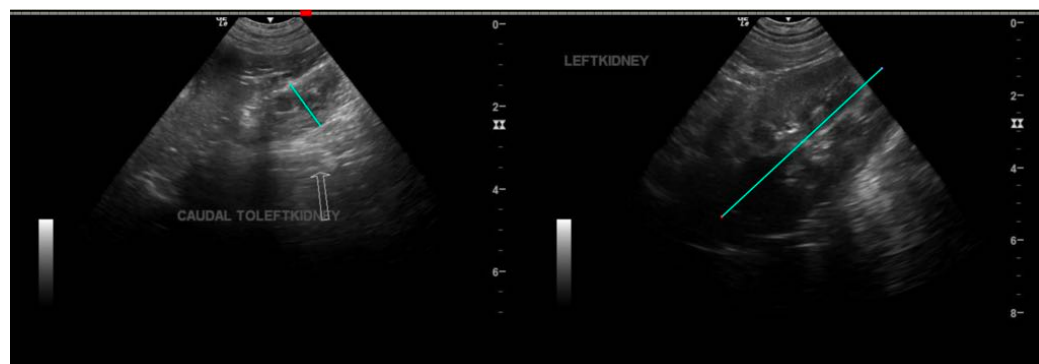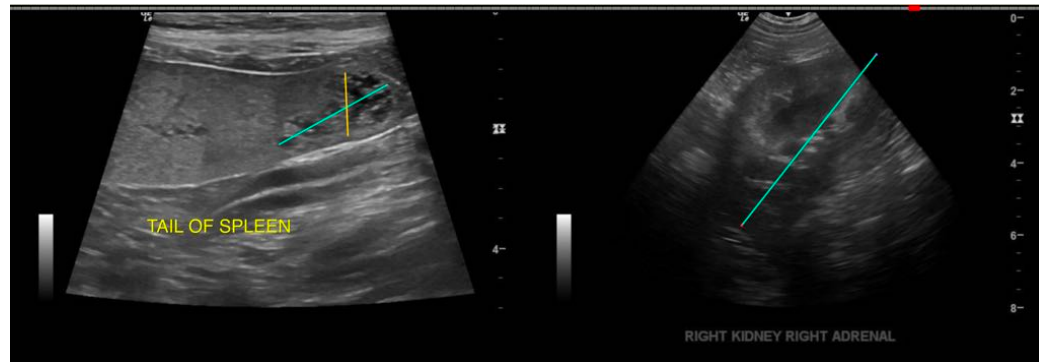
are most consistent with reactive lymphadenitis or lymphoid hyperplasia. Neoplastic infiltration is considered less likely.

- Irregular hypoechoic mesentery caudal to the left kidney. The significance of this is unclear. Recommend continued monitoring.

**INTERPRETATION OF THE FINDINGS & FURTHER RECOMMENDATIONS**

Overall today's scan appears relatively similar to the previous scan on 8/5/2022. The splenic lesions may be getting slightly bigger but not quickly and the nodules in the liver do not appear particularly expansile at this time.

The nature of the hypoechoic tissue caudal to the left kidney is uncertain. This is very subtle but should be monitored for progression.





**PATIENT**

Meesha Cortright

**SPECIES**

Canine

**BREED**

Husky Mix

**SEX**

Spayed Female

**AGE**

7y8m

**WEIGHT**

29.8kg

**INTERPRETED BY**

Kathleen Sennello DVM,  
MS, Diplomate ACVIM  
(Small Animal Internal  
Medicine)

**IMAGING  
PERFORMED BY**

Loetitia Saint-Jacques,  
LVT

**HOSPITAL NAME**

Grass Valley Veterinary  
Hospital

**REFERRING VET**

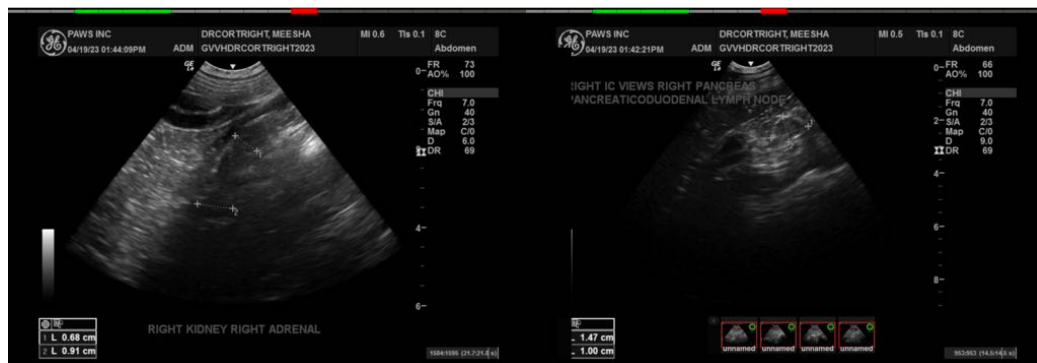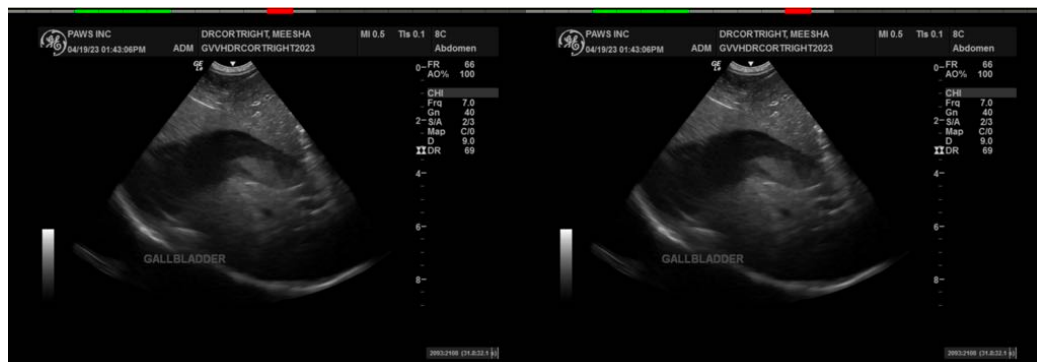
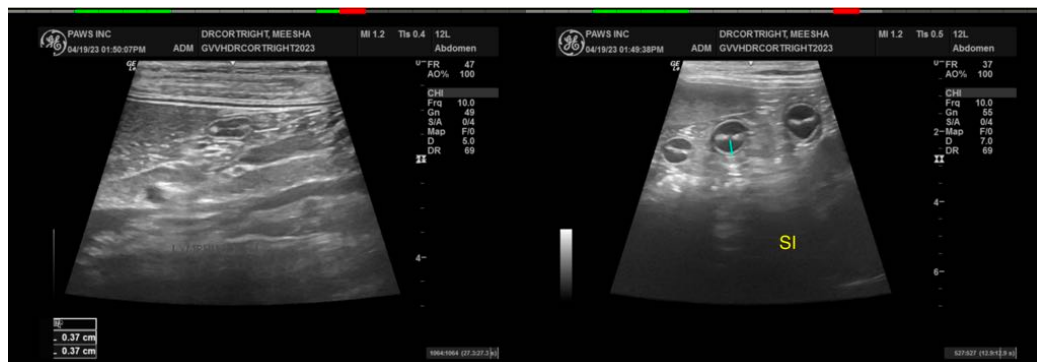
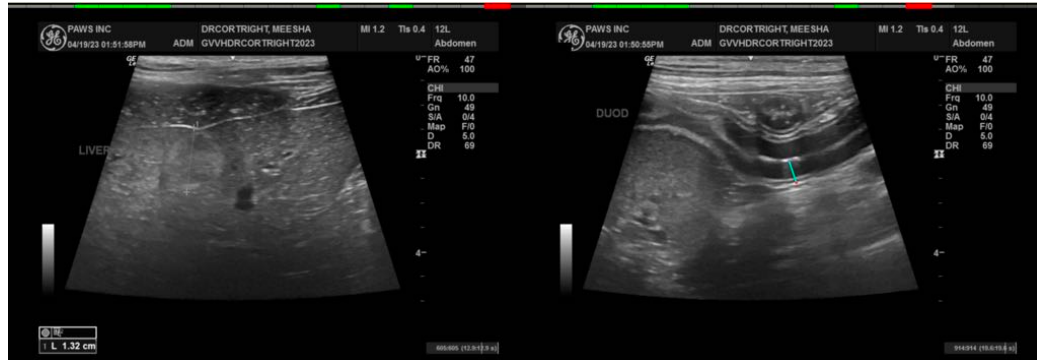
Dr. Kristi Cortright

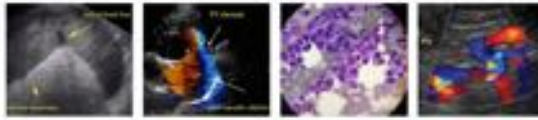
**INVOICE**

10186

**DATE**

4/19/2023





**PATIENT**

Meesha Cortright

**SPECIES**

Canine

**BREED**

Husky Mix

**SEX**

Spayed Female

**AGE**

7y8m

**WEIGHT**

29.8kg

**INTERPRETED BY**

Kathleen Sennello DVM,  
MS, Diplomate ACVIM  
(Small Animal Internal  
Medicine)

**IMAGING PERFORMED BY**

Loetitia Saint-Jacques,  
LVT

**HOSPITAL NAME**

Grass Valley Veterinary  
Hospital

**REFERRING VET**

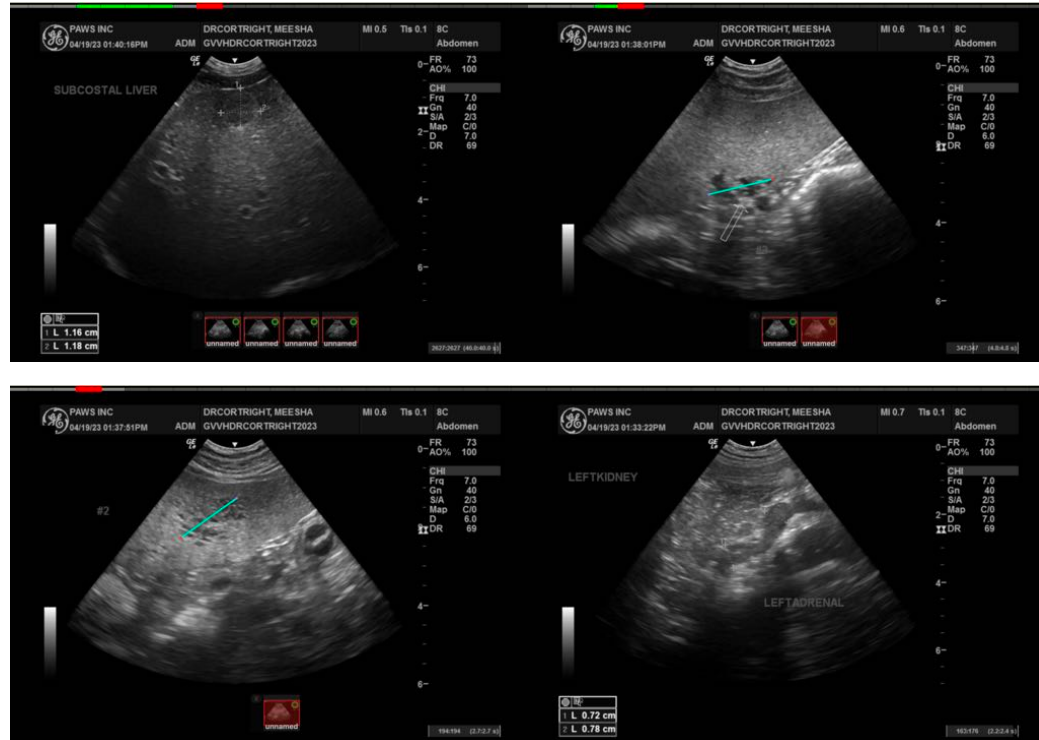
Dr. Kristi Cortright

**INVOICE**

10186

**DATE**

4/19/2023



The information and recommendations provided are based on the images presented by the referring veterinarian/sonographer. No evaluation can be communicated regarding pathology that was not visible in the image/video clips provided.

Thank you for this referral. If the clinical or image interpretation does not parallel your findings or if I can be of any further assistance, please contact me.

Kathleen Sennello DVM, MS, Diplomate ACVIM (Small animal Internal Medicine)

kathleen.sennello@sonopath.com