



PATIENT

Finn Blash

SPECIES

Canine

BREED

Mix

SEX

Neutered Male

AGE

2 Years 10 Months

WEIGHT

81 Pounds

INTERPRETED BY

Kathleen Sennello DVM,
MS, Diplomate ACVIM
(Small Animal Internal
Medicine)

**IMAGING
PERFORMED BY**

Shari Reffi, CVT

HOSPITAL NAME

Blairstown AH

REFERRING VET

Dr. Summers

INVOICE

46742

DATE

4/19/23

PRESENTING CLINICAL SIGNS

Poss. FB, ate tissue. Vomiting

ULTRASONOGRAPHIC EXAMINATION OF THE ABDOMEN

Urinary System

The urinary bladder is moderately distended with anechoic urine. The Bladder wall, trigone, ureteral papillae and visible urethra (to a depth of 2cm) appear normal with no evidence of wall thickening, mucosal irregularities, masses or cystic calculi.

The prostate is normal in size (1.3 cm) and shape for this neutered male dog. The parenchyma is homogenous and the external margins are smooth. The prostatic urethra appears normal with no evidence of irregularity, invasion, mass effect or calculi.

The left kidney has a normal shape and size (6.42 cm). Overall echogenicity is normal with adequate corticomedullary distinction and a typical 1:3 cortex:medulla ratio. There is no evidence of focal perinephric inflammation or effusion. There is no evidence of pyelectasia, nephroliths, infarcts or hydroureter. Renal vasculature is normal.

The right kidney has a normal shape and size (6.94 cm). Overall echogenicity is normal with adequate corticomedullary distinction and a typical 1:3 cortex:medulla ratio. There is no evidence of focal perinephric inflammation or effusion. There is no evidence of pyelectasia, nephroliths, infarcts or hydroureter. Renal vasculature is normal.

Adrenal Glands

The left adrenal gland is normal in size measuring 0.45 cm at the caudal pole. It is observed in its normal position cranial to the left renal artery. It is normal in appearance (uniformly hypoechoic) and shape with no evidence of a mass effect.

The right adrenal gland is normal in size measuring 0.68 cm at the caudal pole. It is observed in its normal position between the cranial aspect of the right kidney and the caudal vena cava. It is normal in appearance (uniformly hypoechoic) and shape with no evidence of a mass effect.

Spleen

The spleen is subjectively normal in size, echotexture is homogenous, and the splenic capsule is smooth with no irregularities. The blood flow through the hilus and splenic parenchyma appears normal. No focal parenchymal abnormalities are visualized.

Liver

The liver is subjectively normal in size, and echogenicity with smooth peripheral margins. The parenchyma is homogenous echotexture. The visible portions of the vasculature and biliary tract appear normal. No focal nodules or cystic lesions are observed.

The gallbladder lumen is moderately distended. The wall of the gall bladder is not thickened and has a smooth mucosal surface. Luminal contents are mild and primarily anechoic. The cystic and common bile ducts are normal/not visible.



PATIENT

Finn Blash

SPECIES

Canine

BREED

Mix

SEX

Neutered Male

AGE

2 Years 10 Months

WEIGHT

81 Pounds

INTERPRETED BY

Kathleen Sennello DVM,
MS, Diplomate ACVIM
(Small Animal Internal
Medicine)

**IMAGING
PERFORMED BY**

Shari Reffi, CVT

HOSPITAL NAME

Blairstown AH

REFERRING VET

Dr. Summers

INVOICE

46742

DATE

4/19/23

Gastrointestinal

The stomach contains mild fluid. The gastric wall is slightly prominent measuring 0.47 cm in thickness with intact wall layering. The distinction of the gastric wall layers is adequate and there is no impression of reduced peristaltic activity. No masses or focal lesions were observed.

The visualized areas of duodenum, jejunum and ileum have a relatively uniform diameter with minimal fluid distension. Wall thickness is normal. Bowel loops follow a curvilinear path with distinct wall layering maintaining the typical 1:3 muscularis:mucosa layer ratio. Duodenum wall measures 0.54 cm. Jejunum wall measures 0.36 cm. Visualized peristalsis appears appropriate. There were no focal lesions consistent with obstruction or a mass effect observed.

The ileocecal junction was visualized and exhibited normal intact wall layering and is subjectively of normal thickness. The colon appears diffusely dilated with echogenic fluid. In some areas of the colon, this echogenic fluid has some shadowing material visualized within it. In some area, the shadowing is somewhat focal, consistent with passing material.

Pancreas

The pancreas is normal and isoechoic to surrounding mesentery. There is no evidence of nodules or cystic lesions. There is no evidence of regional mesenteric inflammation or fluid.

Free Abdomen

Evaluation of the peritoneal cavity did not reveal any evidence of effusion. There are occasional prominent mesenteric lymph nodes. One such lymph node measures 0.54 cm. A sublumbal lymph node is slightly prominent, measuring at 0.98 cm in width. The omentum is of normal echogenicity.

ULTRASONOGRAPHIC FINDINGS

- Subjectively prominent gastric wall – Findings could be consistent with mild gastritis.
- Fluid dilated colon with hard shadowing intraluminal material.
- Prominent mesenteric lymph nodes – The prominent abdominal lymph nodes are most consistent with reactive lymphadenitis or lymphoid hyperplasia. Neoplastic infiltration is considered less likely.

INTERPRETATION OF THE FINDINGS & FURTHER RECOMMENDATIONS

There is no evidence of a significant obstructive pattern involving the stomach or the small intestine, but the colon does appear diffusely fluid dilated with echogenic fluid and some focal shadowing material. This material could consist of firm fecal balls, foreign bodies, etc. My hope is that this material will pass as long as this patient is very well hydrated and encourage to defecate. Correlate these findings with abdominal radiographs. If symptoms persist, consider repeat imaging, as a true obstruction or a more cranial foreign material cannot be definitively ruled out. I suspect the subtle changes visualized associated with the gastric wall are most consistent with gastritis.



PATIENT

Finn Blash

SPECIES

Canine

BREED

Mix

SEX

Neutered Male

AGE

2 Years 10 Months

WEIGHT

81 Pounds

INTERPRETED BY

Kathleen Sennello DVM,
MS, Diplomate ACVIM
(Small Animal Internal
Medicine)

**IMAGING
PERFORMED BY**

Shari Reffi, CVT

HOSPITAL NAME

Blairstown AH

REFERRING VET

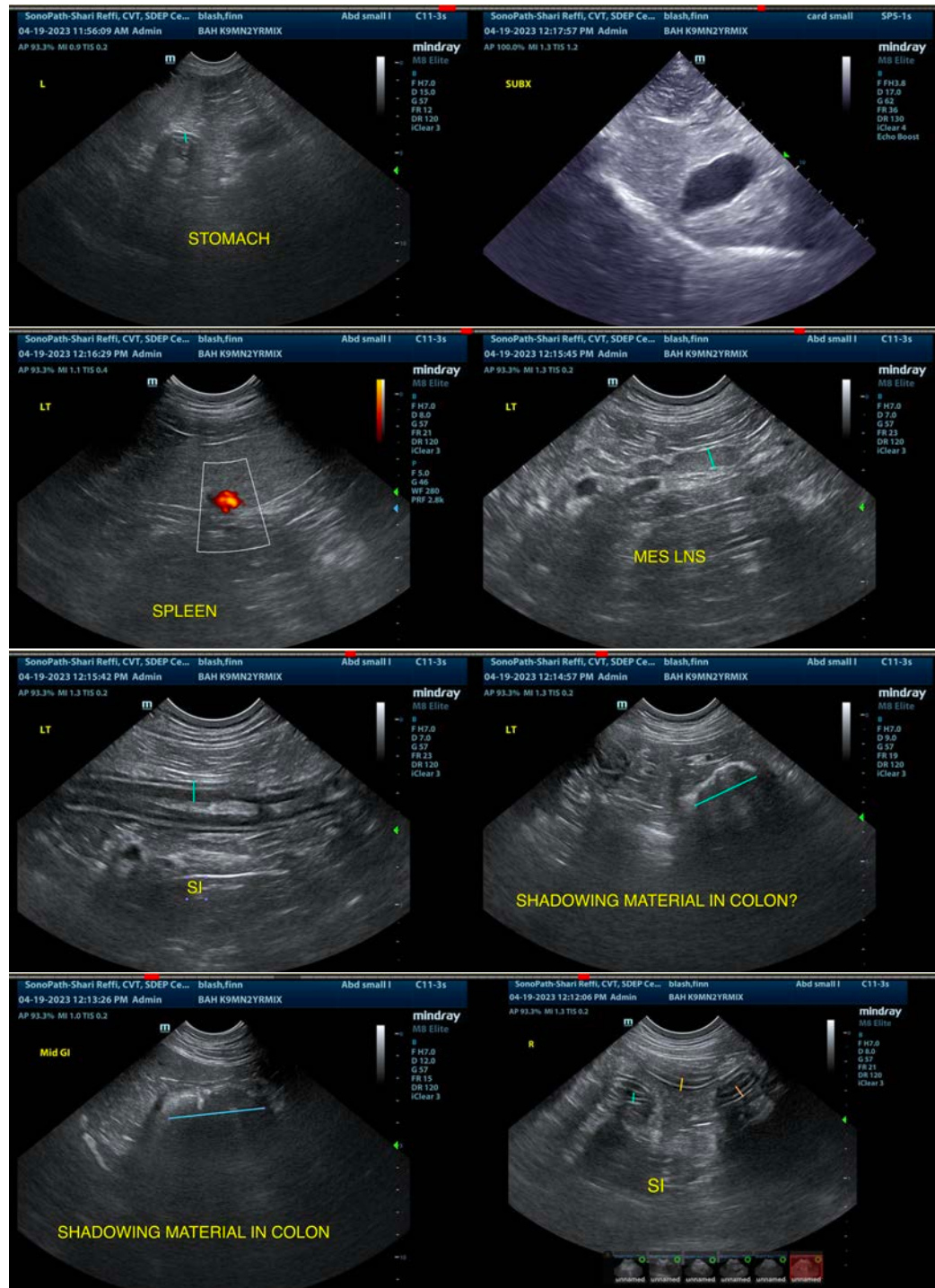
Dr. Summers

INVOICE

46742

DATE

4/19/23





PATIENT

Finn Blash

SPECIES

Canine

BREED

Mix

SEX

Neutered Male

AGE

2 Years 10 Months

WEIGHT

81 Pounds

INTERPRETED BY

Kathleen Sennello DVM,
MS, Diplomate ACVIM
(Small Animal Internal
Medicine)

**IMAGING
PERFORMED BY**

Shari Reffi, CVT

HOSPITAL NAME

Blairstown AH

REFERRING VET

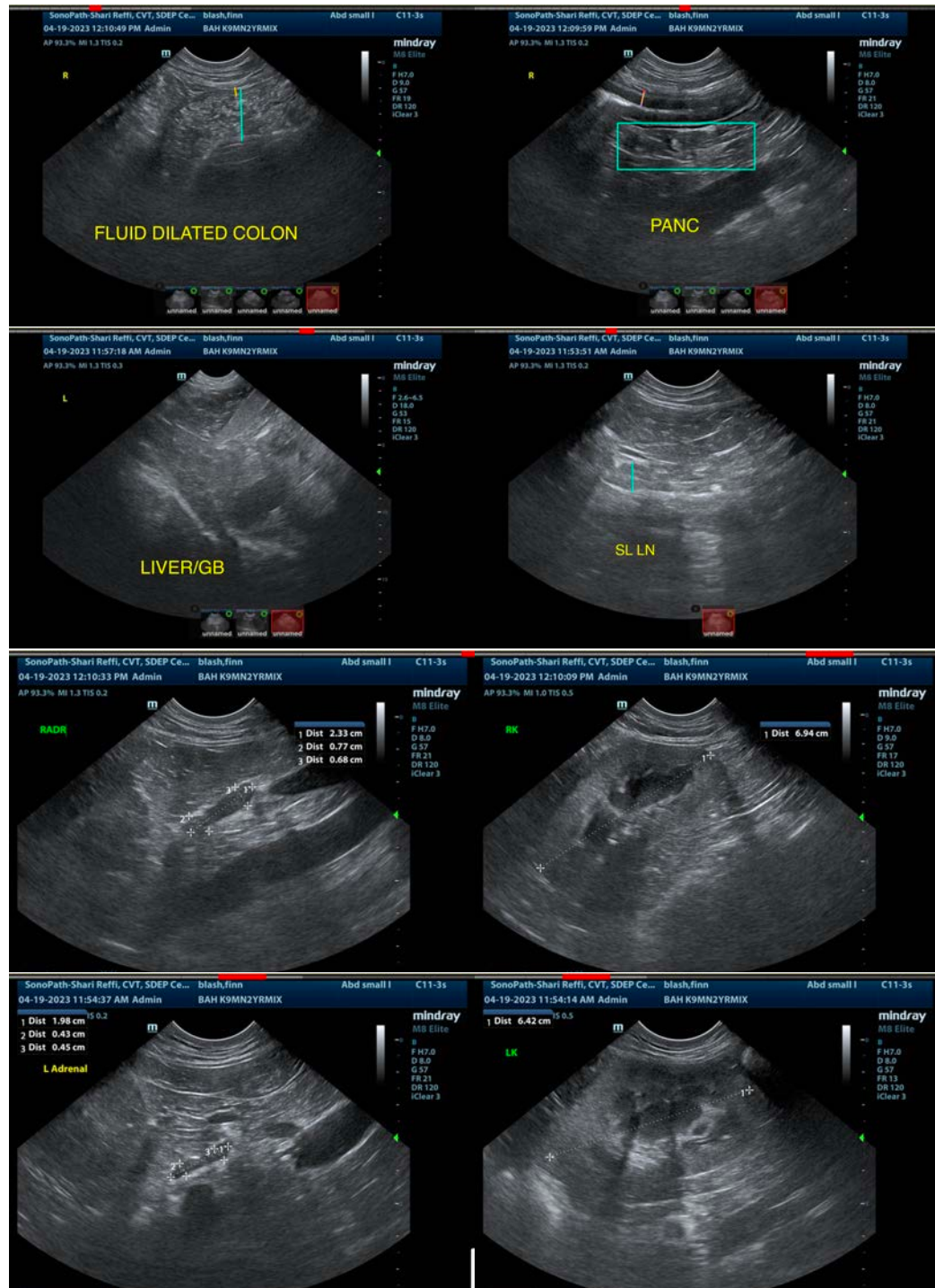
Dr. Summers

INVOICE

46742

DATE

4/19/23





PATIENT

Finn Blash

SPECIES

Canine

BREED

Mix

SEX

Neutered Male

AGE

2 Years 10 Months

WEIGHT

81 Pounds

INTERPRETED BY

Kathleen Sennello DVM,
MS, Diplomate ACVIM
(Small Animal Internal
Medicine)

**IMAGING
PERFORMED BY**

Shari Reffi, CVT

HOSPITAL NAME

Blairstown AH

REFERRING VET

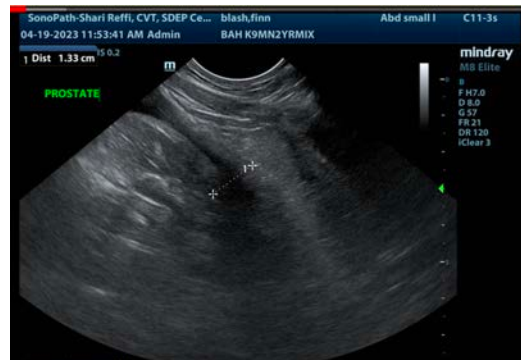
Dr. Summers

INVOICE

46742

DATE

4/19/23



The information and recommendations provided are based on the images presented by the referring veterinarian/sonographer. No evaluation can be communicated regarding pathology that was not visible in the image/video clips provided.

Thank you for this referral. If the clinical or image interpretation does not parallel your findings or if I can be of any further assistance please contact me.

Kathleen Sennello DVM,MS, Diplomate ACVIM (Small animal Internal Medicine)

kathleen.sennello@sonopath.com