

**DATE PRESENTING CLINICAL SIGNS**

4/18/22 Decreased appetite, behavior change (more irritable vs other cats). Another pet in household is having decreased appetite.

**PATIENT**

Clancy Amberger

Current Medications: Gabapentin 100mg 2 hours before appt.  
 Lab Results: 10/2021 NSF (chem, cbc, t4, ua). Current labs pending.  
 Date of Previous IntraPet Ultrasound: No previous.  
 Sedation: Not required to complete full diagnostic ultrasound.  
 Stat Report: Not requested.

**SPECIES**

Feline

**ULTRASONOGRAPHIC EXAMINATION OF THE ABDOMEN****BREED**

DSH

**SEX**

Neutered Male

**AGE**

7/1/05

**WEIGHT**

13.6 Pounds

**INTERPRETED BY**

Kathleen Sennello DVM,  
 MS, Diplomate ACVIM  
 (Small Animal Internal  
 Medicine)

**IMAGING PERFORMED BY**

Stephanie Pearce  
 RDCS, RVT

**HOSPITAL NAME**

Perry Hall AH

**REFERRING VET**

Dr. Hatziannakis

**INVOICE**

36972

**Urinary System**

The urinary bladder is moderately distended with mild primarily suspended echogenic debris present. The Bladder wall, trigone, ureteral papillae and visible urethra (to a depth of 2cm) appear normal with no evidence of wall thickening, mucosal irregularities, masses or calculi. Echogenic debris of this type can be associated with small crystals, cellular debris and proteinaceous debris.

The left kidney has a normal shape and size (4.64 cm). Overall echogenicity is normal with adequate corticomedullary distinction and a typical 1:3 cortex:medulla ratio. There is no evidence of perinephric inflammation or effusion. There is no evidence of pyelectasia, nephroliths, infarcts or hydroureter. Renal vasculature is normal.

The right kidney has a normal shape and size (4.77 cm). Overall echogenicity is normal with adequate corticomedullary distinction and a typical 1:3 cortex:medulla ratio. There is no evidence of perinephric inflammation or effusion. There is no evidence of pyelectasia, nephroliths, infarcts or hydroureter. Renal vasculature is normal.

**Adrenal Glands**

The left adrenal gland is normal in size measuring 0.38 cm at the caudal pole. It is observed in its normal position cranial to the left renal artery. It is normal in appearance (uniformly hypoechoic) and shape with no evidence of a mass effect.

The right adrenal gland is normal in size measuring 0.39 cm at the caudal pole. It is observed in its normal position between the cranial aspect of the right kidney and the caudal vena cava. It is normal in appearance (uniformly hypoechoic) and shape with no evidence of a mass effect.

**Spleen**

The spleen is subjectively normal in size, echotexture is homogenous, and the splenic capsule is smooth with no irregularities. The blood flow through the hilus and splenic parenchyma appears normal. No focal parenchymal abnormalities are visualized.

**Liver**

The liver is subjectively normal in size, and echogenicity with smooth peripheral margins. The parenchyma is homogenous echotexture. The visible portions of the vasculature and biliary tract appear normal. No focal nodules or cystic lesions are observed.

The gallbladder lumen is moderately distended. The wall of the gall bladder is not thickened and has a smooth mucosal surface. Luminal contents are primarily anechoic. The cystic and common bile ducts are normal/not visible.

### ***Gastrointestinal***

The stomach is dilated with mild to moderate fluid and irregular shadowing material most consistent with normal ingesta and gas. It measures at a normal thickness of <0.36cm with some variability due to the presence of rugal folds. The distinction of the gastric wall layering is adequate and there is no impression of reduced peristaltic activity. No masses or focal lesions were observed.

The visualized areas of duodenum, jejunum and ileum have a relatively uniform diameter with minimal fluid distension. Wall thickness is normal. Bowel loops follow a curvilinear path with distinct wall layering maintaining the typical 1:3 muscularis:mucosa layer ratio. Jejunum wall measured 0.21 cm. Visualized peristalsis appears appropriate. There were no focal lesions consistent with obstruction or a mass effect observed.

The ileocecal junction was visualized and exhibited normal intact wall layering and is subjectively of normal thickness. Sections of colon are visualized with formed fecal material and gas shadowing distally. There is no observed focal or generalized colon wall thickening or loss of layering.

### ***Pancreas***

The pancreas is normal and isoechoic to surrounding mesentery. There is no evidence of nodules or cystic lesions. There is no evidence of regional mesenteric inflammation or fluid.

### ***Free Abdomen***

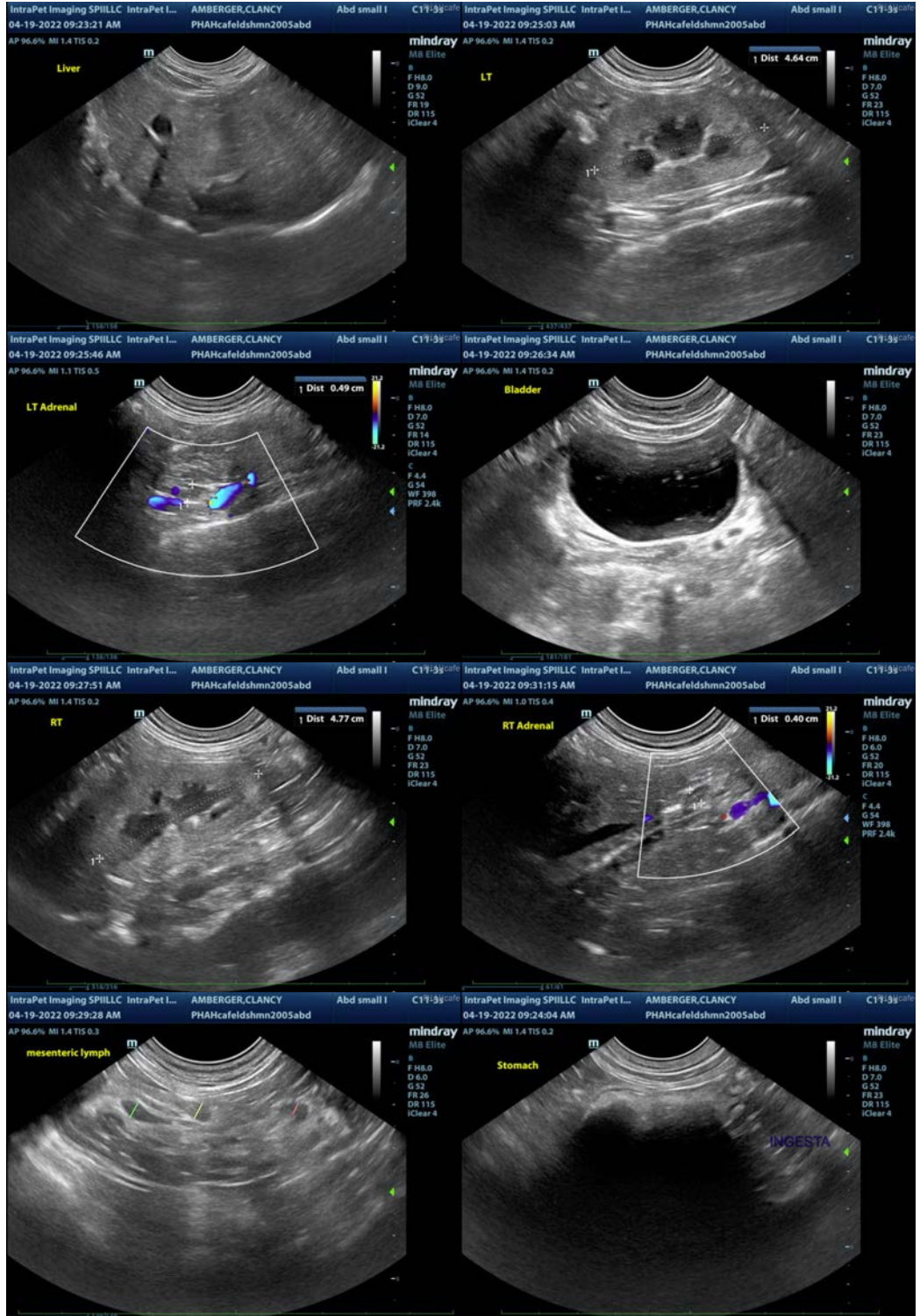
Evaluation of the peritoneal cavity did not reveal any evidence of effusion. There are visible/prominent mesenteric lymph nodes measuring 0.20, 0.39, 0.20 cm. The omentum is of normal echogenicity.

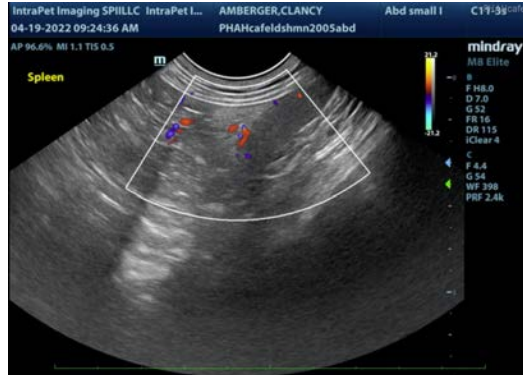## **ULTRASONOGRAPHIC FINDINGS**

- Echogenic debris in the urinary bladder – The echogenic debris in the bladder lumen could be consistent with cells, crystals, and/or mucus.
- Mild/moderate amount of ingesta within the gastric lumen – Correlate with feeding history. If the patient was adequately fasted, this could represent delayed gastric emptying or much less likely a partial outflow tract obstruction.
- Visible/prominent mesenteric lymph nodes – The prominent abdominal lymph nodes are most consistent with reactive lymphadenitis or lymphoid hyperplasia. Neoplastic infiltration is considered less likely.

## **INTERPRETATION OF THE FINDINGS & FURTHER RECOMMENDATIONS**

Today's scan appears relatively normal for an aged cat. Recommend urinalysis and culture to investigate the echogenic debris in the urinary bladder. If GI disease is suspected, you could consider a GI panel to Texas A&M for a qualitative fPLI, TLI, cobalamin and folate to further evaluate the possible delayed gastric emptying and prominent mesenteric lymph nodes.





The information and recommendations provided are based on the images presented by the referring veterinarian/sonographer. No evaluation can be communicated regarding pathology that was not visible in the image/video clips provided.

Thank you for this referral. If the clinical or image interpretation does not parallel your findings or if I can be of any further assistance please contact me.

Kathleen Sennello DVM,MS, Diplomate ACVIM (Small animal Internal Medicine)  
kathleen.sennello@sonopath.com