

**DATE PRESENTING CLINICAL SIGNS**

4/19/22 Patient presents for evaluation of increased urinations and licking vulva. PE is overall unremarkable.

PATIENT

Bandita Hagerty

Current Medications: None.
 Lab Results: Azotemia noted- Iris stage 3.
 Date of Previous IntraPet Ultrasound: No previous.
 Sedation: Not required to complete full diagnostic ultrasound.
 Stat Report: Not requested.

SPECIES

Feline

ULTRASONOGRAPHIC EXAMINATION OF THE ABDOMEN**BREED**

DMH

Urinary System

The urinary bladder is moderately distended with anechoic urine. The Bladder wall, trigone, ureteral papillae and visible urethra (to a depth of 2cm) appear normal with no evidence of wall thickening, mucosal irregularities, masses or cystic calculi.

SEX

Spayed Female

The left kidney is small and irregular shape, measuring 2.34 cm. Pyelectasia is present at 0.25 cm and evidence of previous infarcts. Overall echogenicity is slightly hyperechoic with poor corticomedullary distinction and a typical 1:3 cortex:medulla ratio. There is no evidence of perinephric inflammation or effusion. There is no evidence of nephroliths or hydroureter. Renal vasculature is normal.

AGE

10/14/07

The right kidney has a normal shape and size (3.15 cm). Overall echogenicity is slightly hyperechoic with poor corticomedullary distinction and a typical 1:3 cortex:medulla ratio. There is no evidence of perinephric inflammation or effusion. There is no evidence of pyelectasia, nephroliths, infarcts or hydroureter. Renal vasculature is normal.

WEIGHT

7 Pounds

INTERPRETED BY

Kathleen Sennello DVM,
 MS, Diplomate ACVIM
 (Small Animal Internal
 Medicine)

Adrenal Glands

The left adrenal gland is normal in size measuring 0.37 cm at the caudal pole. It is observed in its normal position cranial to the left renal artery. It is normal in appearance (uniformly hypoechoic) and shape with no evidence of a mass effect.

The right adrenal gland is normal in size measuring 0.35 cm at the caudal pole. It is observed in its normal position between the cranial aspect of the right kidney and the caudal vena cava. It is normal in appearance (uniformly hypoechoic) and shape with no evidence of a mass effect.

IMAGING PERFORMED BY

Stephanie Pearce
 RDCS, RVT

Spleen

The spleen is subjectively normal in size, echotexture is homogenous, and the splenic capsule is smooth with no irregularities. The blood flow through the hilus and splenic parenchyma appears normal. No focal parenchymal abnormalities are visualized.

HOSPITAL NAME

Perry Hall AH

Liver

The liver is subjectively normal in size, and echogenicity with smooth peripheral margins. The parenchyma is homogenous echotexture. The visible portions of the vasculature and biliary tract appear normal. No focal nodules or cystic lesions are observed.

REFERRING VET

Dr. Miller

The gallbladder lumen is moderately distended. The wall of the gall bladder is not thickened and has a smooth mucosal surface. Luminal contents are primarily anechoic. The cystic and common bile ducts are normal/not visible.

INVOICE

36971

Gastrointestinal

The stomach contains minimal luminal contents. It measures at a normal thickness of <0.36cm with some variability due to the presence of rugal folds. The distinction of the gastric wall layers is adequate and there is no impression of reduced peristaltic activity. No masses or focal lesions were observed.

The visualized areas of duodenum, jejunum and ileum have a relatively uniform diameter with minimal fluid distension. Wall thickness is normal. Bowel loops follow a curvilinear path with distinct wall layering maintaining the typical 1:3 muscularis:mucosa layer ratio. Jejunum wall measured 0.21 cm. Visualized peristalsis appears appropriate. There were no focal lesions consistent with obstruction or a mass effect observed.

The ileocecal junction was visualized and exhibited normal intact wall layering and is subjectively of normal thickness. Sections of colon are visualized with formed fecal material and gas shadowing distally. There is no observed focal or generalized colon wall thickening or loss of layering.

Pancreas

The pancreas is normal and isoechoic to surrounding mesentery. There is no evidence of nodules or cystic lesions. There is no evidence of regional mesenteric inflammation or fluid.

Free Abdomen

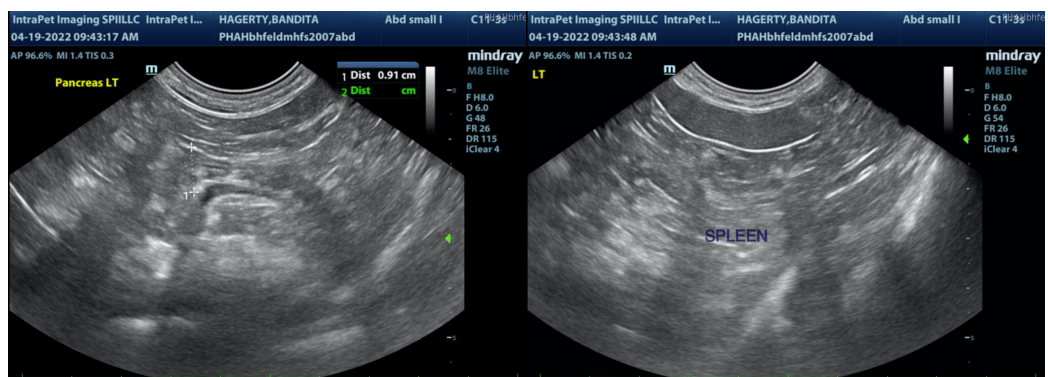
Evaluation of the peritoneal cavity did not reveal any evidence of effusion, or subjective lymphadenomegaly. The Medial iliac nodes appear normal and there was no evidence of a caudal aortic thrombus at the bifurcation. The omentum is of normal uniform echogenicity.

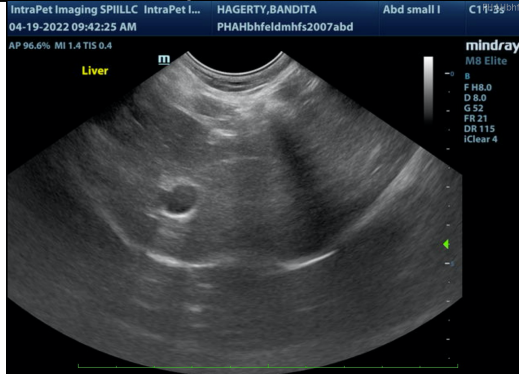
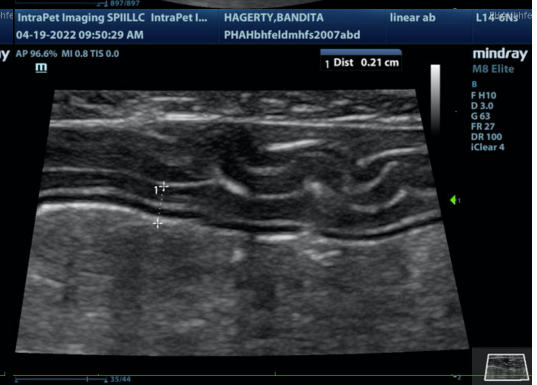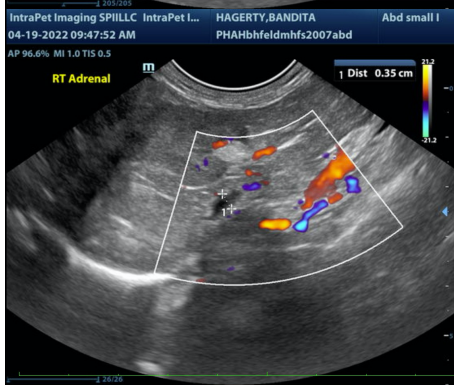
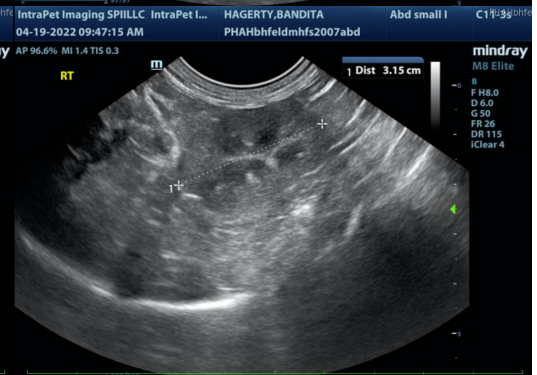
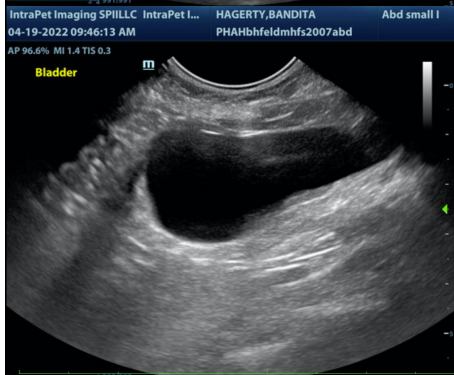
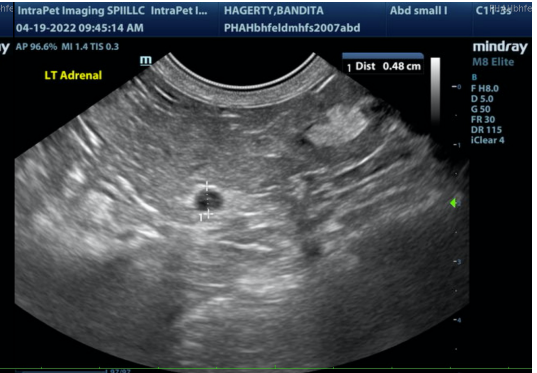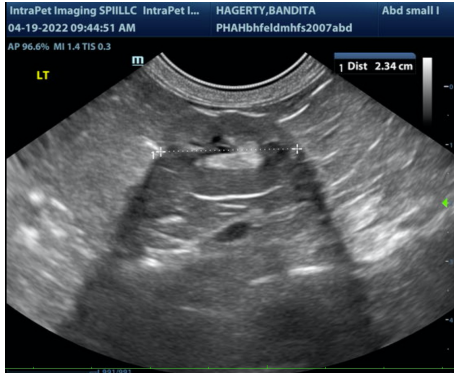ULTRASONOGRAPHIC FINDINGS

- Decreased corticomedullary distinction in both kidneys, small left kidney with pyelectasia and previous infarcts – Mild loss of corticomedullary distinction in both kidneys could be consistent with chronic degenerative disease or interstitial nephrosis. The mild pyelectasia seen on the left side could be consistent with PU/PD, fluid therapy, pyelonephritis, or a unilateral obstruction (none observed).

INTERPRETATION OF THE FINDINGS & FURTHER RECOMMENDATIONS

Today's scan appears relatively normal aside from the changes observed in the kidneys. These changes are most consistent with previous renal injury and chronic progressive renal disease. There is mild pyelectasia, and the left kidney appears somewhat small. Recommend urinalysis and culture, blood pressure evaluation +/- urine protein/creatinine ratio.





The information and recommendations provided are based on the images presented by the referring veterinarian/sonographer. No evaluation can be communicated regarding pathology that was not visible in the image/video clips provided.

Thank you for this referral. If the clinical or image interpretation does not parallel your findings or if I can be of any further assistance please contact me.

Kathleen Sennello DVM,MS, Diplomate ACVIM (Small animal Internal Medicine)
kathleen.sennello@sonopath.com