

**DATE PRESENTING CLINICAL SIGNS**

4/18/23 Increase in respiratory effort, increase in respiratory rate, seems uncomfortable at night.

PATIENT

Brewer Blake

Current Medications: Carprofen 25mg ½ BID 4/5-4/10.
 Lab Results: 3/22/23 PCV 26%. 3/28/23 PCV 29%. 4/5/23 PCV 32%. 4/17/23 PCV 28%. Attached.
 Date of Previous IntraPet Ultrasound: No previous.
 Sedation: Not required to complete full diagnostic ultrasound.
 Stat Report: Not requested.
 Imaging Performed By: Rachel Brillhart, RDMS.

SPECIES

Canine

ULTRASONOGRAPHIC EXAMINATION OF THE ABDOMEN**BREED**

Goldendoodle

Urinary System

The urinary bladder is moderately distended with anechoic urine. The Bladder wall, trigone, ureteral papillae and visible urethra (to a depth of 2cm) appear normal with no evidence of wall thickening, mucosal irregularities, masses or cystic calculi.

SEX

Intact Male

The prostate is large in size (0.91 cm) but has a regular shape with smooth external margins. The parenchyma is heterogenous but no discrete focal lesions are present. The prostatic urethra appears normal with no evidence of irregularity, invasion, mass effect or calculi.

AGE

1/2/23

The left kidney has a normal shape and size (5.91 cm). Overall echogenicity is normal with adequate corticomedullary distinction and a typical 1:3 cortex:medulla ratio. There is no evidence of focal perinephric inflammation or effusion. There is no evidence of pyelectasia, nephroliths, infarcts or hydroureter. Renal vasculature is normal.

WEIGHT

20 Pounds

The right kidney has a normal shape and size (6.36 cm). Overall echogenicity is normal with adequate corticomedullary distinction and a typical 1:3 cortex:medulla ratio. There is no evidence of focal perinephric inflammation or effusion. There is no evidence of pyelectasia, nephroliths, infarcts or hydroureter. Renal vasculature is normal.

INTERPRETED BY

Kathleen Sennello DVM,
 MS, Diplomate ACVIM
 (Small Animal Internal
 Medicine)

Adrenal Glands

The left adrenal gland is normal in size measuring 0.49 cm at the caudal pole. It is observed in its normal position cranial to the left renal artery. It is normal in appearance (uniformly hypoechoic) and shape with no evidence of a mass effect.

HOSPITAL NAME

Bel Air Vet Hospital

The right adrenal gland is normal in size measuring 0.55 cm at the caudal pole. It is observed in its normal position between the cranial aspect of the right kidney and the caudal vena cava. It is normal in appearance (uniformly hypoechoic) and shape with no evidence of a mass effect.

REFERRING VET

Dr. Schmidt

Spleen

The spleen is subjectively normal in size, echotexture is homogenous, and the splenic capsule is smooth with no irregularities. The blood flow through the hilus and splenic parenchyma appears normal. No focal parenchymal abnormalities are visualized.

INVOICE

46714

Liver

The liver is subjectively normal in size, and echogenicity with smooth peripheral margins. The parenchyma is homogenous echotexture. The visible portions of the vasculature and biliary tract appear normal. No focal nodules or cystic lesions are observed.

The gallbladder lumen is moderately distended. The wall of the gall bladder is not thickened and has a smooth mucosal surface. Luminal contents are mild and primarily anechoic. The cystic and common bile ducts are normal/not visible.

Gastrointestinal

The stomach contains minimal luminal contents. In many regions it measures at a normal thickness of <0.7cm with some variability due to the presence of rugal folds. In other areas, the gastric wall appears more prominent with intact layering, measuring up to 1.2 cm. There is no impression of reduced peristaltic activity. No focal mass lesions were observed.

The visualized areas of duodenum, jejunum and ileum have a relatively uniform diameter with minimal fluid distension. Wall thickness is normal. Bowel loops follow a curvilinear path with distinct wall layering maintaining the typical 1:3 muscularis:mucosa layer ratio. Duodenum wall measures 0.42 cm. Jejunum wall measures 0.32 cm. Visualized peristalsis appears appropriate. The ileum appears somewhat prominent and thickened with intact wall layering, measuring at 0.42 cm.

The ileocecal junction was visualized and exhibited normal intact wall layering and is subjectively of normal thickness. Sections of colon are visualized with formed fecal material and gas shadowing distally. There is no observed focal or generalized colon wall thickening or loss of layering.

Pancreas

The pancreas is prominent and mildly mottled compared to the surrounding isoechoic mesentery. There is no evidence of nodules or cystic lesions. There is no evidence of regional mesenteric inflammation or fluid.

Free Abdomen

Evaluation of the peritoneal cavity did not reveal any evidence of effusion. There are prominent mesenteric lymph nodes visualized. Examples measure 0.74 cm and 0.65 cm. Additionally, the sublumbar lymph nodes are visible at the iliac bifurcation measuring 0.62 cm and 0.53 cm in width. The omentum is generally of normal echogenicity.

Other

Both testicles are visualized and appear within normal limits.

ULTRASONOGRAPHIC FINDINGS

- Prominent, mottled pancreas – The pancreatic changes are most consistent with age-related parenchymal remodeling, potentially secondary to a prior inflammatory episode, early fibrosis or chronic pancreatitis.
- Prominent gastric wall – Gastric wall layering appears intact and no distinct focal lesions are visualized. Consider such differentials as gastritis, imaging artifact, edema, much less likely infiltrative disease.
- Mildly prominent/thickened ileum – The mild small intestinal wall changes may be a normal variant in this patient or could be consistent with an inflammatory process (e.g., inflammatory bowel disease).
- Mild mesenteric lymphadenopathy – The prominent abdominal lymph nodes are most consistent with reactive lymphadenitis or lymphoid hyperplasia. Neoplastic infiltration is considered less likely. This can be a normal finding in puppies.

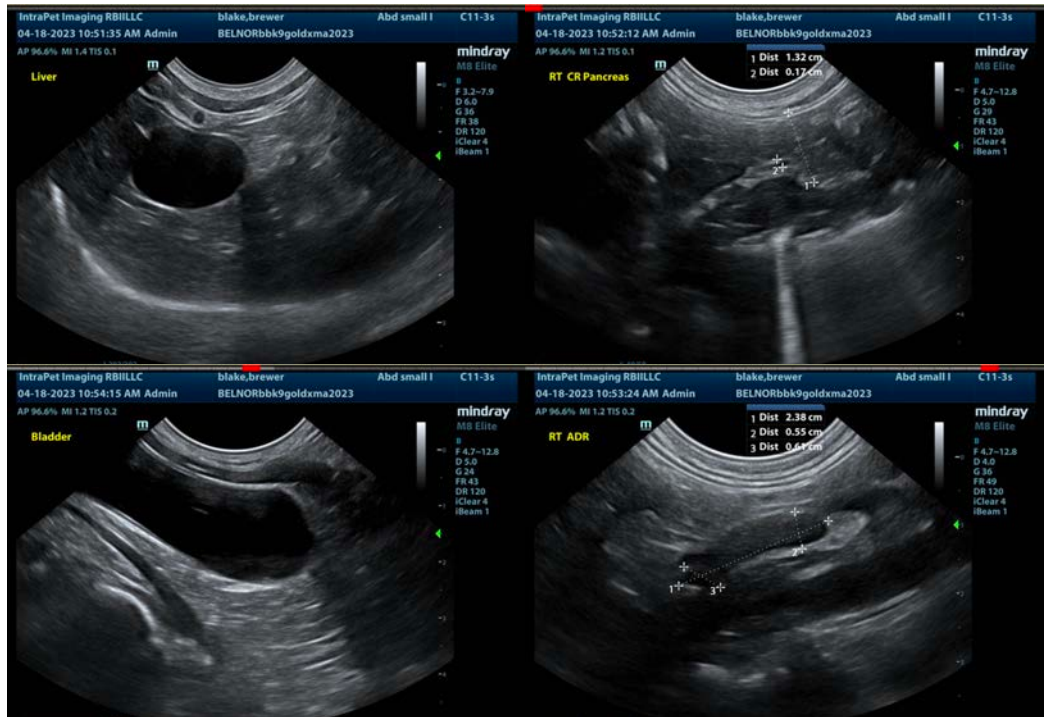
INTERPRETATION OF THE FINDINGS & FURTHER RECOMMENDATIONS

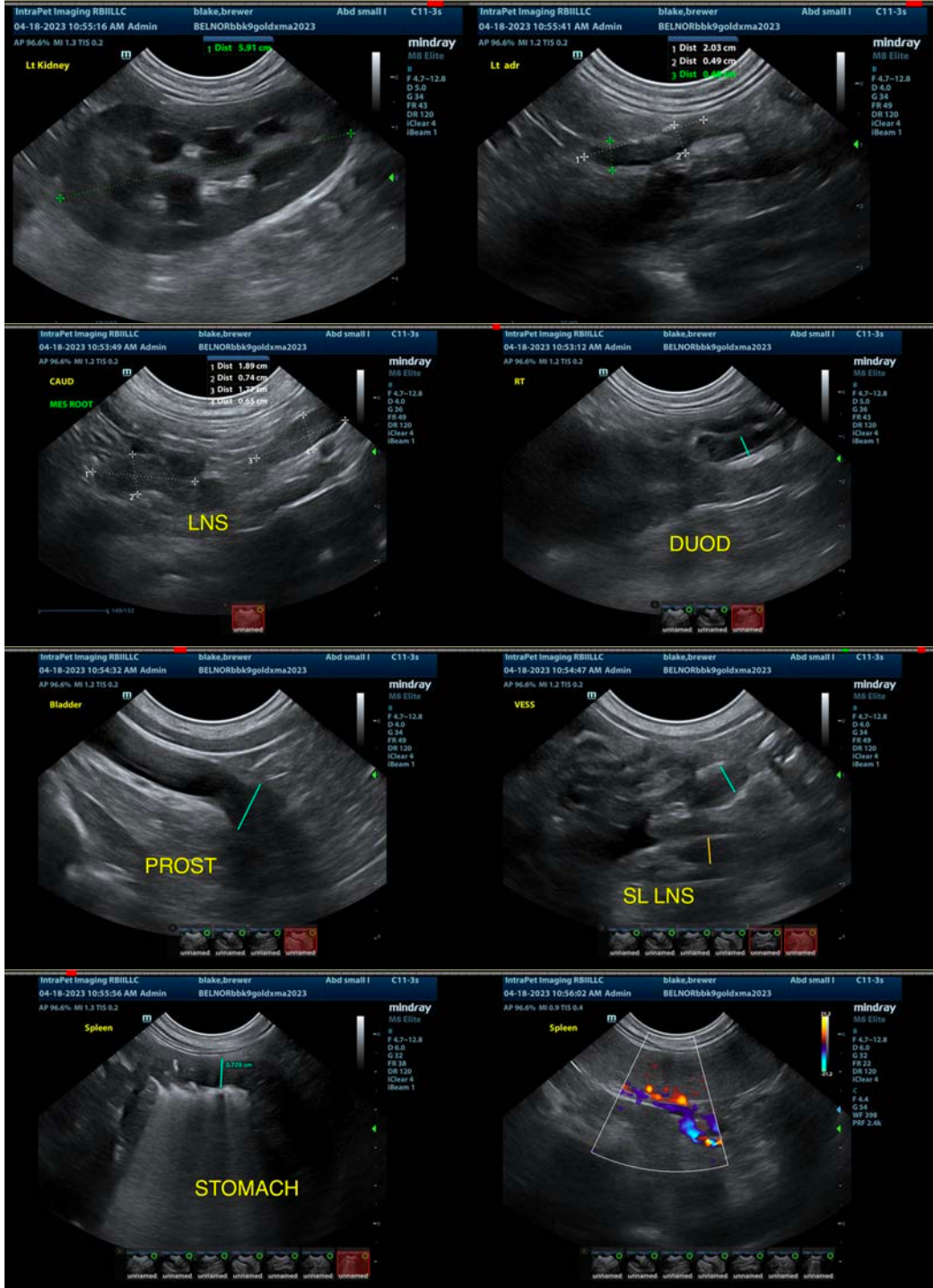
No prominent focal lesions are visualized on today's exam to explain the anemia reported. In some views of the gastric wall, it appears somewhat thickened, but there is apparent rugal folding and the stomach is fairly empty, making true assessment of the gastric wall thickness challenging. I suspect this is largely imaging artifact, but gastritis or infiltrative disease are possible. If there are concerns about underlying gastric disease, you could consider an upper GI endoscopy. I suspect the changes described in the pancreas are incidental, and the significance of the prominent/mildly thickened ileum is uncertain, as wall layering is intact.

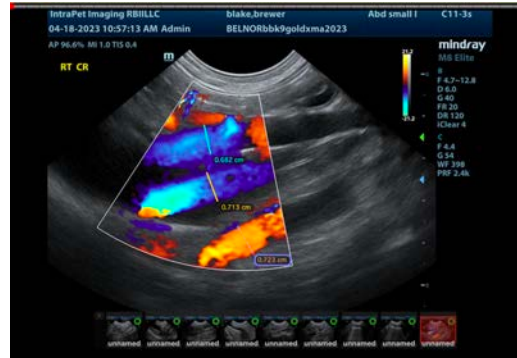
The lymphadenopathy is likely within normal limits for a puppy.

Pediatric patients often have slightly lower packed cell volumes than adults, although I suspect this is still lower than usual. Consider a pathologist review of a blood smear, a rectal exam looking for evidence of melena, and empirical deworming. The symptoms of panting, etc. are interesting, as I would not suspect that as a symptom with this mild degree of anemia. Consider the possibility of cardiopulmonary disease. Recommend 3-view thoracic radiographs.

Although unlikely based on today's imaging, you could consider screening for Addison's disease and pre- and post-prandial bile acids to look for evidence of a portosystemic shunt.







The information and recommendations provided are based on the images presented by the referring veterinarian/sonographer. No evaluation can be communicated regarding pathology that was not visible in the image/video clips provided.

Thank you for this referral. If the clinical or image interpretation does not parallel your findings or if I can be of any further assistance please contact me.

Kathleen Sennello DVM,MS, Diplomate ACVIM (Small animal Internal Medicine)
kathleen.sennello@sonopath.com