



PATIENT

Beloved Vega-Olds

SPECIES

Canine

BREED

Poodle X

SEX

Spayed Female

AGE

8 Years

WEIGHT

20 Pounds

INTERPRETED BY

Kathleen Sennello DVM,
MS, Diplomate ACVIM
(Small Animal Internal
Medicine)

IMAGING PERFORMED BY

Dr. Petrone

HOSPITAL NAME

Long Branch AH

REFERRING VET

Dr. Griffin

INVOICE

46711

DATE

4/18/23

PRESENTING CLINICAL SIGNS

Chronic waxing/waning. GI signs (v+/d+/anorexia). Usually responds to supportive care (i/d, metro, cerenia, etc.)

ULTRASONOGRAPHIC EXAMINATION OF THE ABDOMEN

Urinary System

The urinary bladder is moderately distended with anechoic urine. The Bladder wall, trigone, ureteral papillae and visible urethra (to a depth of 2cm) appear normal with no evidence of wall thickening, mucosal irregularities, masses or cystic calculi.

The left kidney has a normal shape and size (4.91 cm). Overall echogenicity is normal with adequate corticomedullary distinction and a typical 1:3 cortex:medulla ratio. There is no evidence of focal perinephric inflammation or effusion. There is no evidence of pyelectasia, nephroliths, infarcts or hydroureter. Renal vasculature is normal.

The right kidney has a normal shape and size (5.48 cm). Overall echogenicity is normal with adequate corticomedullary distinction and a typical 1:3 cortex:medulla ratio. There is no evidence of focal perinephric inflammation or effusion. There is no evidence of pyelectasia, nephroliths, infarcts or hydroureter. Renal vasculature is normal.

Adrenal Glands

The left adrenal gland is normal in size measuring 0.45 cm at the caudal pole. It is observed in its normal position cranial to the left renal artery. It is normal in appearance (uniformly hypoechoic) and shape with no evidence of a mass effect.

The right adrenal gland is normal in size measuring 0.44 cm at the caudal pole. It is observed in its normal position between the cranial aspect of the right kidney and the caudal vena cava. It is normal in appearance (uniformly hypoechoic) and shape with no evidence of a mass effect.

Spleen

The spleen is subjectively normal in size, echotexture is homogenous, and the splenic capsule is smooth with no irregularities. The blood flow through the hilus and splenic parenchyma appears normal. No focal parenchymal abnormalities are visualized.

Liver

The liver is subjectively normal in size, and echogenicity with smooth peripheral margins. The parenchyma is homogenous echotexture. The visible portions of the vasculature and biliary tract appear normal. No focal nodules or cystic lesions are observed.

The gall bladder lumen is moderately distended. The wall of the gall bladder is not thickened and has a smooth mucosal surface. There is a moderate amount of non-organized echogenic debris. The cystic and common bile ducts are normal/not visible.

Gastrointestinal

The stomach contains minimal luminal contents. It measures at a normal thickness of <0.7cm with some variability due to the presence of rugal folds. The distinction of the gastric wall layers is adequate and there is no impression of reduced peristaltic activity. No masses or focal lesions were observed.



PATIENT

Beloved Vega-Olds

SPECIES

Canine

BREED

Poodle X

SEX

Spayed Female

AGE

8 Years

WEIGHT

20 Pounds

INTERPRETED BY

Kathleen Sennello DVM,
MS, Diplomate ACVIM
(Small Animal Internal
Medicine)

IMAGING PERFORMED BY

Dr. Petrone

HOSPITAL NAME

Long Branch AH

REFERRING VET

Dr. Griffin

INVOICE

46711

DATE

4/18/23

The visualized areas of duodenum, jejunum and ileum have a relatively uniform diameter with minimal fluid distension. Wall thickness is normal. Bowel loops follow a curvilinear path with distinct wall layering maintaining the typical 1:3 muscularis:mucosa layer ratio. Duodenum wall measures 0.49 cm. Jejunum wall measures 0.33 cm. Visualized peristalsis appears appropriate. There were no focal lesions consistent with obstruction or a mass effect observed.

The ileocecal junction was visualized and exhibited normal intact wall layering and is subjectively of normal thickness. Sections of colon are visualized with formed fecal material and gas shadowing distally. There is no observed focal or generalized colon wall thickening or loss of layering.

Pancreas

The pancreas is normal and isoechoic to surrounding mesentery. There is no evidence of nodules or cystic lesions. There is no evidence of regional mesenteric inflammation or fluid.

Free Abdomen

Evaluation of the peritoneal cavity did not reveal any evidence of effusion, or subjective lymphadenomegaly. The Medial iliac nodes appear normal and there was no evidence of a caudal aortic thrombus at the bifurcation. The omentum is of normal uniform echogenicity.

ULTRASONOGRAPHIC FINDINGS

- Mild gallbladder debris – The significance of the aggregated gallbladder debris is unclear. This could represent an early mucocele, cholestasis, or may be secondary to fasting but seems unlikely to be causing a current issue. Recommend continued monitoring.

INTERPRETATION OF THE FINDINGS & FURTHER RECOMMENDATIONS

Today's scan is relatively normal with no significant lesions visualized associated with the gastrointestinal tract to explain the intermittent GI signs reported. Intermittent GI disease can be frustrating, as it is difficult to assess therapies due to the intermittent nature. I often recommend owners take notes over time to try to see if there is a pattern or any association with these episodes and feeding habits, times of stress, etc.

Consider such differentials as food allergy/dietary intolerance, GI parasitism, pancreatitis, dysbiosis, recurrent dietary indiscretion, IBD and less likely neoplasia, etc....

- Consider a novel protein/hydrolyzed protein diet (exclusively at least 4-6 weeks)
- Recommend screening for Addison's disease.
- Consider a GI panel to Texas A&M for evaluation of B12 levels, folate, PLI/TLI etc.. to further evaluate for pancreatic/small intestinal disease.
- Recommend chronic probiotic therapy.

If symptoms are persisting or getting worse, there is no response to the above suggestions, and primary gastrointestinal disease is strongly suspected (bloodwork is normal) then consider obtaining GI biopsies.



PATIENT

Beloved Vega-Olds

SPECIES

Canine

BREED

Poodle X

SEX

Spayed Female

AGE

8 Years

WEIGHT

20 Pounds

INTERPRETED BY

Kathleen Sennello DVM,
MS, Diplomate ACVIM
(Small Animal Internal
Medicine)

IMAGING PERFORMED BY

Dr. Petrone

HOSPITAL NAME

Long Branch AH

REFERRING VET

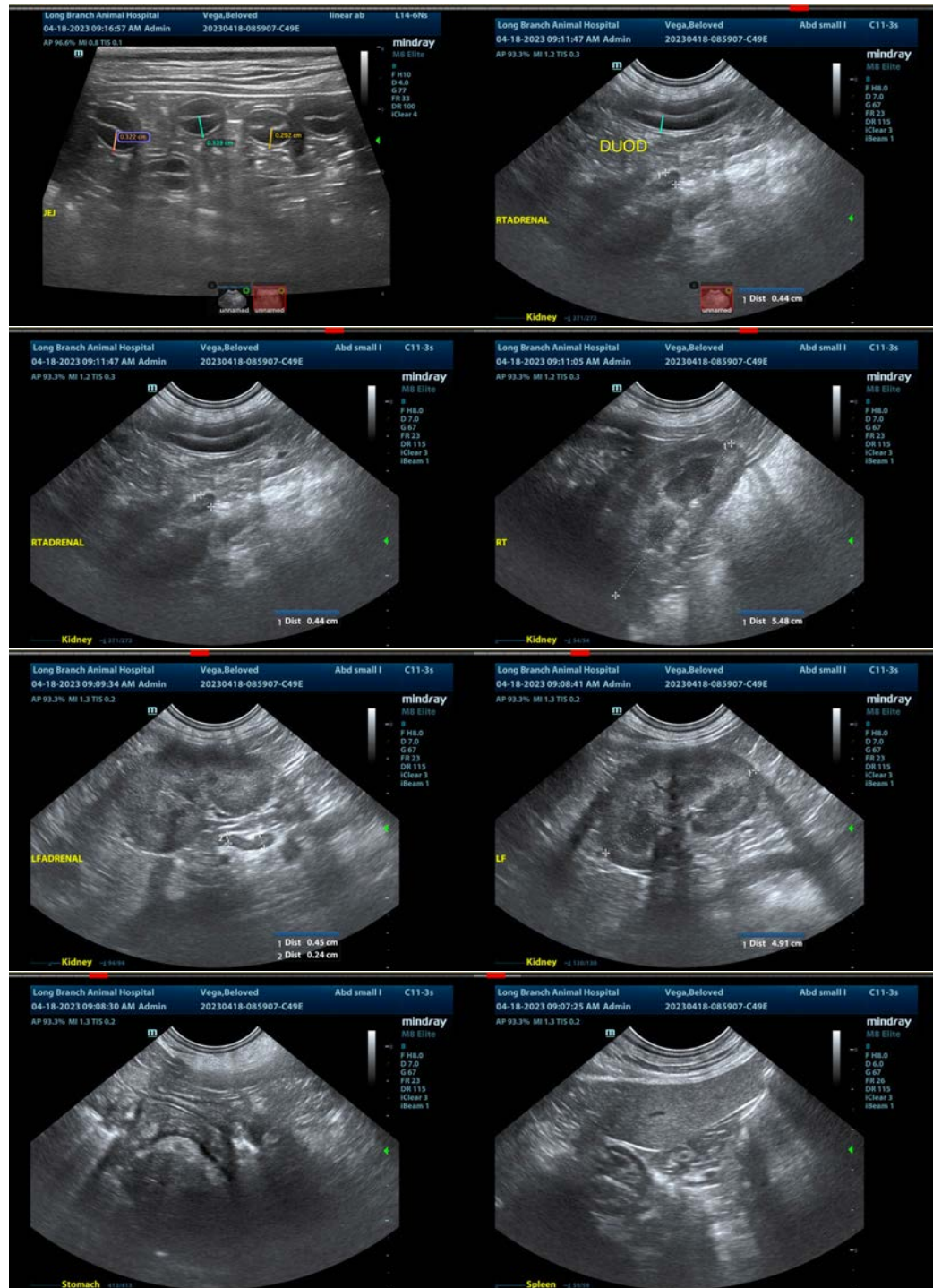
Dr. Griffin

INVOICE

46711

DATE

4/18/23





PATIENT

Beloved Vega-Olds

SPECIES

Canine

BREED

Poodle X

SEX

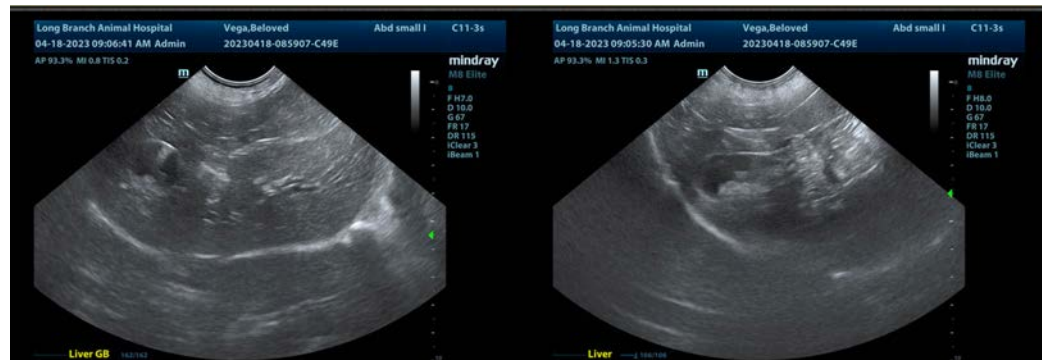
Spayed Female

AGE

8 Years

WEIGHT

20 Pounds



The information and recommendations provided are based on the images presented by the referring veterinarian/sonographer. No evaluation can be communicated regarding pathology that was not visible in the image/video clips provided.

Thank you for this referral. If the clinical or image interpretation does not parallel your findings or if I can be of any further assistance please contact me.

Kathleen Sennello DVM,MS, Diplomate ACVIM (Small animal Internal Medicine)

kathleen.sennello@sonopath.com

INTERPRETED BY

Kathleen Sennello DVM,
MS, Diplomate ACVIM
(Small Animal Internal
Medicine)

IMAGING PERFORMED BY

Dr. Petrone

HOSPITAL NAME

Long Branch AH

REFERRING VET

Dr. Griffin

INVOICE

46711

DATE

4/18/23