



PATIENT

Mags Brandt

SPECIES

Feline

BREED

DSH

SEX

Spayed Female

AGE

11 Years

WEIGHT

4.55 kg

INTERPRETED BY

Kathleen Sennello DVM,
 MS, Diplomate ACVIM
 (Small Animal Internal
 Medicine)

IMAGING PERFORMED BY

Crystal Hill

HOSPITAL NAME

Novel Vet

REFERRING VET

Dr. Gibbs

INVOICE

74509

DATE

4/16/26

PRESENTING CLINICAL SIGNS

Recheck ultrasound done elsewhere in 2023 - diagnosed with chronic enteropathy. Has been on Gabapentin BID and Prednisolone. Abdominal tenseness/pain?

Abnormal PE/Chem/CBC/UA Results: Lab results pending. Previous US revealed - chronic enteropathy (intestinal lymphoma vs inflammatory bowel disease), ongoing, currently managed with prednisolone. Nephropathy revealed.

ULTRASONOGRAPHIC EXAMINATION OF THE ABDOMEN

Urinary System

The urinary bladder is moderately distended with anechoic urine. The Bladder wall, trigone, ureteral papillae and visible urethra (to a depth of 2cm) appear normal with no evidence of wall thickening, mucosal irregularities, masses or cystic calculi.

The left kidney has a normal shape and size (3.67 cm). Overall echogenicity is slightly hyperechoic with mildly reduced corticomedullary distinction and a typical 1:3 cortex:medulla ratio. There is no evidence of focal perinephric inflammation or effusion. There is no evidence of pyelectasia, nephroliths, infarcts or hydroureter. Renal vasculature is normal.

The right kidney has a normal shape and size (3.63 cm). Overall echogenicity is slightly hyperechoic with mildly reduced corticomedullary distinction and a typical 1:3 cortex:medulla ratio. There is no evidence of focal perinephric inflammation or effusion. There is no evidence of pyelectasia, nephroliths, infarcts or hydroureter. Renal vasculature is normal.

Adrenal Glands

The left adrenal gland is normal in size measuring 0.34 cm at the caudal pole. It is observed in its normal position cranial to the left renal artery. It is normal in appearance (uniformly hypoechoic) and shape with no evidence of a mass effect.

The right adrenal gland is normal in size measuring 0.35 cm at the caudal pole. It is observed in its normal position between the cranial aspect of the right kidney and the caudal vena cava. It is normal in appearance (uniformly hypoechoic) and shape with no evidence of a mass effect.

Spleen

The spleen is subjectively normal in size (0.77 cm), echotexture is homogenous, and the splenic capsule is smooth with no irregularities. The blood flow through the hilus and splenic parenchyma appears normal. No focal parenchymal abnormalities are visualized.

Liver

The liver is subjectively normal in size, and echogenicity with smooth peripheral margins. The parenchyma is homogenous echotexture. The visible portions of the vasculature and biliary tract appear normal. No focal nodules or cystic lesions are observed.

The gall bladder lumen is moderately distended. The wall of the gall bladder is not thickened and has a smooth mucosal surface. Luminal contents are mild and likely incidental at this time. The cystic and common bile ducts are normal/not visible.



PATIENT

Mags Brandt

SPECIES

Feline

BREED

DSH

SEX

Spayed Female

AGE

11 Years

WEIGHT

4.55 kg

INTERPRETED BY

Kathleen Sennello DVM,
 MS, Diplomate ACVIM
 (Small Animal Internal
 Medicine)

IMAGING PERFORMED BY

Crystal Hill

HOSPITAL NAME

Novel Vet

REFERRING VET

Dr. Gibbs

INVOICE

74509

DATE

4/16/26

Gastrointestinal

The stomach contains mild fluid and gas. It measures at a normal thickness of <0.36cm with some variability due to the presence of rugal folds. The distinction of the gastric wall layers is adequate and there is no impression of reduced peristaltic activity. No masses or focal lesions were observed.

The visualized areas of duodenum, jejunum and ileum have a uniform diameter with minimal fluid distension. Wall thickness is normal to slightly increased. Bowel loops follow a typical curvilinear path with distinct wall layering, but some areas display a prominent muscularis layer which does not display the typical 1:3 muscularis:mucosa layer ratio. Duodenum wall measures 0.27 cm. Jejunum wall measures 0.29 cm. Visualized peristalsis appears appropriate. There were no focal lesions consistent with obstruction or a mass effect observed.

Sections of colon are visualized with formed fecal material and gas shadowing distally. There is no observed focal or generalized colon wall thickening or loss of layering.

Pancreas

The area of the pancreas is normal and isoechoic to surrounding mesentery. There is no evidence of nodules or cystic lesions. There is no evidence of regional mesenteric inflammation or fluid.

Free Abdomen

Evaluation of the peritoneal cavity did not reveal any evidence of effusion, or subjective lymphadenomegaly. The Medial iliac nodes appear normal and there was no evidence of a caudal aortic thrombus at the bifurcation. The omentum is of normal uniform echogenicity.

ULTRASONOGRAPHIC FINDINGS

- Mild age related changes visualized associated with both kidneys.
- Mildly “ropey” appearing small intestine with some areas exhibiting prominent muscularis layer – The mild small intestinal wall changes may be a normal variant in this patient or could be consistent with an inflammatory process (e.g., inflammatory bowel disease).

INTERPRETATION OF THE FINDINGS & FURTHER RECOMMENDATIONS

The changes observed on today’s scan are mild. No focal lesions are visualized associated with the GI tract, although a subtle gastric lesion cannot be ruled out, as intraluminal gas can interfere with full evaluation. Additionally, current steroid can mask the appearance of inflammation, etc. Correlate today’s findings with clinical assessment. If symptoms are persistent, further evaluation may be warranted.



PATIENT

Mags Brandt

SPECIES

Feline

BREED

DSH

SEX

Spayed Female

AGE

11 Years

WEIGHT

4.55 kg

INTERPRETED BY

Kathleen Sennello DVM,
 MS, Diplomate ACVIM
 (Small Animal Internal
 Medicine)

**IMAGING
 PERFORMED BY**

Crystal Hill

HOSPITAL NAME

Novel Vet

REFERRING VET

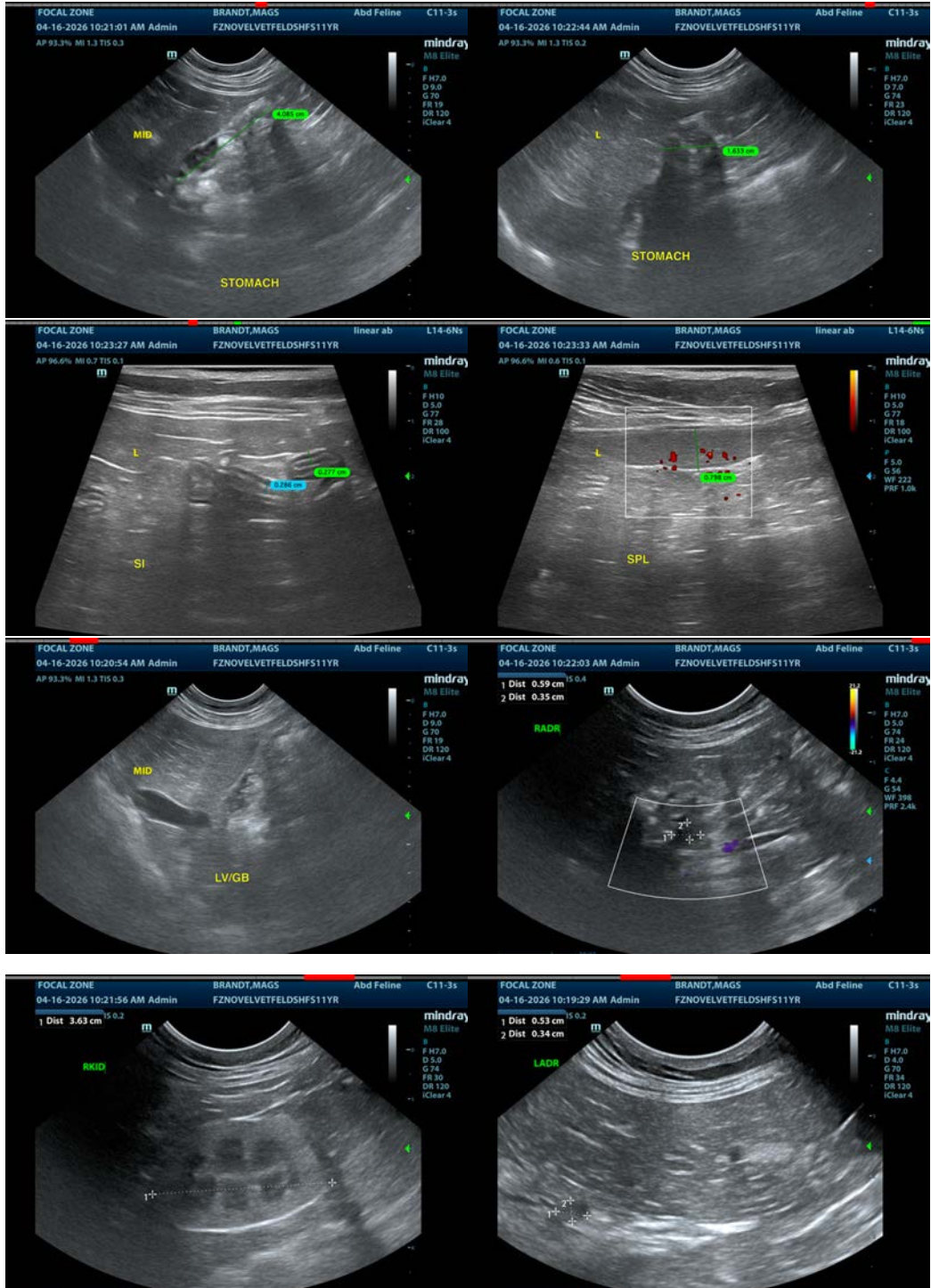
Dr. Gibbs

INVOICE

74509

DATE

4/16/26





PATIENT

Mags Brandt

SPECIES

Feline

BREED

DSH

SEX

Spayed Female

AGE

11 Years

WEIGHT

4.55 kg

INTERPRETED BY

Kathleen Sennello DVM,
MS, Diplomate ACVIM
(Small Animal Internal
Medicine)

**IMAGING
PERFORMED BY**

Crystal Hill

HOSPITAL NAME

Novel Vet

REFERRING VET

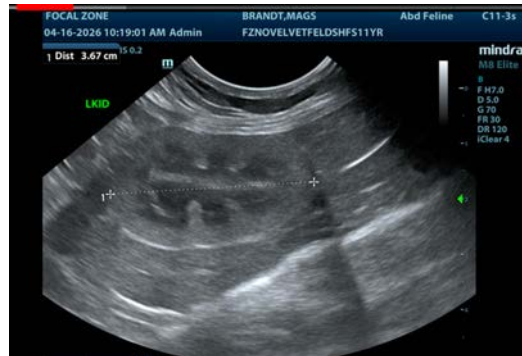Dr. Gibbs

INVOICE

74509

DATE

4/16/26



The information and recommendations provided are based on the images presented by the referring veterinarian/sonographer. No evaluation can be communicated regarding pathology that was not visible in the image/video clips provided.

Thank you for this referral. If the clinical or image interpretation does not parallel your findings or if I can be of any further assistance please contact me.

Kathleen Sennello DVM,MS, Diplomate ACVIM (Small animal Internal Medicine)

info@sonopath.com