IMAGING PERFORMED BY

IntraPet.com

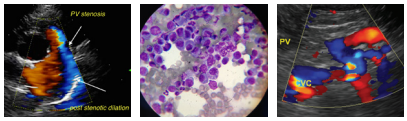

SonoPath
Clinical Sonography & Telecytology
EDUCATIONAL TELECONSULTATION SERVICES™
1-800-838-4268 info@sonopath.com SonoPath.com

DATE
4/15/22

PATIENT
Sami Geisel

SPECIES
Canine

BREED
German Shorthair Pointer

SEX
Spayed Female

AGE
5/30/08

WEIGHT
56.2 Pounds

INTERPRETED BY
Kathleen Sennello DVM, MS, Diplomate ACVIM (Small Animal Internal Medicine)

IMAGING PERFORMED BY
Rachel Brilhart RDMS

HOSPITAL NAME
Bel Air Vet Hospital

REFERRING VET
Dr. Stevenson

INVOICE
36961

PRESENTING CLINICAL SIGNS

Increase ALKP. On rad stomach axis shift cranial (liver shift?). “Busy” GI lat view. Decreased detail along abd midline. Stomach axis shift left on v/d rad.

Current Medications: Incurin 1mg- 2 SID, Proin ER 1 SID, ursodiol 1 SID, Denamarin 1 SID, Meloxidyl 1.5mg/mL to 56# mark.
Date of Previous IntraPet Ultrasound: 6/5/2020. See attached.
Date of Previous IntraPet Ultrasound: 6/5/2020 and 8/27/2019.

Sedation: Not required to complete full diagnostic ultrasound.
Stat Report: Not requested.

ULTRASONOGRAPHIC EXAMINATION OF THE ABDOMEN

Urinary System

The urinary bladder is moderately distended with anechoic urine. The Bladder wall, trigone, ureteral papillae and visible urethra (to a depth of 2cm) appear normal with no evidence of wall thickening, mucosal irregularities, masses or cystic calculi.

The left kidney has a normal shape and size (6.85 cm). Overall echogenicity is normal with adequate corticomedullary distinction and a typical 1:3 cortex:medulla ratio. There is no evidence of perinephric inflammation or effusion. There is no evidence of pyelectasia, nephroliths, infarcts or hydroureter. Renal vasculature is normal.

The right kidney has a normal shape and size (7.4 cm). Overall echogenicity is normal with adequate corticomedullary distinction and a typical 1:3 cortex:medulla ratio. There is no evidence of perinephric inflammation or effusion. There is no evidence of pyelectasia, nephroliths, infarcts or hydroureter. Renal vasculature is normal.

Adrenal Glands

The left adrenal gland is borderline large in size measuring 0.94 cm at the cranial pole, 0.84 cm at the caudal pole, and 3.22 cm in length. It is observed in its normal position cranial to the left renal artery. It is somewhat abnormal in appearance in that there is a hyperechoic region in the cranial pole measuring 0.48 cm x 0.48 cm. This hyperechoic region does not deform the shape of the adrenal gland (measurements of the adrenal gland are similar to that recorded 6/2020).

The right adrenal gland is normal in size measuring 0.50 cm at the caudal pole. It is observed in its normal position between the cranial aspect of the right kidney and the caudal vena cava. It is normal in appearance (uniformly hypoechoic) and shape with no evidence of a mass effect.

Spleen

The spleen is subjectively normal in size. The spleen echotexture is heterogenous and mottled, the splenic capsule is smooth with no irregularities. The blood flow through the hilus and splenic parenchyma appears normal. No focal parenchymal abnormalities are visualized.

Liver

The liver is large in size, and normal in echogenicity with smooth peripheral margins. The parenchyma is heterogenous in echotexture with subtle, indistinct focal mottling. The visible portions of the vasculature and biliary tract appear normal. No focal nodules or cystic lesions are observed.

The gallbladder lumen is moderately distended. The wall of the gall bladder is not thickened and has a smooth mucosal surface. Luminal contents are primarily anechoic. The cystic and common bile ducts are normal/not visible.

Gastrointestinal

The stomach contains minimal luminal contents. It measures at a normal thickness of <0.7cm with some variability due to the presence of rugal folds. The distinction of the gastric wall layers is adequate and there is no impression of reduced peristaltic activity. No masses or focal lesions were observed.

The visualized areas of duodenum, jejunum and ileum have a relatively uniform diameter with minimal fluid distension. Wall thickness is normal. Bowel loops follow a curvilinear path with distinct wall layering maintaining the typical 1:3 muscularis:mucosa layer ratio. The duodenum measured as normal (between 0.3-0.5cm in wall thickness) and the jejunum measured as normal (between 0.2-0.47cm.) Visualized peristalsis appears appropriate. There were no focal lesions consistent with obstruction or a mass effect observed.

The ileocecal junction was visualized and exhibited normal intact wall layering and is subjectively of normal thickness. Sections of colon are visualized with formed fecal material and gas shadowing distally. There is no observed focal or generalized colon wall thickening or loss of layering.

Pancreas

The pancreas is normal and isoechoic to surrounding mesentery. There is no evidence of nodules or cystic lesions. There is no evidence of regional mesenteric inflammation or fluid.

Free Abdomen

Evaluation of the peritoneal cavity did not reveal any evidence of effusion, or subjective lymphadenomegaly. The Medial iliac nodes appear normal and there was no evidence of a caudal aortic thrombus at the bifurcation. The omentum is of normal uniform echogenicity.

ULTRASONOGRAPHIC FINDINGS

- Borderline large left adrenal gland – The left adrenal gland appears somewhat enlarged, but the measurements obtained today are very similar to those obtained in the previous scan (6/2020). The new finding is a hyperechoic region in the cranial pole, the significance of which is unclear. This could be an incidental finding or an early neoplastic lesion.

- Mottled spleen – The diffuse splenic changes are non-specific and could be consistent with lymphoid hyperplasia, extramedullary hematopoiesis, infiltrative neoplasia, inflammation, other. Cytology or histopathology would be necessary to get a definitive diagnosis. The spleen was described as mottled on the previous scan (6/2020) so I suspect this is an incidental finding.

- Large, heterogeneous liver – The diffuse hepatic changes are non-specific and could be consistent with vacuolar hepatopathy, nodular hyperplasia, inflammatory/immune-mediated disease, fibrosis, extramedullary hematopoiesis, toxic hepatopathy (e.g., copper), infiltrative neoplasia (less likely) or other hepatopathy. Based on the description, I suspect this has progressed, as the liver appears large and fairly heterogeneous on today's evaluation).

INTERPRETATION OF THE FINDINGS & FURTHER RECOMMENDATIONS

The left adrenal gland appears somewhat large, that is stable from a scan two years ago, I suspect this is likely either insignificance or associated with mild Cushing's disease. On today's scan, there is a hyperechoic lesion in the cranial pole of the left adrenal gland. This lesion does not deviate the shape of the adrenal, but could still be an early neoplastic lesion. Recommend blood pressure evaluation and continued monitoring with ultrasound. If symptoms of Cushing's are present, then consider adrenal function testing. Recommend

recheck of the left adrenal gland in approximately two months, as these lesions can change rapidly.

The liver is mottled. This is a non-specific finding. No focal lesions are observed. Consider a liver function test and a fine needle aspirate of the liver. As described above, if signs of Cushing's are present, you could consider adrenal function testing.

Consider three view thoracic radiographs to rule out concurrent thoracic disease/involvement.

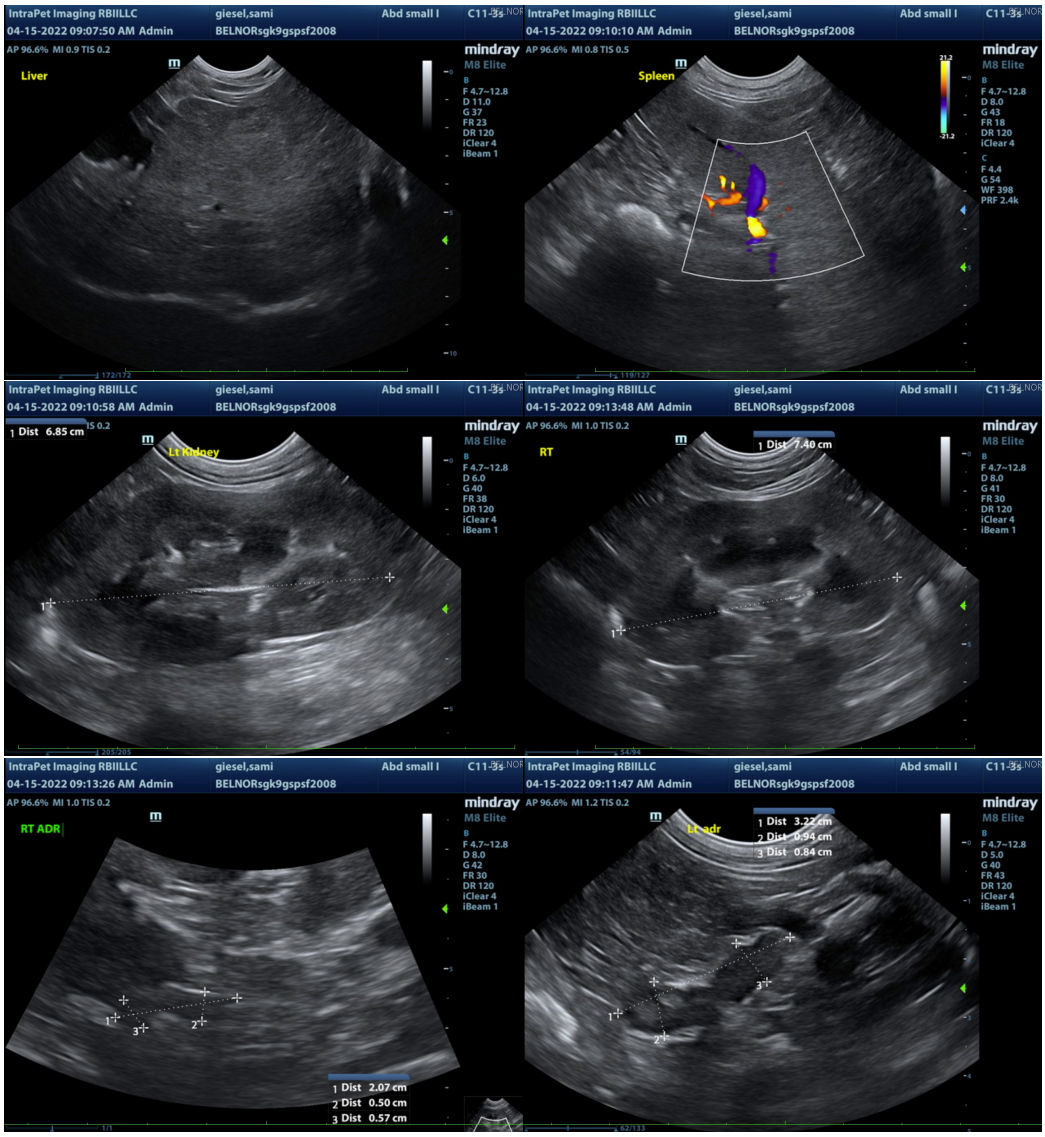

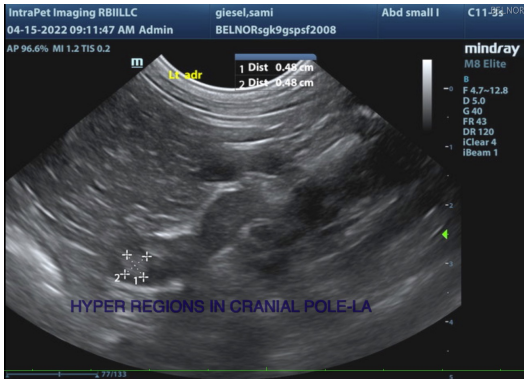

The information and recommendations provided are based on the images presented by the referring veterinarian/sonographer. No evaluation can be communicated regarding pathology that was not visible in the image/video clips provided.

Thank you for this referral. If the clinical or image interpretation does not parallel your findings or if I can be of any further assistance please contact me.

Kathleen Sennello DVM,MS, Diplomate ACVIM (Small animal Internal Medicine)
kathleen.sennello@sonopath.com