

PATIENT

Mickey Gatewood

SPECIES

Canine

BREED

Border Collie

SEX

Spayed Female

AGE

11 Years 5 Months

WEIGHT

48.8 lbs

INTERPRETED BY

Kathleen Sennello DVM,
 MS, Diplomate ACVIM
 (Small Animal Internal
 Medicine)

IMAGING PERFORMED BY

Kathleen Byrnes

HOSPITAL NAME

Animal Clinic Madison
 Mayodan

REFERRING VET

Dr. McKinlay

INVOICE

74423

DATE

4/14/26

PRESENTING CLINICAL SIGNS

P presented for ultrasound due to PU/PD

Abnormal PE/Chem/CBC/UA Results: usg 1.016-1.020, UPC 0.1, ALT 52- 173, ALKP 107-821, LDDST not supportive of Cushing's

ULTRASONOGRAPHIC EXAMINATION OF THE ABDOMEN

Urinary System

The urinary bladder is moderately distended with anechoic urine. The Bladder wall, trigone, ureteral papillae and visible urethra (to a depth of 2cm) appear normal with no evidence of wall thickening, mucosal irregularities, masses or cystic calculi.

The left kidney has a normal shape and size (6.81 cm) with mild pyelectasia at 0.33 cm. Overall echogenicity is normal with adequate corticomedullary distinction and a typical 1:3 cortex:medulla ratio. There is no evidence of focal perinephric inflammation or effusion. There is no evidence of nephroliths, infarcts or hydroureter. Renal vasculature is normal.

The right kidney has a normal shape and size (5.84 cm). Overall echogenicity is normal with adequate corticomedullary distinction and a typical 1:3 cortex:medulla ratio. There is no evidence of focal perinephric inflammation or effusion. There is no evidence of pyelectasia, nephroliths, infarcts or hydroureter. Renal vasculature is normal.

Adrenal Glands

The left adrenal gland is large and irregular in shape. It is observed in its normal position cranial to the left renal artery. It is abnormal in appearance in that the caudal pole is extremely enlarged, with a focal mass effect. The cranial pole measures 1.57 cm. The caudal pole measures 4.54 cm, with the poorly defined hyperechoic mass effect measuring 4.63 cm x 4.49 cm with some concern for possible vascular invasion.

The right adrenal gland is large and irregular in appearance, measuring 1.14 cm at the cranial pole and 0.65 cm at the caudal pole. It is observed in its normal position between the cranial aspect of the right kidney and the caudal vena cava. In the mid cranial aspect of the gland there is a poorly defined hyperechoic mass effect measuring 1.18 cm x 1.34 cm.

Spleen

The spleen is subjectively normal in size (2.08 cm), echotexture is homogenous, and the splenic capsule is smooth with no irregularities. The blood flow through the hilus and splenic parenchyma appears normal. No focal parenchymal abnormalities are visualized.

Liver

The liver is subjectively normal in size, and echogenicity with smooth peripheral margins. The parenchyma is mildly heterogenous in echotexture with subtle, indistinct focal mottling. The visible portions of the vasculature and biliary tract appear normal. No focal nodules or cystic lesions are observed.



PATIENT

Mickey Gatewood

The gall bladder lumen is moderately distended. The wall of the gall bladder is not thickened and has a smooth mucosal surface. Luminal contents are mild and likely incidental at this time. The cystic and common bile ducts are normal/not visible.

SPECIES

Canine

Gastrointestinal

The stomach contains moderate fluid/shadowing ingesta/gas. It measures at a normal thickness of <0.7cm with some variability due to the presence of rugal folds. The distinction of the gastric wall layers is adequate and there is no impression of reduced peristaltic activity. No masses or focal lesions were observed.

BREED

Border Collie

The visualized areas of duodenum, jejunum and ileum have a relatively uniform diameter with mild fluid and gas distension. Wall thickness is normal. Bowel loops follow a curvilinear path with distinct wall layering maintaining the typical 1:3 muscularis:mucosa layer ratio. Duodenum wall measures 0.50 cm. Jejunum wall measures 0.35 cm. Visualized peristalsis appears appropriate. There were no focal lesions consistent with obstruction or a mass effect observed.

SEX

Spayed Female

AGE

11 Years 5 Months

Sections of colon are visualized with formed fecal material and gas shadowing distally. There is no observed focal or generalized colon wall thickening or loss of layering.

WEIGHT

48.8 lbs

Pancreas

The pancreas is normal and isoechoic to surrounding mesentery. There is no evidence of nodules or cystic lesions. There is no evidence of regional mesenteric inflammation or fluid.

INTERPRETED BY

Kathleen Sennello DVM,
 MS, Diplomate ACVIM
 (Small Animal Internal
 Medicine)

Free Abdomen

There is scant free fluid near the left kidney with no evidence of a significant diffuse lymphadenopathy. A sublumbar lymph node is prominent at 0.44 cm. The omentum is generally of normal echogenicity.

ULTRASONOGRAPHIC FINDINGS

IMAGING PERFORMED BY

Kathleen Byrnes

- Large, hyperechoic mass effect visualized associated with the left adrenal – The large size of this lesion increases the concern for a carcinoma or pheochromocytoma. Other differentials are possible. There could be concern for vascular invasion in the region.
- Poorly defined hyperechoic mass effect visualized in the mid body of the right adrenal – Possible differentials include an adenoma, carcinoma, pheochromocytoma, or metastatic lesions.
- Mildly heterogeneous liver – The diffuse hepatic changes are non-specific and could be consistent with vacuolar hepatopathy, nodular hyperplasia, inflammatory/immune-mediated disease, fibrosis, extramedullary hematopoiesis, toxic hepatopathy (e.g., copper), infiltrative neoplasia (less likely) or other hepatopathy.

HOSPITAL NAME

Animal Clinic Madison
 Mayodan

REFERRING VET

Dr. McKinlay

INVOICE

74423

DATE

4/14/26

INTERPRETATION OF THE FINDINGS & FURTHER RECOMMENDATIONS

There are lesions evident on both adrenals. There is a large mass effect visualized associated with the left adrenal, and a smaller lesion visualized associated with the right adrenal. The size of the left adrenal is concerning for a neoplastic lesion. Recommend a blood pressure evaluation. If hypertension is present, consider measuring catecholamine levels, looking for a possible pheochromocytoma. Additionally, you could consider an adrenal panel to University of Tennessee combined with an ACTH



PATIENT

Mickey Gatewood

SPECIES

Canine

BREED

Border Collie

SEX

Spayed Female

AGE

11 Years 5 Months

WEIGHT

48.8 lbs

INTERPRETED BY

Kathleen Sennello DVM,
 MS, Diplomate ACVIM
 (Small Animal Internal
 Medicine)

IMAGING PERFORMED BY

Kathleen Byrnes

HOSPITAL NAME

Animal Clinic Madison
 Mayodan

REFERRING VET

Dr. McKinlay

INVOICE

74423

DATE

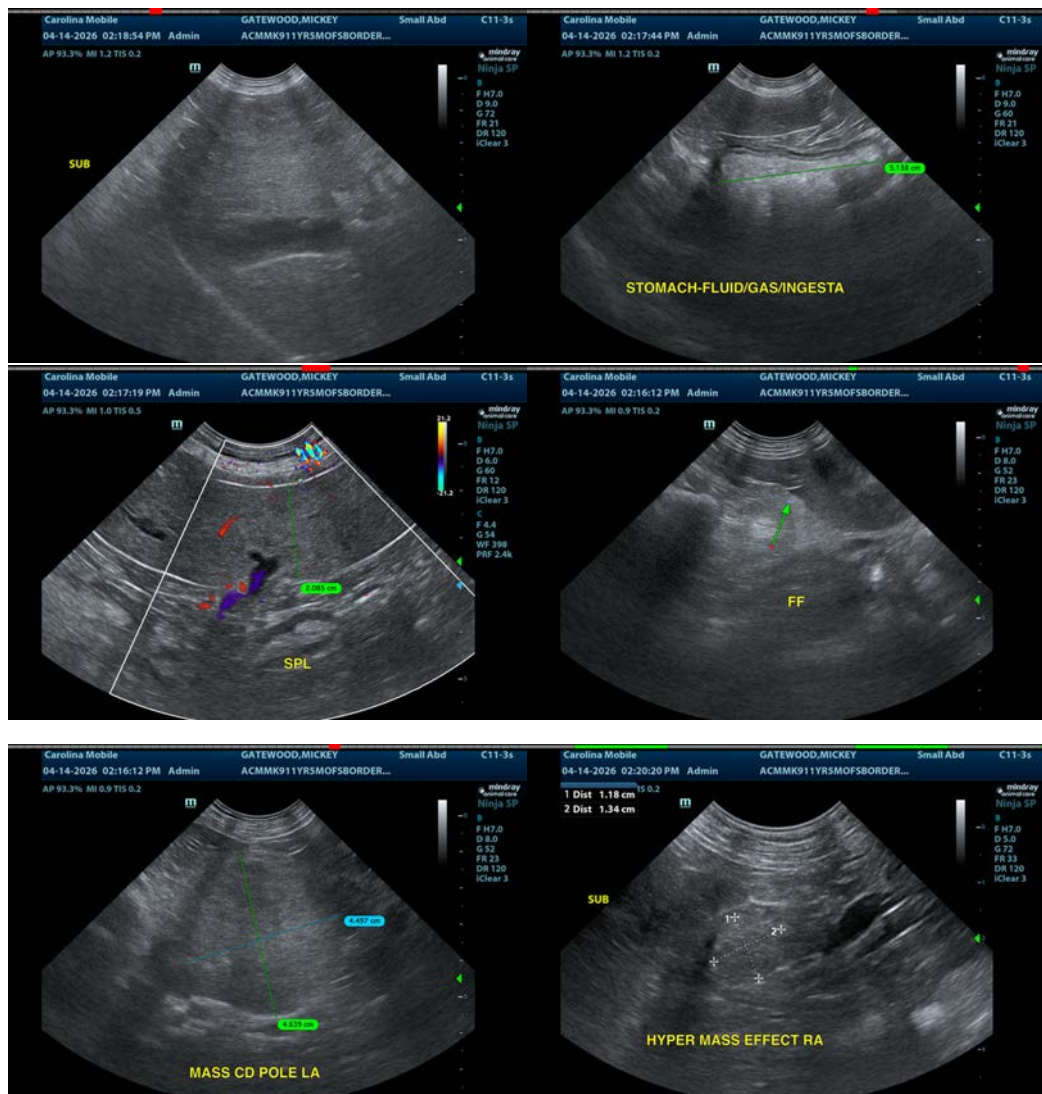
4/14/26

stimulation test, looking for other non-cortisol adrenal hormones that could be being produced.

Ultimately, a contrast CT scan is strongly recommended to further evaluate and to assess the patient for possible surgical intervention. If surgery is not an option, medical therapy could be considered generally for palliative therapy.

Consultation with a veterinary oncologist could be considered, as medical chemotherapeutic options may also be available.

Recommend three view thoracic radiographs to evaluate for possible concurrent thoracic disease/involvement (disregard if this has already been done).





PATIENT

Mickey Gatewood

SPECIES

Canine

BREED

Border Collie

SEX

Spayed Female

AGE

11 Years 5 Months

WEIGHT

48.8 lbs

INTERPRETED BY

Kathleen Sennello DVM,
 MS, Diplomate ACVIM
 (Small Animal Internal
 Medicine)

IMAGING PERFORMED BY

Kathleen Byrnes

HOSPITAL NAME

Animal Clinic Madison
 Mayodan

REFERRING VET

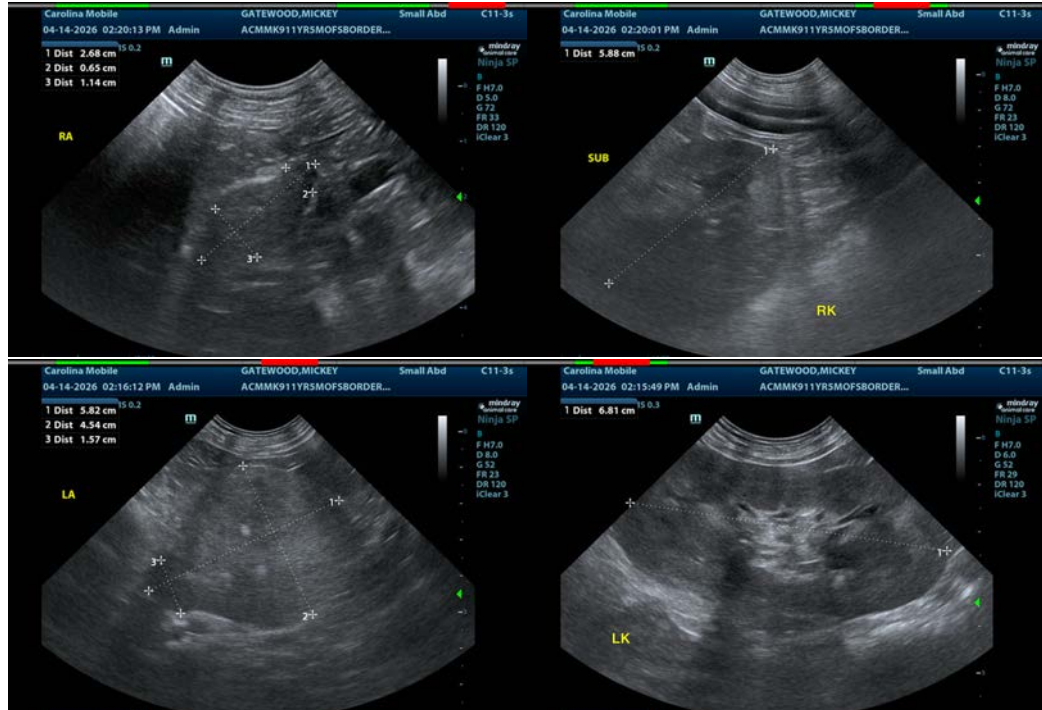
Dr. McKinlay

INVOICE

74423

DATE

4/14/26



The information and recommendations provided are based on the images presented by the referring veterinarian/sonographer. No evaluation can be communicated regarding pathology that was not visible in the image/video clips provided.

Thank you for this referral. If the clinical or image interpretation does not parallel your findings or if I can be of any further assistance please contact me.

Kathleen Sennello DVM,MS, Diplomate ACVIM (Small animal Internal Medicine)

info@sonopath.com