



DATE PRESENTING CLINICAL SIGNS

4/14/26

Patient History: Presented 3/25/26 for annual PE. O noted at time of PE that has gained a significant amount of weight despite trying for weight loss and polydypsia, arthritis/joint issues. On PE, BCS 8/9, mild-mod dental calc, lenticular sclerosis, cystic mass around thoracolumbar spine, papillomas, dermal cyst RF carpus. BW showed significant liver elevations but normal T4. Recommended LDDST but subsequent results not supportive of Cushing's.

PATIENT

Callie Patterson

SPECIES

Canine

Current Medications: Simparica Trio.

Labwork Results: Attached, reported as: CBC/CHEM/T4: ALT 177, ALP 1098, chol 375. LDDST: pre 5.41, 4 hrs post 0.82, 8 hrs post 0.5<

Date of Previous IntraPet Ultrasound: No previous.

Sedation: Not required to complete full diagnostic ultrasound.

Stat Report: Not requested.

Imaging Performed by: Rachel Brillhart, RDMS.

BREED

Puggle

SEX

Spayed Female

ULTRASONOGRAPHIC EXAMINATION OF THE ABDOMEN

Urinary System

The urinary bladder is moderately distended with anechoic urine. The Bladder wall, trigone, ureteral papillae and visible urethra (to a depth of 2cm) appear normal with no evidence of wall thickening, mucosal irregularities, masses or cystic calculi.

AGE

8/29/14

The left kidney has a normal shape and size (5.49 cm) with small non-obstructive nephroliths. Overall echogenicity is slightly hyperechoic with poor corticomedullary distinction and a typical 1:3 cortex:medulla ratio. There is no evidence of focal perinephric inflammation or effusion. There is no evidence of pyelectasia, infarcts or hydroureter. Renal vasculature is normal.

WEIGHT

40.9 lbs

The right kidney has a normal shape and size (5.23 cm) with non-obstructive nephroliths. Overall echogenicity is slightly hyperechoic with poor corticomedullary distinction and a typical 1:3 cortex:medulla ratio. There is no evidence of focal perinephric inflammation or effusion. There is no evidence of pyelectasia, infarcts or hydroureter. Renal vasculature is normal.

INTERPRETED BY

Kathleen Sennello DVM,
MS, Diplomate ACVIM
(Small Animal Internal
Medicine)

Adrenal Glands

The left adrenal gland is normal in size measuring 0.69 cm at the cranial pole and 0.66 cm at the caudal pole. It is observed in its normal position cranial to the left renal artery. It is normal in appearance (uniformly hypoechoic) and shape with no evidence of a mass effect.

HOSPITAL NAME

Chadwell Animal
Hospital

The right adrenal gland is normal in size measuring 0.74 cm at the cranial pole and 0.70 cm at the caudal pole. It is observed in its normal position between the cranial aspect of the right kidney and the caudal vena cava. It is normal in appearance (uniformly hypoechoic) and shape with no evidence of a mass effect.

REFERRING VET

Dr. Mengers

Spleen

The spleen is subjectively normal in size (1.06 cm), echotexture is homogenous, and the splenic capsule is smooth with no irregularities. The blood flow through the hilus and splenic parenchyma appears normal. No focal parenchymal abnormalities are visualized.

INVOICE

74446

Liver

The liver is large in size and irregular. The parenchyma is heterogenous in echotexture with subtle, indistinct focal mottling. The visible portions of the vasculature and biliary tract appear normal. There are occasional ill-

defined hypoechoic nodules in the parenchyma, examples measure 0.74 cm and 0.75 cm. Additionally, there is a poorly defined hyperechoic mass effect on the right side of the liver measuring 4.63 cm in diameter, and a mixed echogenicity hyperechoic mass effect on the left side of the liver measuring 4.82 cm x 5.47 cm.

The gall bladder lumen is moderately distended. The wall of the gall bladder is not thickened and has a smooth mucosal surface. Luminal contents are mild and likely incidental at this time. The cystic and common bile ducts are normal/not visible.

Gastrointestinal

The stomach contains minimal luminal contents. It measures at a normal thickness of <0.7cm with some variability due to the presence of rugal folds. The distinction of the gastric wall layers is adequate and there is no impression of reduced peristaltic activity. No masses or focal lesions were observed.

The visualized areas of duodenum, jejunum and ileum have a relatively uniform diameter with minimal fluid distension. Wall thickness is normal. Bowel loops follow a curvilinear path with distinct wall layering maintaining the typical 1:3 muscularis:mucosa layer ratio. Duodenum wall measures 0.41 cm. Jejunum wall measures 0.36 cm. Visualized peristalsis appears appropriate. There were no focal lesions consistent with obstruction or a mass effect observed.

Sections of colon are visualized with formed fecal material and gas shadowing distally. There is no observed focal or generalized colon wall thickening or loss of layering.

Pancreas

The right limb of the pancreas is prominent and mottled compared to the surrounding isoechoic mesentery. There is no evidence of nodules or cystic lesions. There is no evidence of regional mesenteric inflammation or fluid.

Free Abdomen

Evaluation of the peritoneal cavity did not reveal any evidence of effusion, or subjective lymphadenomegaly. The Medial iliac nodes appear normal and there was no evidence of a caudal aortic thrombus at the bifurcation. The omentum is of normal uniform echogenicity.

ULTRASONOGRAPHIC FINDINGS

- Age related changes and non-obstructive nephroliths visualized associated with both kidneys.
- Pancreatic changes most consistent with chronic pancreatic remodeling +/- chronic pancreatitis.
- Large, heterogeneous, irregular, rounded liver with occasional ill-defined hypoechoic nodules and larger, poorly defined, hyperechoic/mixed echogenicity mass lesions – The hypoechoic nodules have a somewhat benign appearance. The larger lesions could represent adenomas, carcinomas, other.

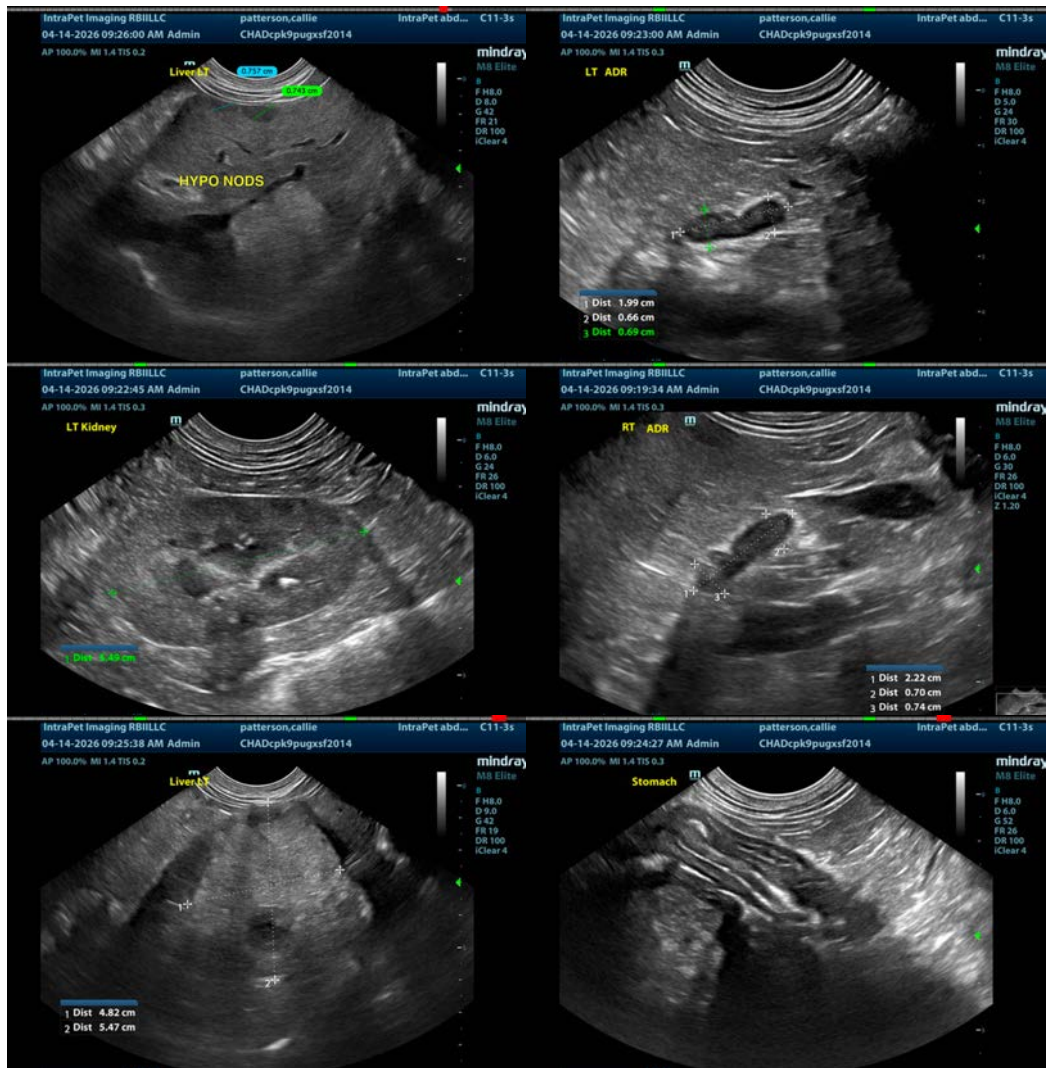
INTERPRETATION OF THE FINDINGS & FURTHER RECOMMENDATIONS

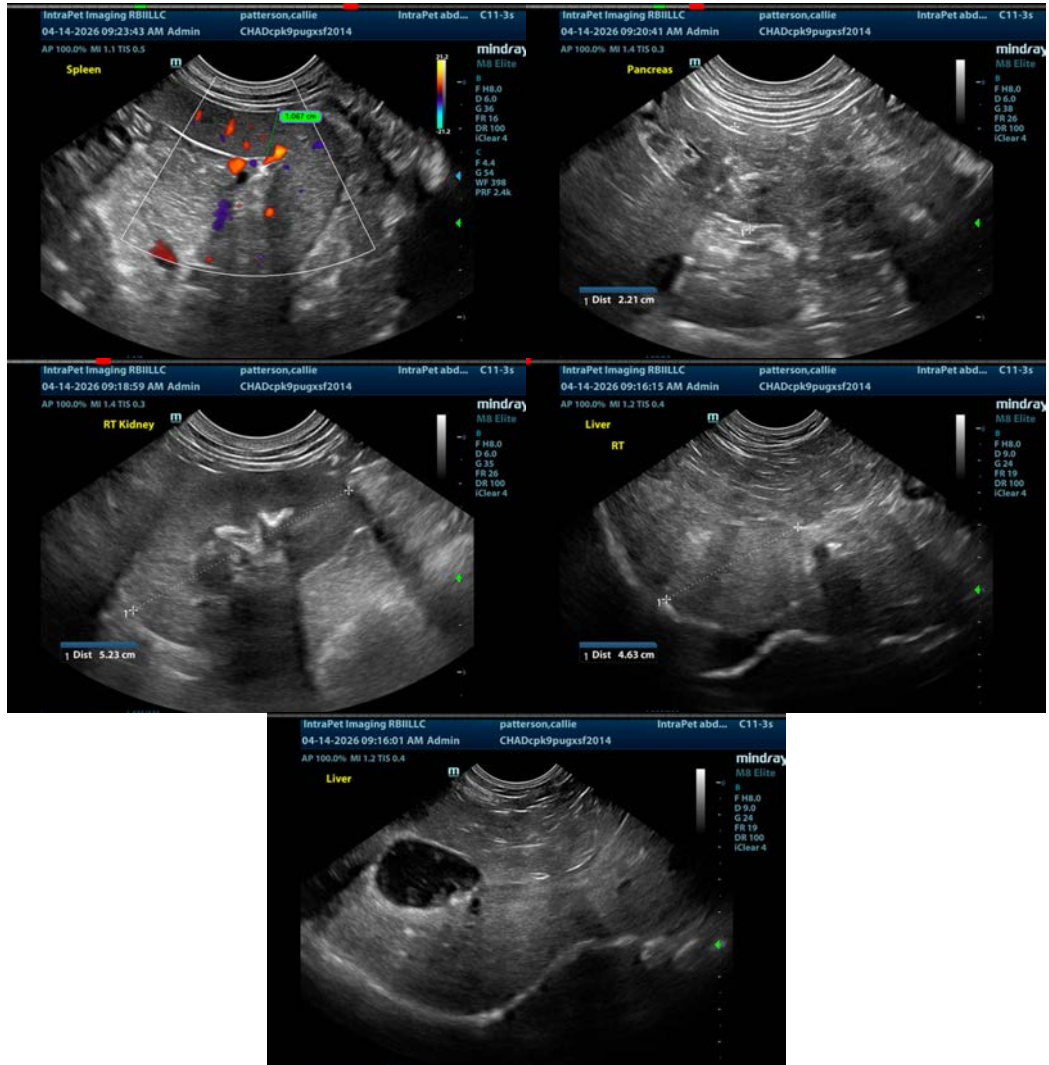
Both kidneys have changes consistent with chronic age related renal changes. Correlate with urinalysis, looking for urine concentrating ability. Consider a blood pressure and urine protein to creatinine ratio for further assessment.

The liver is large, heterogeneous and irregular with ill-defined hypoechoic and larger hyper/mixed echogenicity mass lesions. The nature of these lesions is uncertain. If a safe window for sampling is available, consider a fine needle aspirate of the large hyperechoic mixed echogenicity lesion on the left side, and ideally a contrast CT scan to get better detail as to the location and extent of these lesions to assess for possible surgical removal.

It is uncertain if the PU/PD s secondary t the renal disease or the liver issues. You could consider pre- and post-prandial bile acids to assess liver function to see if this is contributing.

Recommend three view thoracic radiographs to evaluate for possible concurrent thoracic disease/involvement (disregard if this has already been done).





The information and recommendations provided are based on the images presented by the referring veterinarian/sonographer. No evaluation can be communicated regarding pathology that was not visible in the image/video clips provided.

Thank you for this referral. If the clinical or image interpretation does not parallel your findings or if I can be of any further assistance please contact me.

Kathleen Sennello DVM,MS, Diplomate ACVIM (Small animal Internal Medicine)
 info@sonopath.com