

**DATE PRESENTING CLINICAL SIGNS**

4/14/23

Patient presents for a 5 day history of anorexia and intermittent vomiting. Pet is eating very little - maybe a few treats and drinking very little. No history of FB/toxin ingestion. Vomiting yellow bile with mucus and rare flecks of blood. On exam 6 lb weight loss, tense abdomen. Slight intermittent head tilt to the right.

PATIENT

Moe Schmuft

Current Medications: Cerenia 28mg sq 4/13 and to start Cerenia 60 mg PO 4/14, Famotidine 20mg sq 4/13 to start 20mg oral BID 4/14, Trazodone 100mg 1-2T BID prn anxiety- prn for years, Thyroxine 0.2mg bid for years, Gabapentin 300mg 1 am and 2 pm for calming, Carprofen 100mg 1/2 BID months

SPECIES

Canine

Lab Results: Unremarkable.

Radiographs: Possible mass/FB in stomach vs ingesta.

Date of Previous IntraPet Ultrasound: No previous.

BREED

Labrador X

Sedation: Not required to complete full diagnostic ultrasound.

Stat Report: STAT requested.

Imaging Performed By: Rachel Brillhart, RDMS.

SEX

Neutered Male

ULTRASONOGRAPHIC EXAMINATION OF THE ABDOMEN**Urinary System**

The urinary bladder is moderately distended with anechoic urine. The Bladder wall, trigone, ureteral papillae and visible urethra (to a depth of 2cm) appear normal with no evidence of wall thickening, mucosal irregularities, masses or cystic calculi.

AGE

5/1/08

The prostate is normal in size (1.5 cm) and shape for this neutered male dog. The parenchyma is homogenous and the external margins are smooth. The prostatic urethra appears normal with no evidence of irregularity, invasion, mass effect or calculi.

WEIGHT

61 Pounds

The left kidney has a normal shape and size (6.05 cm). Overall echogenicity is normal with adequate corticomedullary distinction and a typical 1:3 cortex:medulla ratio. There is no evidence of focal perinephric inflammation or effusion. There is no evidence of pyelectasia, nephroliths, infarcts or hydroureter. Renal vasculature is normal.

INTERPRETED BY

Kathleen Sennello DVM,
MS, Diplomate ACVIM
(Small Animal Internal
Medicine)

The right kidney has a normal shape and size (6.98 cm). Overall echogenicity is normal with adequate corticomedullary distinction and a typical 1:3 cortex:medulla ratio. There is no evidence of focal perinephric inflammation or effusion. There is no evidence of pyelectasia, nephroliths, infarcts or hydroureter. Renal vasculature is normal.

HOSPITAL NAME

Fullerton AH

Adrenal Glands

The left adrenal gland is normal in size measuring 0.94 cm at the caudal pole. It is observed in its normal position cranial to the left renal artery. It is normal in appearance (uniformly hypoechoic) and shape with no evidence of a mass effect.

REFERRING VET

Dr. Unger

The right adrenal gland is normal in size measuring 0.84 cm at the caudal pole. It is observed in its normal position between the cranial aspect of the right kidney and the caudal vena cava. It is normal in appearance (uniformly hypoechoic) and shape with no evidence of a mass effect.

INVOICE

46677

Spleen

The spleen is subjectively normal in size, echotexture is homogenous, and the splenic capsule is smooth with no irregularities. The blood flow through the hilus and splenic parenchyma appears normal. No focal parenchymal abnormalities are visualized.

Liver

The liver is subjectively normal in size, and echogenicity with smooth peripheral margins. The parenchyma is heterogenous in echotexture with subtle, indistinct focal mottling. The visible portions of the vasculature and biliary tract appear normal. No focal nodules or cystic lesions are observed.

The gallbladder lumen is moderately distended. The wall of the gall bladder is not thickened and has a smooth mucosal surface. Luminal contents are mild and primarily anechoic. The cystic and common bile ducts are normal/not visible.

Gastrointestinal

The stomach is mildly distended with gas and a small amount of fluid. In some areas the gastric wall appears relatively normal with intact wall layering, measuring less 0.70 cm. In other areas, gastric wall appears severely thickened and irregular, creating somewhat of a mass effect. There is a focal area of gastric wall measuring 7.15 cm x 4.13 cm, which appears to have complete loss of wall layering, creating a mass effect. Some of these areas appear to involve the more distal stomach in the region of the pylorus, but this appears fairly extensive.

The visualized areas of duodenum, jejunum and ileum have a relatively uniform diameter with minimal fluid distension. Wall thickness is normal. Bowel loops follow a curvilinear path with distinct wall layering maintaining the typical 1:3 muscularis:mucosa layer ratio. The duodenum measured as normal (between 0.3-0.5cm in wall thickness) and the jejunum measured as normal (between 0.2-0.47cm.) Visualized peristalsis appears appropriate. There were no focal lesions consistent with obstruction or a mass effect observed.

The ileocecal junction was visualized and exhibited normal intact wall layering and is subjectively of normal thickness. Sections of colon are visualized with formed fecal material and gas shadowing distally. There is no observed focal or generalized colon wall thickening or loss of layering.

Pancreas

The area of the pancreas is normal and isoechoic to surrounding mesentery. There is no evidence of nodules or cystic lesions. There is no evidence of regional mesenteric inflammation or fluid.

Free Abdomen

Evaluation of the peritoneal cavity did not reveal any evidence of effusion. There is a large irregular lymph node in the right cranial abdomen measuring 1.65 cm x 1.26 cm. The omentum is hyperechoic around the stomach.

ULTRASONOGRAPHIC FINDINGS

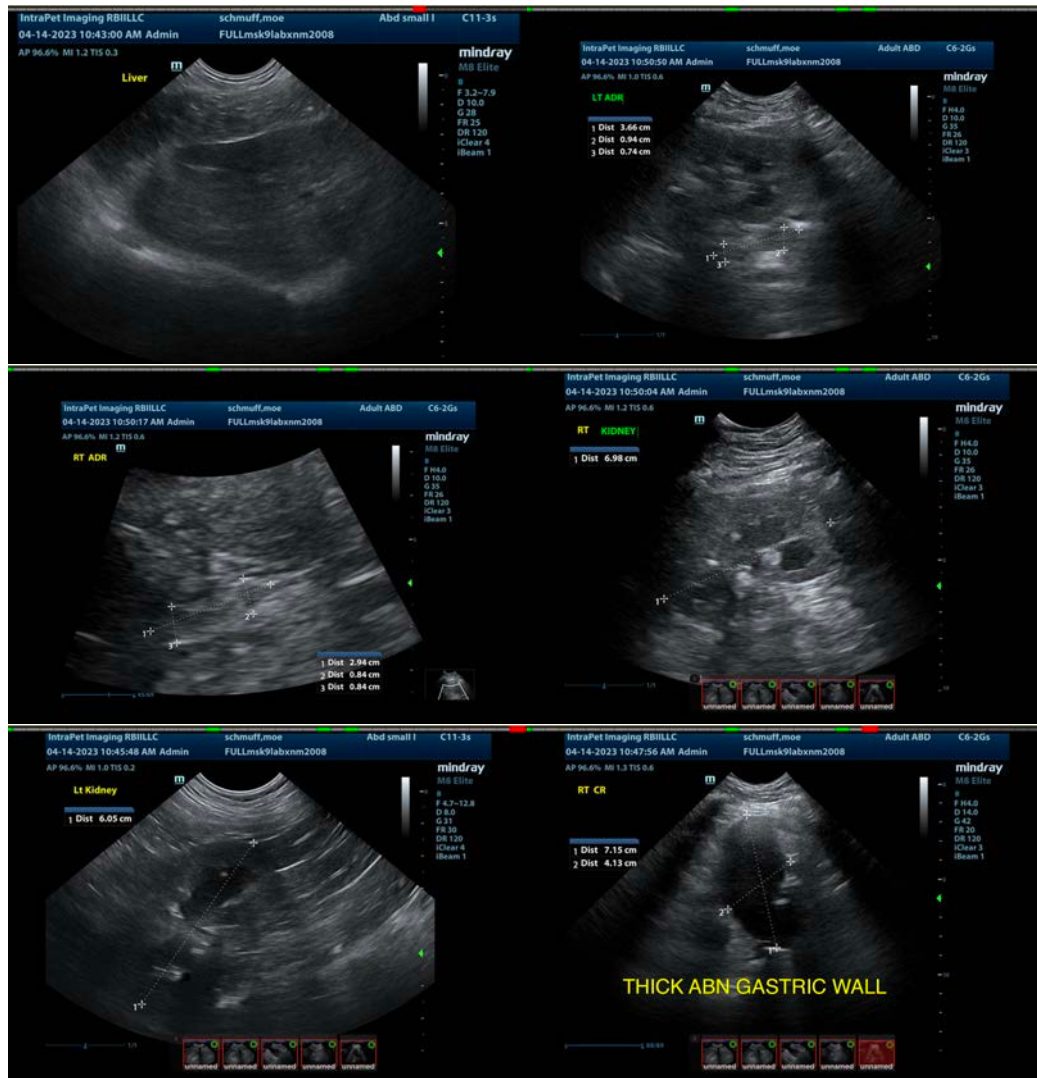
- Heterogeneous liver – The hepatic changes are consistent with age-related parenchymal remodeling and are not considered clinically significant at this time.
- Focal area of gastric wall, which is severely irregular, thickened, and has loss of wall layering. Findings are most concerning for a gastric mass lesion (carcinoma, round cell neoplasia, adenoma, other). Additionally, a severely hyperplastic ulcer, etc. is possible.
- Prominent abnormal cranial abdominal lymph node – This could represent a reactive or metastatic lymph node.

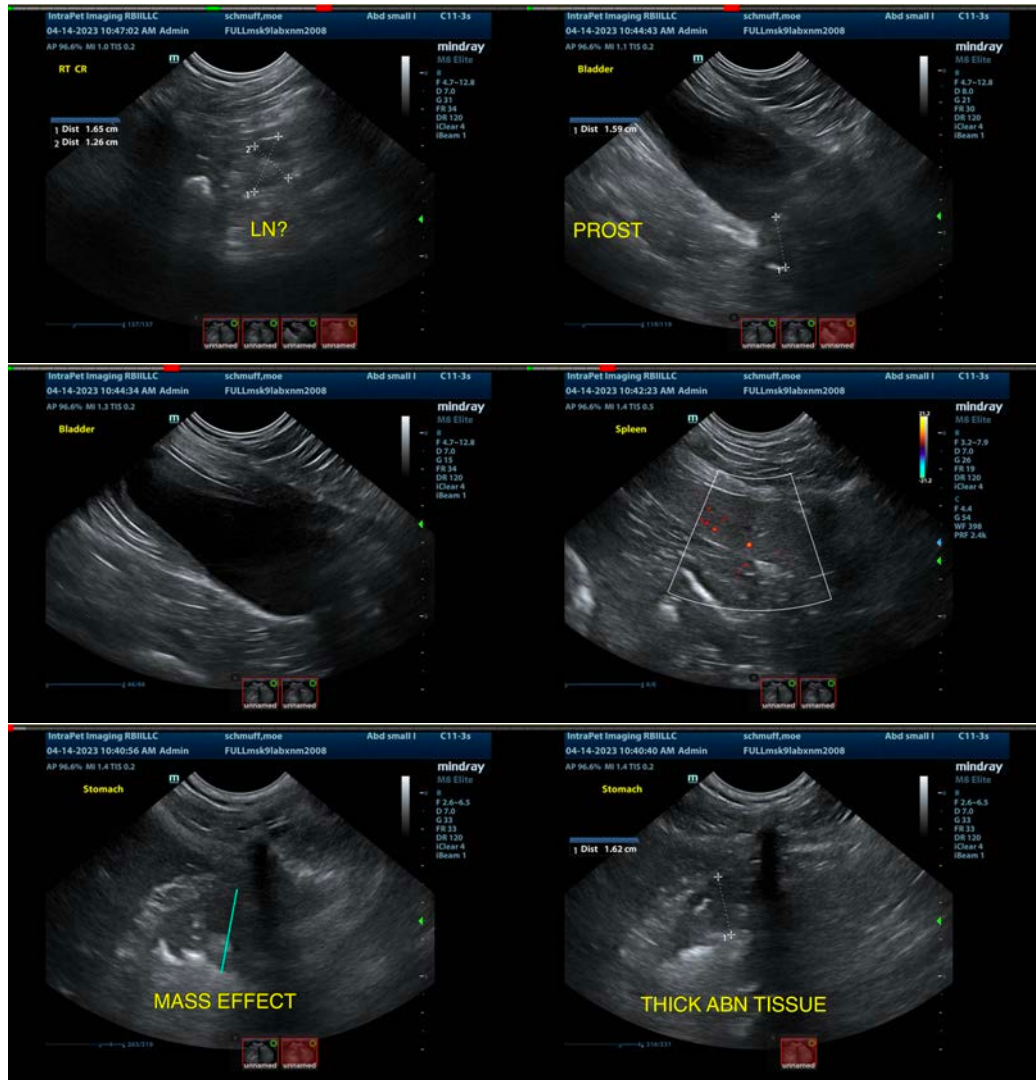
INTERPRETATION OF THE FINDINGS & FURTHER RECOMMENDATIONS

The gastric wall appears to have a focal lesion, which is very irregular with complete loss of wall layering. Findings are most concerning for a gastric mass effect. If a window can be obtained for a fine needle aspirate, this could be considered. If not, consider upper GI endoscopy to try to further characterize and obtain biopsy

samples. The exact location and extent of this lesion is difficult to say, but there is concern that it involves the pyloric region and is fairly extensive. Additionally, a contrast CT scan could be considered prior to surgery if this is desired, or visual evaluation and biopsy at the time of surgery with the knowledge that this may not be resectable.

Recommend three view thoracic radiographs to evaluate for possible concurrent thoracic disease/involvement.





The information and recommendations provided are based on the images presented by the referring veterinarian/sonographer. No evaluation can be communicated regarding pathology that was not visible in the image/video clips provided.

Thank you for this referral. If the clinical or image interpretation does not parallel your findings or if I can be of any further assistance please contact me.

Kathleen Sennello DVM,MS, Diplomate ACVIM (Small animal Internal Medicine)
 kathleen.sennello@sonopath.com