



**DATE PRESENTING CLINICAL SIGNS**

4/14/22 Pt presents for back pain but has low T4 and ALP 1200, increased cholesterol. O elects to workup ALP-Cushing's vs primary liver vs other. Recommended ultrasound prior to LDDS testing.

**PATIENT**

King Moulden  
Current Medications: Carprofen 18mg BID, Gabapentin 100mg BID.  
Lab Results: Low T4, ALP 1200, increased cholesterol.  
Date of Previous IntraPet Ultrasound: No previous.  
Sedation: Not required to complete full diagnostic ultrasound.  
Stat Report: Not requested.

**SPECIES**

Canine

**ULTRASONOGRAPHIC EXAMINATION OF THE ABDOMEN**

**BREED**

Yorkshire Terrier

**Urinary System**

The urinary bladder is moderately distended with anechoic urine. The Bladder wall, trigone, ureteral papillae and visible urethra (to a depth of 2cm) appear normal with no evidence of wall thickening, mucosal irregularities, masses or cystic calculi.

**SEX**

Neutered Male

The prostate is normal in size (0.82 cm) and shape for this neutered male dog. The parenchyma is homogenous and the external margins are smooth. A small 0.17 cm pinpoint mineralization is visualized within the parenchyma. The prostatic urethra appears normal with no evidence of irregularity, invasion, mass effect or calculi.

**AGE**

7/18/10

The left kidney has a normal shape and size (4.99 cm). Overall echogenicity is slightly hyperechoic with poor corticomedullary distinction and a typical 1:3 cortex:medulla ratio. There is no evidence of perinephric inflammation or effusion. There is no evidence of pyelectasia, nephroliths, infarcts or hydroureter. Renal vasculature is normal.

**WEIGHT**

20.4 Pounds

The right kidney has a normal shape and size (4.7 cm). Overall echogenicity is slightly hyperechoic with poor corticomedullary distinction and a typical 1:3 cortex:medulla ratio. There is no evidence of perinephric inflammation or effusion. There is no evidence of pyelectasia, nephroliths, infarcts or hydroureter. Renal vasculature is normal.

**INTERPRETED BY**

Kathleen Sennello DVM,  
MS, Diplomate ACVIM  
(Small Animal Internal  
Medicine)

**Adrenal Glands**

The left adrenal gland is borderline large in size measuring 0.87 cm at the cranial pole, 0.82 cm at the caudal pole, and 2.19 cm in length. It is observed in its normal position cranial to the left renal artery. It is normal in appearance (uniformly hypoechoic) and shape with no evidence of a mass effect.

**IMAGING PERFORMED BY**

Andi Parkinson RDMS

The right adrenal gland is large in size measuring 1.03 cm at the cranial pole, 0.72 cm at the caudal pole, and 2.02 cm in length. It is observed in its normal position between the cranial aspect of the right kidney and the caudal vena cava. It is somewhat irregular in appearance in that there is a patchy, hyperechoic region within the mid body of the gland, measuring 1.07 cm x 0.71 cm. This does not appear to significantly deform the margins of the adrenal gland.

**HOSPITAL NAME**

Everhart Vet Hospital

**REFERRING VET**

Dr. Rubinstein

**Spleen**

The spleen is subjectively normal in size, echotexture is homogenous, and the splenic capsule is smooth with no irregularities. The blood flow through the hilus and splenic parenchyma appears normal. No focal parenchymal abnormalities are visualized.

**INVOICE**

36897

**Liver**

The liver is subjectively normal in size, and echogenicity with smooth peripheral margins. The parenchyma is heterogenous in echotexture with subtle, indistinct focal mottling. The visible portions of the vasculature and biliary tract appear normal. No focal nodules or cystic lesions are observed.

The gall bladder lumen is significantly distended. Some areas of the wall appear mildly thickened with adherent debris. There is a large amount of primarily non-organized echogenic debris. A portion of this debris is starting to form some striations, most consistent with an early mucocele. There is no evidence of bile duct dilation. These changes can be consistent with an early gall bladder mucocele.

### ***Gastrointestinal***

The stomach contains minimal luminal contents. It measures at a normal thickness of <0.7cm with some variability due to the presence of rugal folds. The distinction of the gastric wall layers is adequate and there is no impression of reduced peristaltic activity. No masses or focal lesions were observed.

The visualized areas of duodenum, jejunum and ileum have a relatively uniform diameter with minimal fluid distension. Wall thickness is normal. Bowel loops follow a curvilinear path with distinct wall layering maintaining the typical 1:3 muscularis:mucosa layer ratio. The duodenum measured as normal (between 0.3-0.5cm in wall thickness) and the jejunum measured as normal (between 0.2-0.47cm.) Visualized peristalsis appears appropriate. There were no focal lesions consistent with obstruction or a mass effect observed.

The ileocecal junction was visualized and exhibited normal intact wall layering and is subjectively of normal thickness. Sections of colon are visualized with formed fecal material and gas shadowing distally. There is no observed focal or generalized colon wall thickening or loss of layering.

### ***Pancreas***

The pancreas is normal and isoechoic to surrounding mesentery. There is no evidence of nodules or cystic lesions. There is no evidence of regional mesenteric inflammation or fluid.

### ***Free Abdomen***

Evaluation of the peritoneal cavity did not reveal any evidence of effusion, or subjective lymphadenomegaly. The Medial iliac nodes appear normal and there was no evidence of a caudal aortic thrombus at the bifurcation. The omentum is of normal uniform echogenicity.

## **PRIMARY FINDINGS**

- Borderline bilateral adrenomegaly with a slightly irregular right adrenal gland – The bilateral adrenomegaly could be consistent with bilateral hyperplasia (e.g., secondary to pituitary-dependent hyperadrenocorticism), bilateral infiltrative neoplasia, inflammatory adrenal disease, other. Correlation with clinical findings is recommended. The significance of the irregular hyperechoic region on the right adrenal gland is unknown. Recommend continued monitoring.
- Heterogeneous liver – The diffuse hepatic changes are non-specific and could be consistent with vacuolar hepatopathy, nodular hyperplasia, inflammatory/immune-mediated disease, fibrosis, extramedullary hematopoiesis, toxic hepatopathy (e.g., copper), infiltrative neoplasia (less likely) or other hepatopathy.
- Large amount of debris within the gallbladder lumen with early organization – most consistent with early mucocele development. Recommend starting Ursodiol and continued monitoring.

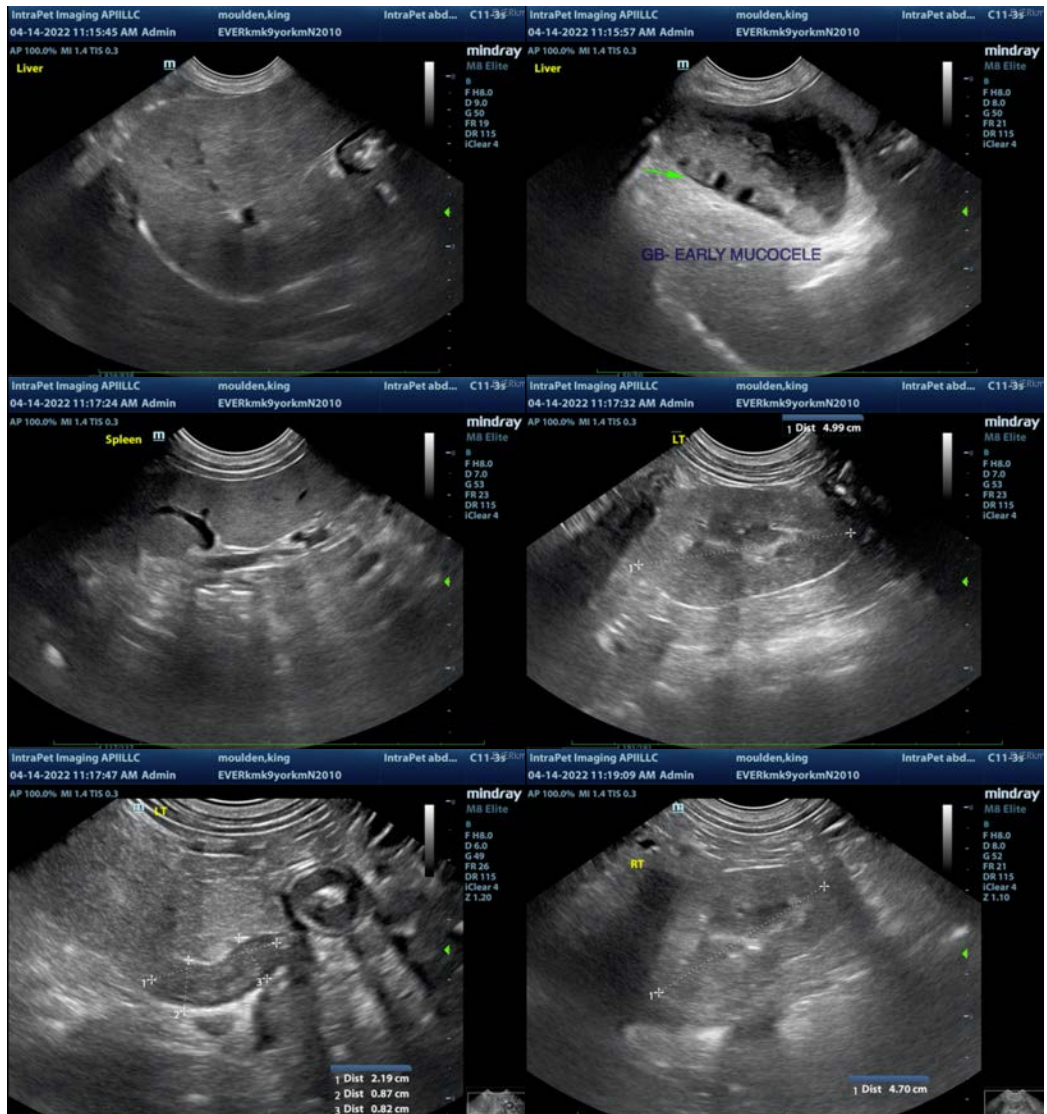
## **SECONDARY FINDINGS**

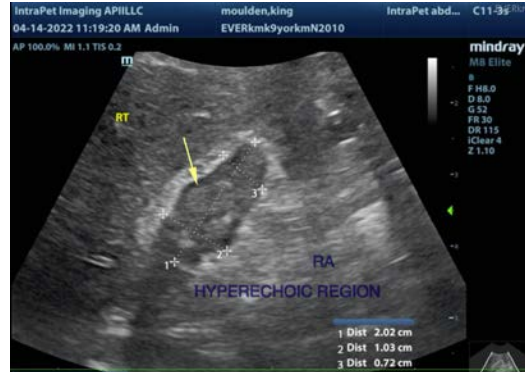- Small pinpoint mineralization within the prostatic parenchyma – This is likely an incidental finding, but continued monitoring is warranted.
- Decreased corticomedullary distinction in both kidneys – The bilateral renal findings are consistent with age-related change.

## INTERPRETATION OF THE FINDINGS & FURTHER RECOMMENDATIONS

The liver is large and somewhat heterogeneous, but there are no focal lesions visualized. There is an early mucocele developing. This does not appear overtly inflamed, but consider starting Ursodiol with close continued monitoring +/- antibiotics, as this could develop into a surgical lesion in the future.

Both adrenal glands appear somewhat large for a small dog. Additionally, the right adrenal gland has an irregularity. Correlate this with clinical signs. If symptoms of Cushing's are present, I would consider testing (I would not test while experiencing back pain, as this could cause false positives), and I recommend continued monitoring of the right adrenal gland for development of a mass effect. Additionally, a blood pressure evaluation is warranted.





The information and recommendations provided are based on the images presented by the referring veterinarian/sonographer. No evaluation can be communicated regarding pathology that was not visible in the image/video clips provided.

Thank you for this referral. If the clinical or image interpretation does not parallel your findings or if I can be of any further assistance please contact me.

Kathleen Sennello DVM,MS, Diplomate ACVIM (Small animal Internal Medicine)  
kathleen.sennello@sonopath.com