

**DATE PRESENTING CLINICAL SIGNS**

4/13/23

3/8/23 - Presented for ADR. Has been lethargic for about a week and has decreased appetite for about a week as well (only eating about a quarter of what he normally does). Littermate passed away in nov 2019 from congenital heart disease at 2. P is using litterbox normally. O noticed weight loss as well due to not eating. On Saturday patient noticed a change in purr - almost as if he had a whistle stuck in throat. P started on mirtaz but not having improvement.

**PATIENT**

Two Bit Hershberger

**SPECIES**

Feline

Current Medications: Mirtazapine 15mg Tablet Give 1/4 tablet by mouth every 72 hours as needed for appetite. Started 3/9/23

Lab Results: AST and ALP - slightly decreased. U/A - 2+ protein

Date of Previous IntraPet Ultrasound: No previous.

Sedation: Not required to complete full diagnostic ultrasound.

Stat Report: Not requested.

Imaging Performed By: Rachel Brillhart, RDMS.

**BREED**

DSH

**SEX**

Neutered Male

**ULTRASONOGRAPHIC EXAMINATION OF THE ABDOMEN****Urinary System**

The urinary bladder is moderately distended with anechoic urine. The Bladder wall, trigone, ureteral papillae and visible urethra (to a depth of 2cm) appear normal with no evidence of wall thickening, mucosal irregularities, masses or cystic calculi.

**AGE**

2/1/17

The left kidney has a normal shape and size (3.72 cm). Overall echogenicity is normal with adequate corticomedullary distinction and a typical 1:3 cortex:medulla ratio. There is no evidence of focal perinephric inflammation or effusion. There is no evidence of pyelectasia, nephroliths, infarcts or hydroureter. Renal vasculature is normal.

**WEIGHT**

7.9 Pounds

The right kidney has a normal shape and size (3.53 cm). Overall echogenicity is normal with adequate corticomedullary distinction and a typical 1:3 cortex:medulla ratio. There is no evidence of focal perinephric inflammation or effusion. There is no evidence of pyelectasia, nephroliths, infarcts or hydroureter. Renal vasculature is normal.

**INTERPRETED BY**

Kathleen Sennello DVM,  
MS, Diplomate ACVIM  
(Small Animal Internal  
Medicine)

**Adrenal Glands**

The left adrenal gland is normal in size measuring 0.43 cm at the caudal pole. It is observed in its normal position cranial to the left renal artery. It is normal in appearance (uniformly hypoechoic) and shape with no evidence of a mass effect.

**HOSPITAL NAME**

Warm &amp; Fuzzy VC

**REFERRING VET**

Dr. Weber

The right adrenal gland is normal in size measuring 0.41 cm at the caudal pole. It is observed in its normal position between the cranial aspect of the right kidney and the caudal vena cava. It is normal in appearance (uniformly hypoechoic) and shape with no evidence of a mass effect.

**INVOICE**

46655

**Spleen**

The spleen is subjectively normal in size (0.90 cm at the hilus), echotexture is homogenous, and the splenic capsule is smooth with no irregularities. The blood flow through the hilus and splenic parenchyma appears normal. No focal parenchymal abnormalities are visualized.

**Liver**

The liver is subjectively normal in size, and echogenicity with smooth peripheral margins. The parenchyma is homogenous echotexture. The visible portions of the vasculature and biliary tract appear normal. No focal nodules or cystic lesions are observed.

The gallbladder lumen is moderately distended. The wall of the gall bladder is not thickened and has a smooth mucosal surface. Luminal contents are mild and primarily anechoic. The cystic and common bile ducts are normal/not visible.

### ***Gastrointestinal***

The stomach contains minimal luminal contents. It measures at a normal thickness of <0.36cm with some variability due to the presence of rugal folds. The distinction of the gastric wall layers is adequate and there is no impression of reduced peristaltic activity. No masses or focal lesions were observed.

The visualized areas of duodenum, jejunum and ileum have a relatively uniform diameter with minimal fluid distension. Wall thickness is normal. Bowel loops follow a curvilinear path with distinct wall layering maintaining the typical 1:3 muscularis:mucosa layer ratio. The duodenum measured as normal (between 0.13-0.38cm in wall thickness) and the jejunum measured as normal (between 0.15-0.36cm.) Visualized peristalsis appears appropriate. There were no focal lesions consistent with obstruction or a mass effect observed.

The ileocecal junction was visualized and exhibited normal intact wall layering and is subjectively of normal thickness. Sections of colon are visualized with formed fecal material and gas shadowing distally. There is no observed focal or generalized colon wall thickening or loss of layering.

### ***Pancreas***

The pancreas is prominent and hypoechoic as compared to the surrounding isoechoic mesentery. There is a large, hypoechoic, almost bilobed mass effect visualized dorsal to the stomach in the region of the left limb of the pancreas. Hypoechoic, somewhat normal appearing pancreas appears to be coalescing into a large, hypoechoic mass effect measuring 5.24 cm x 3.69 cm. An adhered lymph node/cranial abdominal mass cannot be ruled out. There is no evidence of regional mesenteric inflammation or fluid. Slightly prominent pancreatic duct noted.

### ***Free Abdomen***

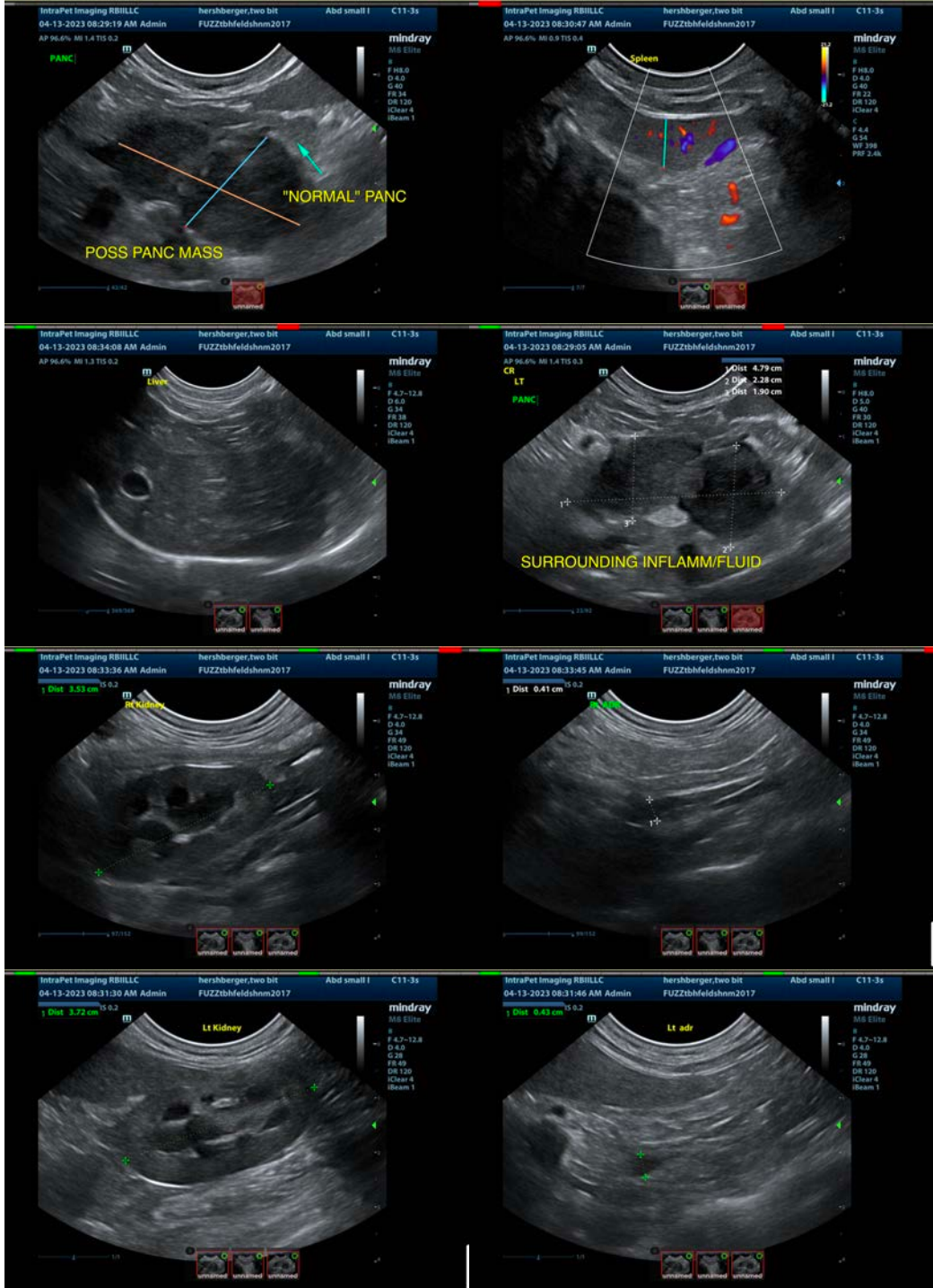
There is scant free fluid surrounding the cranial abdominal mass. There is a prominent lymph node adjacent to the mass effect measuring 0.62 cm. The omentum is hyperechoic around the cranial abdominal mass.

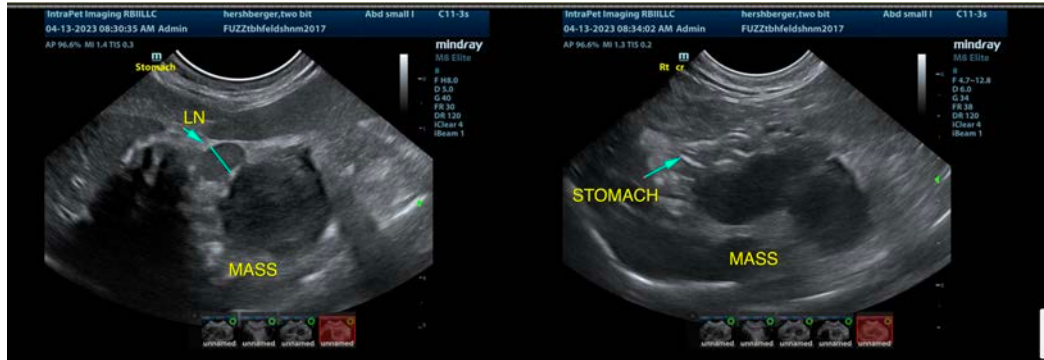
## **ULTRASONOGRAPHIC FINDINGS**

- Large, hypoechoic, bilobed, inflamed cranial abdominal mass – The mass appears associated with the pancreas. An adhered lymph node cannot be ruled out.
- Cranial mesenteric lymphadenopathy – The prominent abdominal lymph nodes are most consistent with reactive lymphadenitis or lymphoid hyperplasia. Neoplastic infiltration is considered less likely.

## **INTERPRETATION OF THE FINDINGS & FURTHER RECOMMENDATIONS**

There is a large cranial abdominal mass that appears intimately associated with the pancreas. Recommend a fine needle aspirate of this mass lesion for cytologic evaluation as well as 3-view thoracic radiographs. If a cytologic diagnosis cannot be obtained based on an aspirate, surgical biopsies would likely be necessary. Concern is high for a neoplastic process associated with the pancreas (carcinoma, lymphoma, insulinoma, other).





The information and recommendations provided are based on the images presented by the referring veterinarian/sonographer. No evaluation can be communicated regarding pathology that was not visible in the image/video clips provided.

Thank you for this referral. If the clinical or image interpretation does not parallel your findings or if I can be of any further assistance please contact me.

Kathleen Sennello DVM,MS, Diplomate ACVIM (Small animal Internal Medicine)  
kathleen.sennello@sonopath.com