

**DATE PRESENTING CLINICAL SIGNS**

4/13/23

Seen rDVM 4/10 Vomiting started on Sunday then progressed into diarrhea. Was outside in yard on Saturday - no known toxic or foreign ingestions. No diet changes - gets mix of wet and dry Does get pupperoni as treats. BW ALKP 416 Amylase 208 CBC Monocytosis Eosinopenia Neutrophils - bands X-rays performed - small amount of gas. Started with outpatient therapy SQ fluids Injectable Cerenia Dispensed - Metronidazole and Famotidine Today rechecked - dripping diarrhea. Repeat X-rays: Stomach gas dilated and fluid & gas pattern small intestines. Referral for continued care. History of bladder stones in past - were surgically removed. History of umbilical hernia.

PATIENT

Summer Spilman

SPECIES

Canine

Current Medications: Ondansetron, Provable, Metronidazole, Metoclopramide, Ampicillin, Protonix.
Lab Results: See attached.

BREED

Shih Tzu

Date of Previous IntraPet Ultrasound: No previous.
Sedation: Not required to complete full diagnostic ultrasound.
Stat Report: Not requested.
Imaging Performed By: Rachel Brillhart, RDMS.

SEX

Spayed Female

ULTRASONOGRAPHIC EXAMINATION OF THE ABDOMEN**AGE**

4/11/12

Urinary System

The urinary bladder is moderately distended with anechoic urine. The Bladder wall, trigone, ureteral papillae and visible urethra (to a depth of 2cm) appear normal with no evidence of wall thickening, mucosal irregularities, masses or cystic calculi.

WEIGHT

11.5 Pounds

The left kidney has a normal shape and size (4.2 cm). Overall echogenicity is normal with adequate corticomedullary distinction and a typical 1:3 cortex:medulla ratio. There is no evidence of focal perinephric inflammation or effusion. There is no evidence of pyelectasia, nephroliths, infarcts or hydroureter. Renal vasculature is normal.

INTERPRETED BY

Kathleen Sennello DVM,
MS, Diplomate ACVIM
(Small Animal Internal
Medicine)

The right kidney has a normal shape and size (4.25 cm). Overall echogenicity is normal with adequate corticomedullary distinction and a typical 1:3 cortex:medulla ratio. There is no evidence of focal perinephric inflammation or effusion. There is no evidence of pyelectasia, nephroliths, infarcts or hydroureter. Renal vasculature is normal.

HOSPITAL NAME

Animal Emergency
Hospital

Adrenal Glands

The left adrenal gland is normal in size measuring 0.42 cm at the caudal pole. It is observed in its normal position cranial to the left renal artery. It is normal in appearance (uniformly hypoechoic) and shape with no evidence of a mass effect.

REFERRING VET

Dr. Saubier

The right adrenal gland is normal in size measuring 0.59 cm at the caudal pole. It is observed in its normal position between the cranial aspect of the right kidney and the caudal vena cava. It is normal in appearance (uniformly hypoechoic) and shape with no evidence of a mass effect.

INVOICE

46650

Spleen

The spleen is subjectively normal in size, echotexture is homogenous, and the splenic capsule is smooth with no irregularities. The blood flow through the hilus and splenic parenchyma appears normal. No focal parenchymal abnormalities are visualized.

Liver

The liver is subjectively normal in size, and echogenicity with smooth peripheral margins. The parenchyma is mildly heterogenous in echotexture with subtle, indistinct focal mottling. The visible portions of the vasculature and biliary tract appear normal. No focal nodules or cystic lesions are observed.

The gall bladder lumen is moderately distended. The wall of the gall bladder is not thickened and has a smooth mucosal surface. There is a moderate amount of non-organized echogenic debris. The cystic and common bile ducts are normal/not visible. There is mild surrounding inflammation visualized near the gallbladder.

Gastrointestinal

The stomach contains minimal luminal contents. It measures at a normal thickness of <0.7cm with some variability due to the presence of rugal folds. The distinction of the gastric wall layers is adequate and there is no impression of reduced peristaltic activity. No masses or focal lesions were observed.

The visualized areas of duodenum, jejunum and ileum have a relatively uniform diameter with minimal fluid distension. Wall thickness is normal. Bowel loops follow a curvilinear path with distinct wall layering maintaining the typical 1:3 muscularis:mucosa layer ratio. Duodenum wall measures 0.31 cm. Jejunum wall measures 0.27 cm. Visualized peristalsis appears appropriate. There were no focal lesions consistent with obstruction or a mass effect observed.

The ileocecal junction was visualized and exhibited normal intact wall layering and is subjectively of normal thickness. Nonformed fecal material is present in the colon. There is no observed focal or generalized colon wall thickening or loss of layering.

Pancreas

The right limb of the pancreas is large and hypoechoic to surrounding mesentery. There is no evidence of nodules or cystic lesions. There is evidence of regional mesenteric inflammation. Consistent with mild pancreatitis.

Free Abdomen

Evaluation of the peritoneal cavity did not reveal any evidence of effusion, or subjective lymphadenomegaly. The Medial iliac nodes appear normal and there was no evidence of a caudal aortic thrombus at the bifurcation. The omentum appears mildly hyperechoic around the right limb of the pancreas.

ULTRASONOGRAPHIC FINDINGS

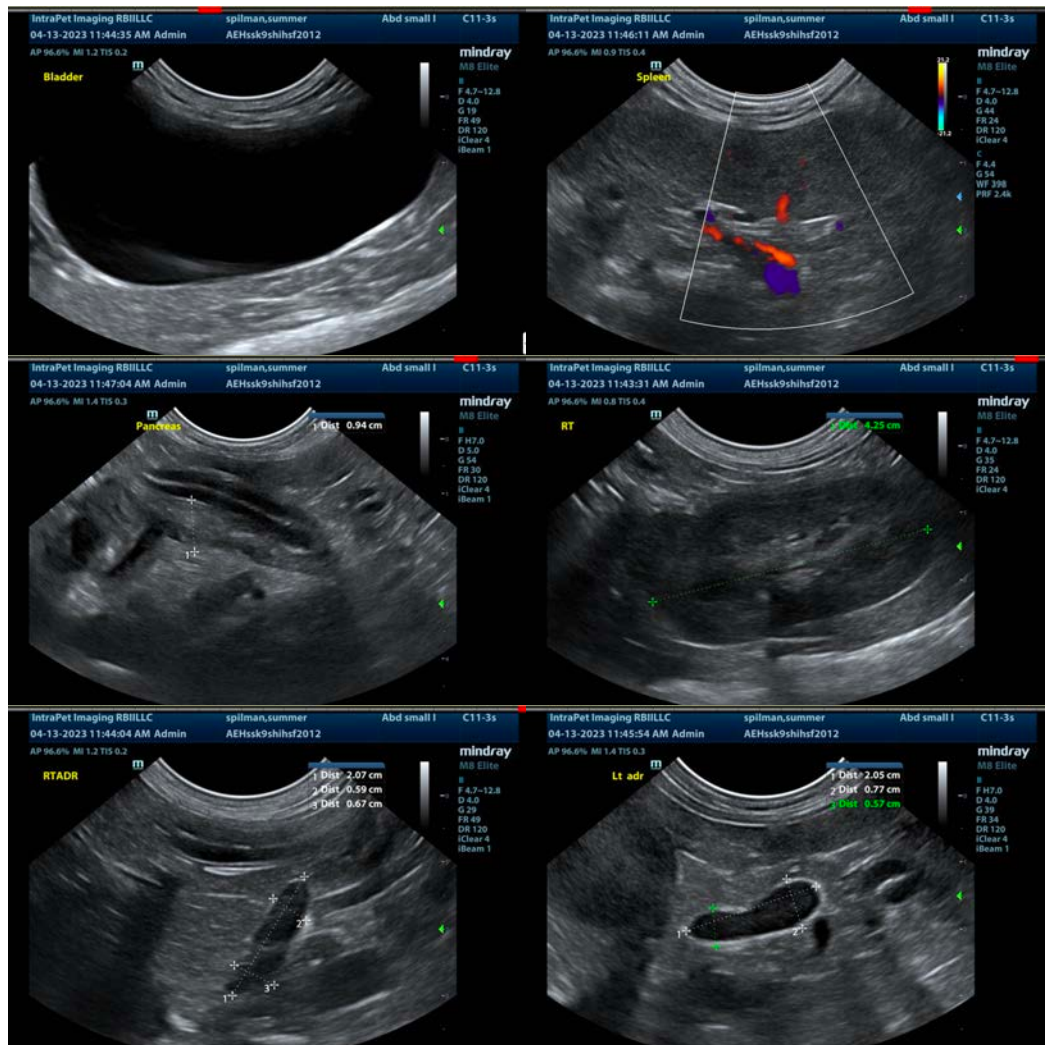
- Prominent, slightly hypoechoic pancreas with mildly hyperechoic surrounding mesentery – The pancreatic changes are most consistent with mild pancreatitis/pancreatic inflammation. Recommend fPLI testing and continued monitoring for improvement or possible development of a pancreatic abscess. Consider fine needle aspirate if not improving.
- Mildly heterogeneous liver – The diffuse hepatic changes are non-specific and could be consistent with vacuolar hepatopathy, nodular hyperplasia, inflammatory/immune-mediated disease, fibrosis, extramedullary hematopoiesis, toxic hepatopathy (e.g., copper), infiltrative neoplasia (less likely) or other hepatopathy.
- Moderate gallbladder debris with mild surrounding inflammation – The significance of the aggregated gallbladder debris is unclear. This could represent an early mucocele, cholestasis, or may be secondary to fasting but seems unlikely to be causing a current issue. Recommend continued monitoring.

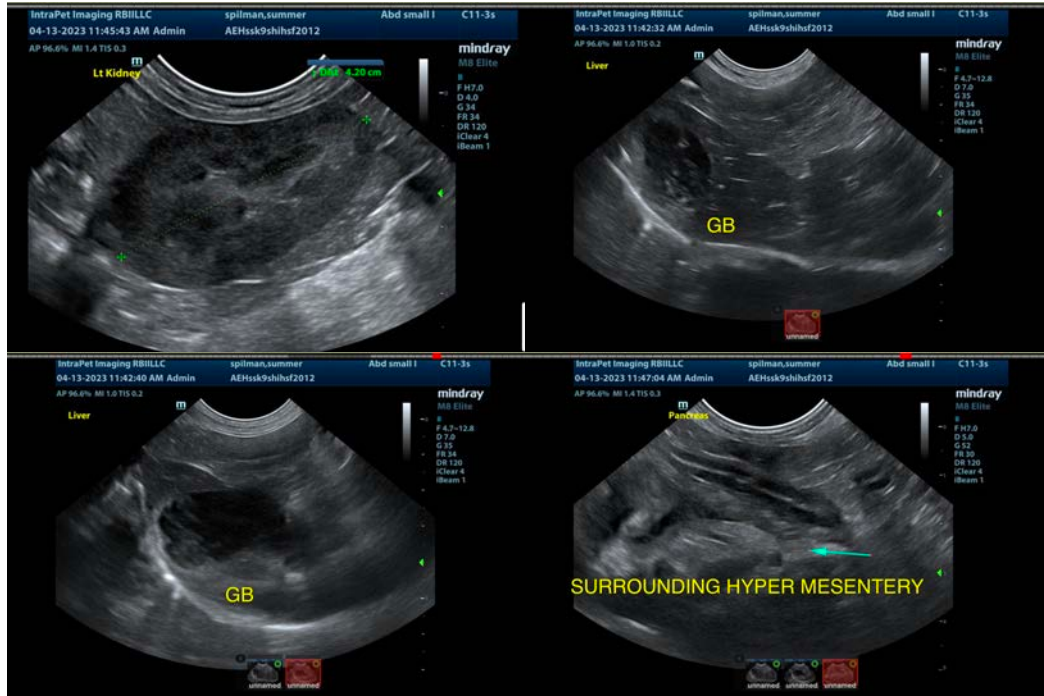
INTERPRETATION OF THE FINDINGS & FURTHER RECOMMENDATIONS

Based on today's exam, the pancreas appears somewhat prominent. Additionally, the gallbladder has moderate debris and possible mild surrounding inflammation. The liver is heterogeneous, which is a non-specific finding, but could be consistent with a vacuolar hepatopathy, less likely neoplastic change, etc. Consider treatment for acute gastroenteritis/pancreatitis. Additionally, consider the following:

- Consider a novel protein/hydrolyzed protein diet (exclusively at least 4-6 weeks)
- Consider a GI panel to Texas A&M for evaluation of B12 levels, folate, PLI/TLI etc.. to further evaluate for pancreatic/small intestinal disease.
- Recommend parasite screening and empirical therapy.
- Recommend chronic probiotic therapy.
- Recommend treatment for pancreatitis with pain medications, nausea medications, IV fluids as needed, etc.

Additionally, you could consider treatment for possible cholecystitis with antibiotics and Ursodiol. If the ALP or bilirubin continues to rise, consider reimaging of this area with ultrasound. If liver enzyme elevations persist and/or increase, you could consider a fine needle aspirate of the liver (provided coagulation parameters are normal).





The information and recommendations provided are based on the images presented by the referring veterinarian/sonographer. No evaluation can be communicated regarding pathology that was not visible in the image/video clips provided.

Thank you for this referral. If the clinical or image interpretation does not parallel your findings or if I can be of any further assistance please contact me.

Kathleen Sennello DVM,MS, Diplomate ACVIM (Small animal Internal Medicine)
kathleen.sennello@sonopath.com