



PATIENT

Saundra Flynn

SPECIES

Canine

BREED

Labrador

SEX

Spayed Female

AGE

13 Years

WEIGHT

53.4 Pounds

INTERPRETED BY

Kathleen Sennello DVM,
MS, Diplomate ACVIM
(Small Animal Internal
Medicine)

IMAGING PERFORMED BY

Dr. Emily Kirk

HOSPITAL NAME

Shiloh Animal Hospital

REFERRING VET

Dr. Emily Kirk

INVOICE

46673

DATE

4/13/23

PRESENTING CLINICAL SIGNS

Presented to another veterinary office about one month ago. At that time patient had started vomiting, stools seemed dark and urine appeared to have blood as well. UA showed > 50 wbc and rbc with suspect cocci present on automated analyzer. Lateral x-ray of abdomen unremarkable. HCT 32 with regenerative response. Treated with Clavamox and famotidine. Continued to have vomiting with evidence of blood. Repeated lateral x-ray of abdomen did not show any changes. Treated with sucralfate, famotidine, omeprazole and bland diet. Symptoms have continued and patient is losing weight.

Abnormal PE/Chem/CBC/UA Results: Regenerative anemia

ULTRASONOGRAPHIC EXAMINATION OF THE ABDOMEN

Urinary System

The urinary bladder is moderately distended with anechoic urine. The Bladder wall, trigone, ureteral papillae and visible urethra (to a depth of 2cm) appear normal with no evidence of wall thickening, mucosal irregularities, masses or cystic calculi.

The left kidney has a normal shape and size (5.59 cm). Overall echogenicity is normal with adequate corticomedullary distinction and a typical 1:3 cortex:medulla ratio. There is no evidence of focal perinephric inflammation or effusion. There is no evidence of pyelectasia, nephroliths, infarcts or hydroureter. Renal vasculature is normal.

The right kidney has a normal shape and size (5.35 cm) with mild pyelectasia at 0.32 cm. Overall echogenicity is normal with adequate corticomedullary distinction and a typical 1:3 cortex:medulla ratio. There is no evidence of focal perinephric inflammation or effusion. There is no evidence of nephroliths, infarcts or hydroureter. Renal vasculature is normal.

Adrenal Glands

The left adrenal gland is large and irregular, measuring 0.71 cm at the cranial pole, 1.55 cm at the caudal pole, and 3.15 cm in length. It is observed in its normal position cranial to the left renal artery. It is abnormal in appearance in that the caudal pole is rounded and enlarged. There is no evidence of vascular invasion visualized.

The region of the right adrenal (between right cranial kidney and vena cava) is unremarkable, but the adrenal is not distinctly visualized. No evidence of a mass effect is visualized.

Spleen

The spleen is subjectively normal in size but slightly irregular in shape. The blood flow through the hilus and splenic parenchyma appears normal. A mixed echogenic splenic mass is visualized bulging from the capsule, measuring 1.86 cm x 2.11 cm.

Liver

The liver is subjectively normal in size, and echogenicity with smooth peripheral margins. The parenchyma is heterogenous in echotexture with subtle, indistinct focal mottling. The visible portions of the vasculature and biliary tract appear normal. There is a small 0.74 cm cystic structure visualized.

The gall bladder lumen is significantly distended. Some areas of the wall appear mildly thickened with adherent debris. There is a large amount of primarily non-organized echogenic debris. There is no evidence of bile duct dilation.



PATIENT

Sandra Flynn

SPECIES

Canine

BREED

Labrador

SEX

Spayed Female

AGE

13 Years

WEIGHT

53.4 Pounds

INTERPRETED BY

Kathleen Sennello DVM,
MS, Diplomate ACVIM
(Small Animal Internal
Medicine)

**IMAGING
PERFORMED BY**

Dr. Emily Kirk

HOSPITAL NAME

Shiloh Animal Hospital

REFERRING VET

Dr. Emily Kirk

INVOICE

46673

DATE

4/13/23

Gastrointestinal

The stomach is mildly distended with a small amount of fluid and gas. The stomach wall largely appears relatively normal with intact wall layering and measures at a normal thickness (<0.70 cm). In other areas, I am able to definitively discern the gastric wall, and suspect it is severely thickened with loss of layering and atypical heterogeneous tissue in some regions. There is an abnormal area measuring approximately 2.76 cm. The gastric wall measures at 1.5 cm.

The visualized areas of duodenum, jejunum and ileum have a relatively uniform diameter with minimal fluid distension. Wall thickness is normal. Bowel loops follow a curvilinear path with distinct wall layering maintaining the typical 1:3 muscularis:mucosa layer ratio. Duodenum wall measures 0.41 cm. Jejunum wall measures 0.34 cm. Visualized peristalsis appears appropriate. There were no focal lesions consistent with obstruction or a mass effect observed.

The ileocecal junction was visualized and exhibited normal intact wall layering and is subjectively of normal thickness. Sections of colon are visualized with formed fecal material and gas shadowing distally. There is no observed focal or generalized colon wall thickening or loss of layering.

Pancreas

The pancreas is normal and isoechoic to surrounding mesentery. There is no evidence of nodules or cystic lesions. There is no evidence of regional mesenteric inflammation or fluid.

Free Abdomen

Evaluation of the peritoneal cavity did not reveal any evidence of effusion, or subjective lymphadenomegaly. The Medial iliac nodes appear normal and there was no evidence of a caudal aortic thrombus at the bifurcation. The omentum is of normal uniform echogenicity.

ULTRASONOGRAPHIC FINDINGS

- Large caudal pole of the left adrenal – Adrenomegaly could be consistent with neoplasia (e.g., adenoma, carcinoma, pheochromocytoma), hyperplasia, inflammation, other.
- Mixed echogenic splenic mass visualized – A focal solid mixed echogenicity mass is visualized associate with the spleen. This mass distorts the splenic capsule. Differentials include : benign lesions (lymphoid hyperplasia, hemangioma etc..) or cancerous lesions (hemangiosarcoma, lymphoma, histocytic sarcoma etc..)
- Heterogeneous liver – The diffuse hepatic changes are non-specific and could be consistent with vacuolar hepatopathy, nodular hyperplasia, inflammatory/immune-mediated disease, fibrosis, extramedullary hematopoiesis, toxic hepatopathy (e.g., copper), infiltrative neoplasia (less likely) or other hepatopathy.
- Thickened irregular gastric wall – Findings are concerning for a possible gastric wall mass (adenoma, carcinoma, round cell neoplasia, etc), although embedded foreign material, severe focal inflammation, ulceration, etc. are possible.
- Large gallbladder debris – The significance of the aggregated gallbladder debris is unclear. This could represent an early mucocele, cholestasis, or may be secondary to fasting but seems unlikely to be causing a current issue. Recommend continued monitoring.



PATIENT

Sandra Flynn

SPECIES

Canine

BREED

Labrador

SEX

Spayed Female

AGE

13 Years

WEIGHT

53.4 Pounds

INTERPRETED BY

Kathleen Sennello DVM,
MS, Diplomate ACVIM
(Small Animal Internal
Medicine)

IMAGING PERFORMED BY

Dr. Emily Kirk

HOSPITAL NAME

Shiloh Animal Hospital

REFERRING VET

Dr. Emily Kirk

INVOICE

46673

DATE

4/13/23

INTERPRETATION OF THE FINDINGS & FURTHER RECOMMENDATIONS

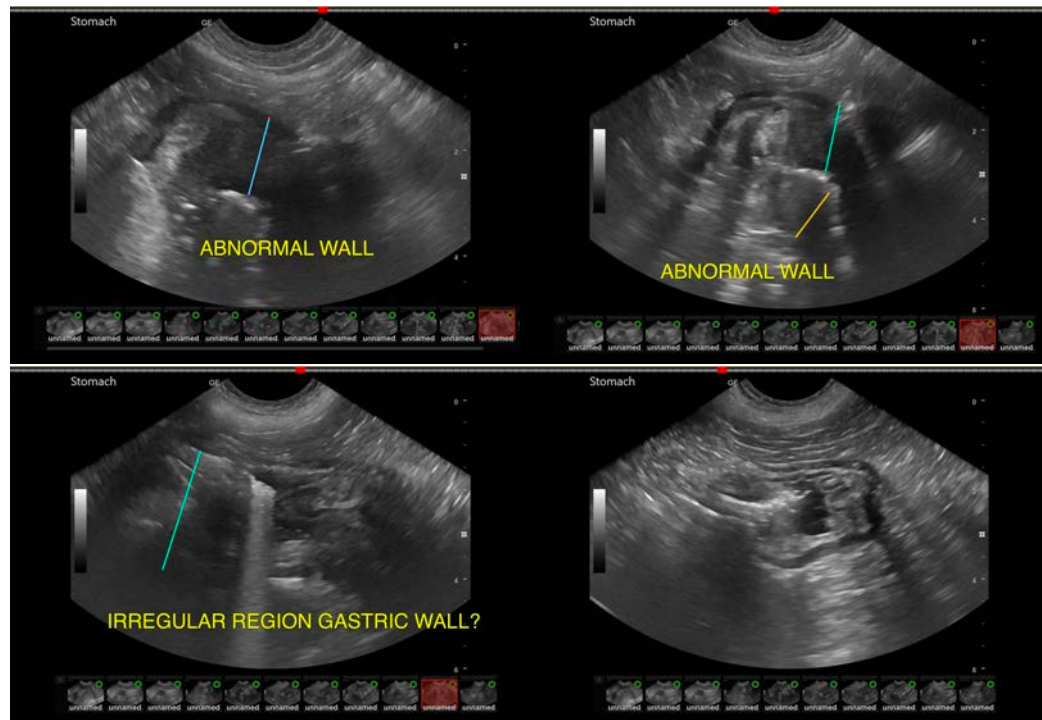
The stomach wall appears abnormal. It is somewhat difficult to clearly visualize due to gas in the stomach and the abnormal architecture, but the gastric wall appears thickened with loss of detail of wall layering. Consider an upper GI endoscopy to further evaluate and obtain biopsies. The exact location and extent of this lesion is difficult to assess. This could represent a neoplastic or benign mass lesion. Additionally, this could represent embedded foreign material, a proliferative ulcer, etc.

The caudal pole of the left adrenal gland appears enlarged. This could represent a benign or neoplastic lesion and could be secreting hormone or be non-active. If signs of Cushing's are present, you could consider adrenal function testing (when the potential lesion is resolved). Additionally, consider a blood pressure evaluation to look for evidence of a pheochromocytoma, and if surgical removal is desired, consider a contrast CT scan, looking for the possibility of vascular invasion.

There is a large amount of debris visualized in the gallbladder. Some of this is adhered to the gallbladder wall with possible mild inflammation. Recommend considering Ursodiol therapy and continuing to monitor the gallbladder with ultrasound.

There is a mixed echogenic mass effect associated with the spleen. Options moving forward would include a fine needle aspirate or splenectomy for both diagnostic and therapeutic purposes.

Recommend three view thoracic radiographs to evaluate for possible concurrent thoracic disease/involvement.





PATIENT

Sandra Flynn

SPECIES

Canine

BREED

Labrador

SEX

Spayed Female

AGE

13 Years

WEIGHT

53.4 Pounds

INTERPRETED BY

Kathleen Sennello DVM,
MS, Diplomate ACVIM
(Small Animal Internal
Medicine)

**IMAGING
PERFORMED BY**

Dr. Emily Kirk

HOSPITAL NAME

Shiloh Animal Hospital

REFERRING VET

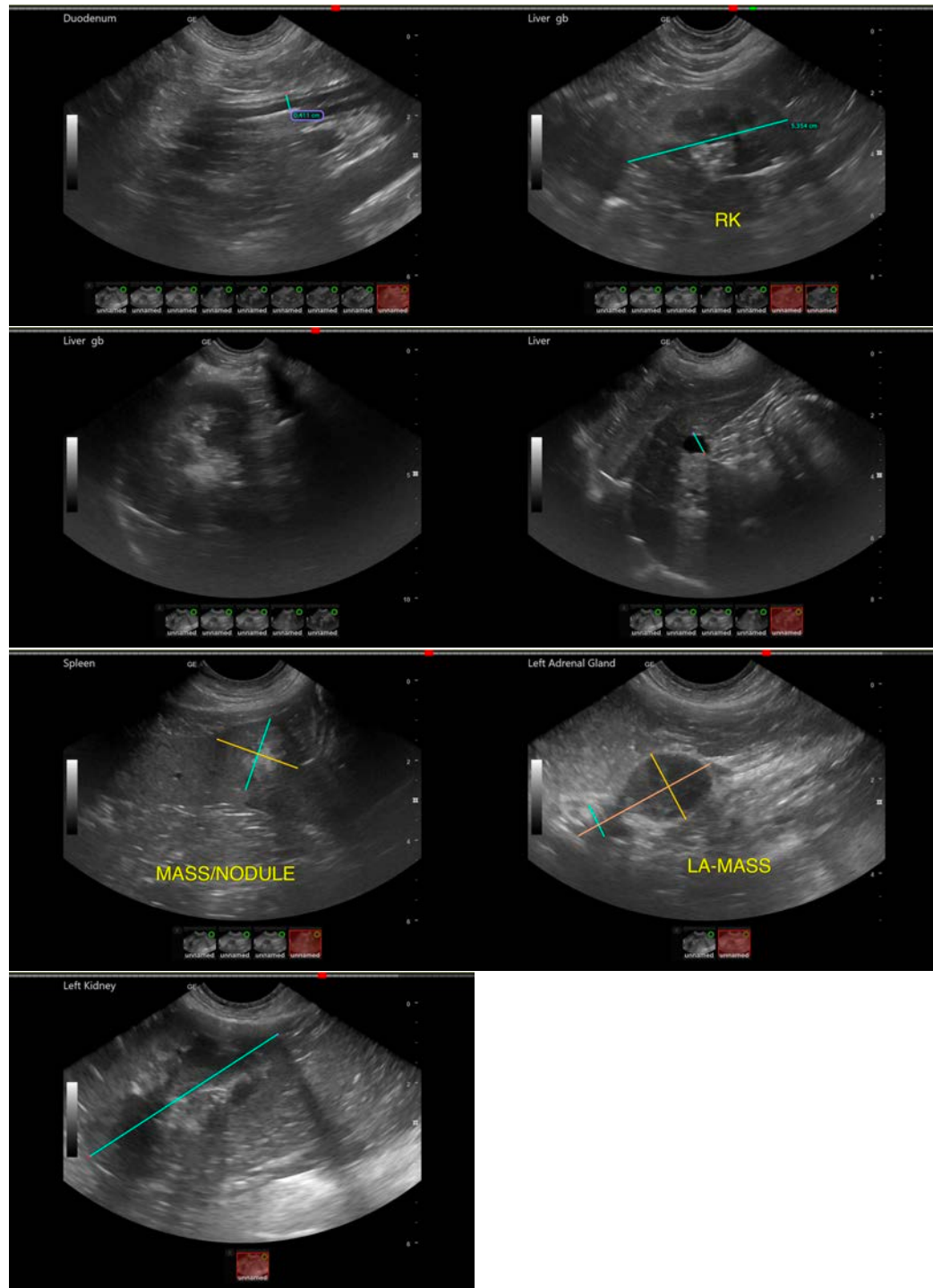
Dr. Emily Kirk

INVOICE

46673

DATE

4/13/23





PATIENT

Sandra Flynn

The information and recommendations provided are based on the images presented by the referring veterinarian/sonographer. No evaluation can be communicated regarding pathology that was not visible in the image/video clips provided.

SPECIES

Canine

Thank you for this referral. If the clinical or image interpretation does not parallel your findings or if I can be of any further assistance please contact me.

BREED

Labrador

Kathleen Sennello DVM,MS, Diplomate ACVIM (Small animal Internal Medicine)

kathleen.sennello@sonopath.com

SEX

Spayed Female

AGE

13 Years

WEIGHT

53.4 Pounds

INTERPRETED BY

Kathleen Sennello DVM,
MS, Diplomate ACVIM
(Small Animal Internal
Medicine)

**IMAGING
PERFORMED BY**

Dr. Emily Kirk

HOSPITAL NAME

Shiloh Animal Hospital

REFERRING VET

Dr. Emily Kirk

INVOICE

46673

DATE

4/13/23