



PATIENT PRESENTING CLINICAL SIGNS

Moses Hellmuth

Weight loss, vomiting, diarrhea Working diagnosis concern for neoplasia Summary of Abnormal LABs mild increase in BUN, low USG cerenia 1/4 of 24mg tab daily.

SPECIES

Feline

ULTRASONOGRAPHIC EXAMINATION OF THE ABDOMEN

BREED

DSH

Urinary System

The urinary bladder is moderately distended with anechoic urine. The Bladder wall, trigone, ureteral papillae and visible urethra (to a depth of 2cm) appear normal with no evidence of wall thickening, mucosal irregularities, masses or cystic calculi.

SEX

Spayed Female

The left kidney has a normal shape and size (3.41 cm). Overall echogenicity is normal with adequate corticomedullary distinction and a typical 1:3 cortex:medulla ratio. There is no evidence of focal perinephric inflammation or effusion. There is no evidence of pyelectasia, nephroliths, infarcts or hydroureter. Renal vasculature is normal.

AGE

10/19/07

The right kidney has a normal shape and size (2.97 cm) with mild pyelectasia at 0.29 cm. Overall echogenicity is normal with adequate corticomedullary distinction and a typical 1:3 cortex:medulla ratio. There is no evidence of focal perinephric inflammation or effusion. There is no evidence of nephroliths, infarcts or hydroureter. Renal vasculature is normal.

WEIGHT

5.44 kg

Adrenal Glands

The left adrenal gland is normal in size measuring 0.37 cm at the caudal pole. It is observed in its normal position cranial to the left renal artery. It is normal in appearance (uniformly hypoechoic) and shape with no evidence of a mass effect.

The region of the right adrenal (between right cranial kidney and vena cava) is unremarkable, but the adrenal is not distinctly visualized. No evidence of a mass effect is visualized.

INTERPRETED BY

Kathleen Sennello DVM,
MS, Diplomate ACVIM
(Small Animal Internal
Medicine)

Spleen

The spleen is subjectively normal in size (0.99 cm), echotexture is homogenous, and the splenic capsule is smooth with no irregularities. The blood flow through the hilus and splenic parenchyma appears normal. No focal parenchymal abnormalities are visualized.

IMAGING PERFORMED BY

Loetitia Saint-Jacques,
LVT

Liver

The liver is subjectively normal in size, and echogenicity with smooth peripheral margins. The parenchyma is homogenous echotexture. The visible portions of the vasculature and biliary tract appear normal. No focal nodules or cystic lesions are observed.

HOSPITAL NAME

MountRose AH

REFERRING VET

Dr. Carroll

INVOICE

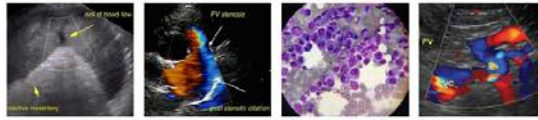
46661

Gastrointestinal

The stomach contains minimal luminal contents. It measures at a normal thickness of <0.36cm with some variability due to the presence of rugal folds. The distinction of the gastric wall layers is adequate and there is no impression of reduced peristaltic activity. No masses or focal lesions were observed.

DATE

4/13/23



PATIENT

Moses Hellmuth

SPECIES

Feline

BREED

DSH

SEX

Spayed Female

AGE

10/19/07

WEIGHT

5.44 kg

INTERPRETED BY

Kathleen Sennello DVM,
MS, Diplomate ACVIM
(Small Animal Internal
Medicine)

**IMAGING
PERFORMED BY**

Loetitia Saint-Jacques,
LVT

HOSPITAL NAME

MountRose AH

REFERRING VET

Dr. Carroll

INVOICE

46661

DATE

4/13/23

The visualized areas of duodenum, jejunum and ileum have a uniform diameter with minimal fluid distension. Wall thickness is normal to slightly increased. Bowel loops follow a typical curvilinear path with distinct wall layering, but some areas display a prominent muscularis layer which does not display the typical 1:3 muscularis:mucosa layer ratio. Duodenum wall measures 0.46 cm. Jejunum wall measures 0.39 cm. Visualized peristalsis appears appropriate. There is a focal section of small intestine where the wall progressively thickens and loses distinction of wall layering, terminating at a large focal bowel mass with a wall thickness of 1.2 cm and complete loss of layering. Orad to this mass effect, the bowel is significantly fluid dilated, suggestive of an obstruction or partial obstruction.

The ileocecal junction was visualized and exhibited normal intact wall layering and is subjectively of normal thickness. Sections of colon are visualized with formed fecal material and gas shadowing distally. There is no observed focal or generalized colon wall thickening or loss of layering.

Pancreas

The pancreas is prominent and hypoechoic as compared to the surrounding isoechoic mesentery. There is no evidence of nodules or cystic lesions. There is no evidence of regional mesenteric inflammation or fluid.

Free Abdomen

Evaluation of the peritoneal cavity did not reveal any evidence of effusion. There are occasional prominent mesenteric lymph nodes. One such lymph node measures at 0.42 cm. The omentum is hyperechoic around the abnormal bowel.

ULTRASONOGRAPHIC FINDINGS

- Hypoechoic, prominent pancreas – The pancreatic changes are most consistent with mild pancreatitis or a recent episode of pancreatic inflammation.
- Diffusely thickened small bowel with a prominent muscularis layer – The small intestinal wall changes could be consistent with an underlying inflammatory process. These types of changes can sometimes be seen in normal older cats. Correlate with clinical signs.
- Focally thickened area of small intestine with complete loss of layering and a narrowed lumen – Findings are suggestive of a focal bowel mass and likely partial obstruction.
- Prominent mesenteric lymph nodes – The prominent abdominal lymph nodes are most consistent with reactive lymphadenitis or lymphoid hyperplasia. Neoplastic infiltration is considered less likely.

INTERPRETATION OF THE FINDINGS & FURTHER RECOMMENDATIONS

The small intestine is diffusely thickened with a prominent muscularis layer. These changes could be consistent with chronic inflammatory disease, neoplasia, etc. Additionally, there is a focal section of small bowel with progressive thickening and complete loss of layering. The small intestine cranial to this lesion appears fluid/ingesta dilated, suggestive of a partial obstruction. These findings are most consistent with a focal bowel mass. Likely differentials would include round cell neoplasia, carcinoma, etc. Recommend a fine needle aspirate of the bowel wall in this region. If a cytologic diagnosis cannot be obtained based on a fine needle aspirate, consider surgical biopsies.



PATIENT

Moses Hellmuth

Recommend three view thoracic radiographs to evaluate for possible concurrent thoracic disease/involvement.

SPECIES

Feline

BREED

DSH

SEX

Spayed Female

AGE

10/19/07

WEIGHT

5.44 kg

INTERPRETED BY

Kathleen Sennello DVM,
MS, Diplomate ACVIM
(Small Animal Internal
Medicine)

**IMAGING
PERFORMED BY**

Loetitia Saint-Jacques,
LVT

HOSPITAL NAME

MountRose AH

REFERRING VET

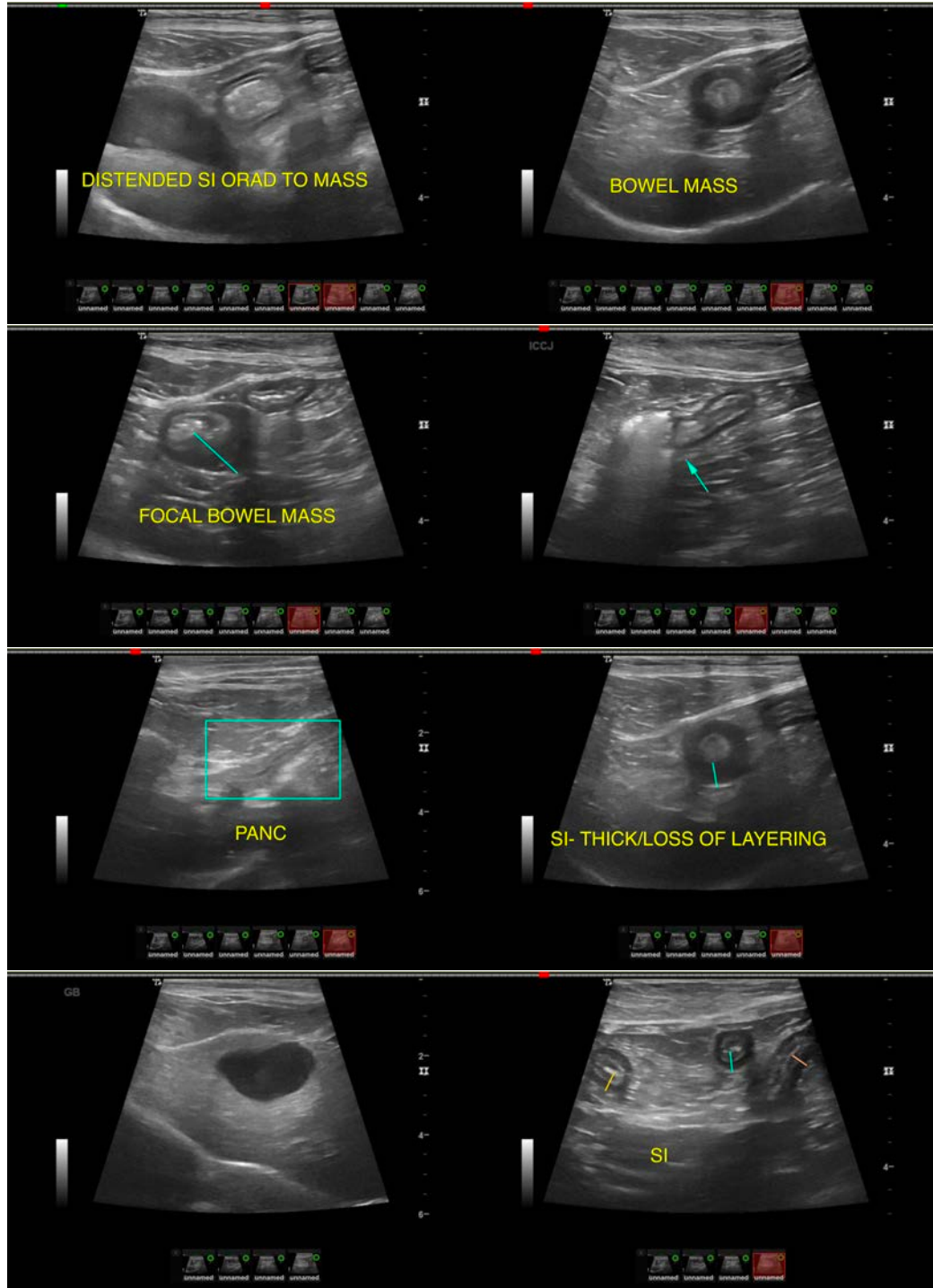
Dr. Carroll

INVOICE

46661

DATE

4/13/23





PATIENT

Moses Hellmuth

SPECIES

Feline

BREED

DSH

SEX

Spayed Female

AGE

10/19/07

WEIGHT

5.44 kg

INTERPRETED BY

Kathleen Sennello DVM,
MS, Diplomate ACVIM
(Small Animal Internal
Medicine)

**IMAGING
PERFORMED BY**

Loetitia Saint-Jacques,
LVT

HOSPITAL NAME

MountRose AH

REFERRING VET

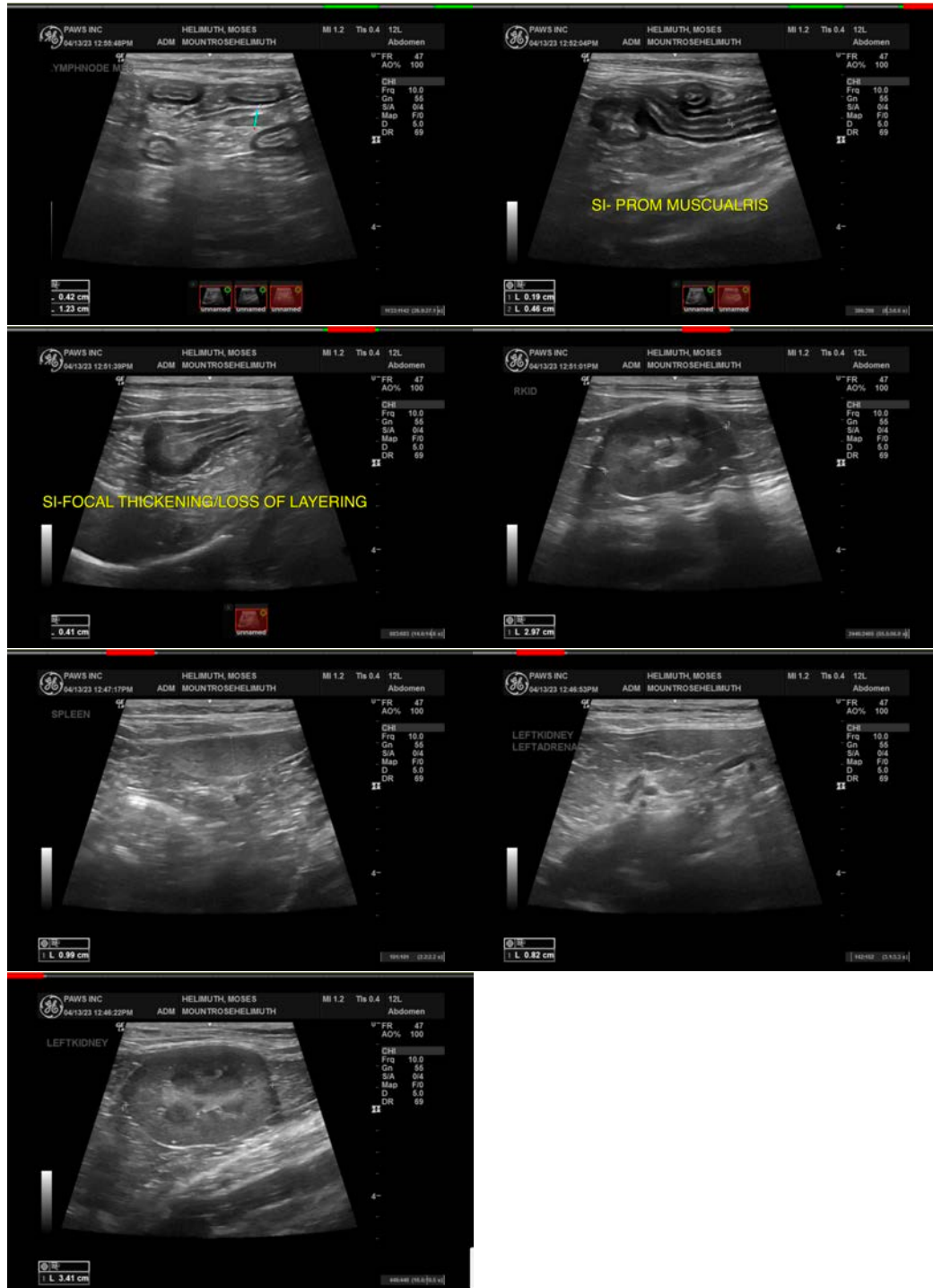
Dr. Carroll

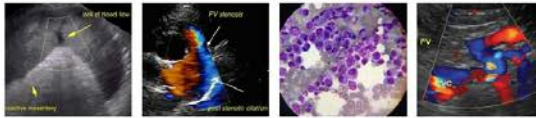
INVOICE

46661

DATE

4/13/23





PATIENT

Moses Hellmuth

The information and recommendations provided are based on the images presented by the referring veterinarian/sonographer. No evaluation can be communicated regarding pathology that was not visible in the image/video clips provided.

SPECIES

Feline

Thank you for this referral. If the clinical or image interpretation does not parallel your findings or if I can be of any further assistance please contact me.

Kathleen Sennello DVM,MS, Diplomate ACVIM (Small animal Internal Medicine)

BREED

DSH

kathleen.sennello@sonopath.com

SEX

Spayed Female

AGE

10/19/07

WEIGHT

5.44 kg

INTERPRETED BY

Kathleen Sennello DVM,
MS, Diplomate ACVIM
(Small Animal Internal
Medicine)

**IMAGING
PERFORMED BY**

Loetitia Saint-Jacques,
LVT

HOSPITAL NAME

MountRose AH

REFERRING VET

Dr. Carroll

INVOICE

46661

DATE

4/13/23