

**DATE PRESENTING CLINICAL SIGNS**

4/13/23

Diagnosed as diabetic about 3 months ago Also had elevation in pancreatic enzymes Was on 4 units of vetsulin, after last curve about 1 month ago, increased to 5 Units BID (around 7am/7pm) tonight ate , got insulin then head was down, bobbing? , did not want to move owner did give honey No change in diet-- had been on wet food since diagnosed as diabetic Had an episode of vomiting a few days ago , once about 4-5 days ago-- also episode of being sluggish.

PATIENT

Layla Quezada

SPECIES

Canine

Current Medications: Buprenorphine.

Lab Results: See attached.

Radiographs: Stomach pretty full of ingesta, SI- ingesta moving through, feces in colon. No uroliths narrow disk space.

BREED

West Highland Terrier

Date of Previous IntraPet Ultrasound: No previous.

Sedation: Not required to complete full diagnostic ultrasound.

Stat Report: Not requested.

Imaging Performed By: Rachel Brillhart, RDMS.

SEX

Spayed Female

ULTRASONOGRAPHIC EXAMINATION OF THE ABDOMEN**AGE**

1/1/12

Urinary System

The urinary bladder is moderately distended with anechoic urine. The Bladder wall, trigone, ureteral papillae and visible urethra (to a depth of 2cm) appear normal with no evidence of wall thickening, mucosal irregularities, masses or cystic calculi.

WEIGHT

19.2 Pounds

The left kidney has a normal shape and size (4.88 cm) with small non-obstructive nephroliths and mild pyelectasia at 0.37 cm. Overall echogenicity is normal with adequate corticomedullary distinction and a typical 1:3 cortex:medulla ratio. There is no evidence of focal perinephric inflammation or effusion. There is no evidence of infarcts or hydroureter. Renal vasculature is normal.

INTERPRETED BY

Kathleen Sennello DVM,
MS, Diplomate ACVIM
(Small Animal Internal
Medicine)

The right kidney has a normal shape and size (4.91 cm) with pinpoint non-obstructive nephroliths. Overall echogenicity is normal with adequate corticomedullary distinction and a typical 1:3 cortex:medulla ratio. There is no evidence of focal perinephric inflammation or effusion. There is no evidence of pyelectasia, infarcts or hydroureter. Renal vasculature is normal.

HOSPITAL NAME

Animal Emergency
Hospital

Adrenal Glands

The left adrenal gland is normal in size measuring 0.59 cm at the caudal pole. It is observed in its normal position cranial to the left renal artery. It is normal in appearance (uniformly hypoechoic) and shape with no evidence of a mass effect.

REFERRING VET

Dr. King

The right adrenal gland is normal in size measuring 0.57 cm at the caudal pole. It is observed in its normal position between the cranial aspect of the right kidney and the caudal vena cava. It is normal in appearance (uniformly hypoechoic) and shape with no evidence of a mass effect.

INVOICE

46653

Spleen

The spleen is subjectively normal in size and the echotexture is homogenous. The splenic capsule is smooth with no visible irregularities. Rare discrete focal hyperechoic, perivascular parenchymal abnormalities are present. The appearance of these lesions is most consistent with benign splenic myelolipomas. The blood flow through the hilus and splenic parenchyma appears normal.

Liver

The liver is large in size, and hypoechoic with smooth peripheral margins. The parenchyma is heterogenous in echotexture with subtle, indistinct focal mottling. The visible portions of the vasculature and biliary tract appear normal. There is an iso- to hypoechoic ill-defined nodule visualized measuring 1.97 cm x 1.4 cm.

The gallbladder lumen is moderately distended. The wall of the gall bladder is not thickened and has a smooth mucosal surface. Luminal contents are mild and primarily anechoic. The cystic and common bile ducts are normal/not visible.

Gastrointestinal

The stomach contains a moderate amount of fluid/ingesta. It measures at a normal thickness of <0.7cm with some variability due to the presence of rugal folds. The distinction of the gastric wall layers is adequate and there is no impression of reduced peristaltic activity. The pylorus appears somewhat prominent with a wall thickness of 0.55 cm with intact wall layering.

The visualized areas of duodenum, jejunum and ileum have a relatively uniform diameter with minimal fluid distension. Wall thickness is normal. Bowel loops follow a curvilinear path with distinct wall layering maintaining the typical 1:3 muscularis:mucosa layer ratio. Duodenum wall measures 0.37 cm. Jejunum wall measures 0.33 cm. Visualized peristalsis appears appropriate. There were no focal lesions consistent with obstruction or a mass effect observed.

The ileocecal junction was visualized and exhibited normal intact wall layering and is subjectively of normal thickness. Sections of colon are visualized with formed fecal material and gas shadowing distally. There is no observed focal or generalized colon wall thickening or loss of layering.

Pancreas

The pancreas is large and hypoechoic to surrounding mesentery. There is no evidence of nodules or cystic lesions. There is evidence of regional mesenteric inflammation. Consistent with moderate pancreatitis.

Free Abdomen

Evaluation of the peritoneal cavity did not reveal any evidence of effusion, or subjective lymphadenomegaly. The Medial iliac nodes appear normal and there was no evidence of a caudal aortic thrombus at the bifurcation. The omentum is of normal uniform echogenicity.

Other

Ringdown artifact is visualized at the level of the diaphragm. This can indicate pulmonary parenchymal disease. Recommend 3-view thoracic radiographs.

ULTRASONOGRAPHIC FINDINGS

- Pinpoint non-obstructive nephroliths visualized in both kidneys with left-sided pyelectasia – Pyelectasia of the kidney(s) could be consistent with pyelonephritis, chronic renal disease, secondary to PU/PD or fluid therapy (if applicable), other.
- Large, irregular, hypoechoic pancreas with surrounding hyperechoic mesentery – The pancreatic changes are most consistent with moderate pancreatitis/pancreatic inflammation. Recommend fPLI testing and continued monitoring for improvement or possible development of a pancreatic abscess. Consider fine needle aspirate if not improving.
- Hypoechoic, heterogeneous liver with ill-defined iso- to hypoechoic nodule – The diffuse hepatic changes are non-specific and could be consistent with vacuolar hepatopathy, nodular hyperplasia, inflammatory/immune-mediated disease, fibrosis, extramedullary hematopoiesis, toxic hepatopathy (e.g., copper), infiltrative neoplasia (less likely) or other hepatopathy. The nature of the nodule visualized is uncertain. Minimal criteria for malignancy are present. Recommend fine needle aspirate or continued monitoring.

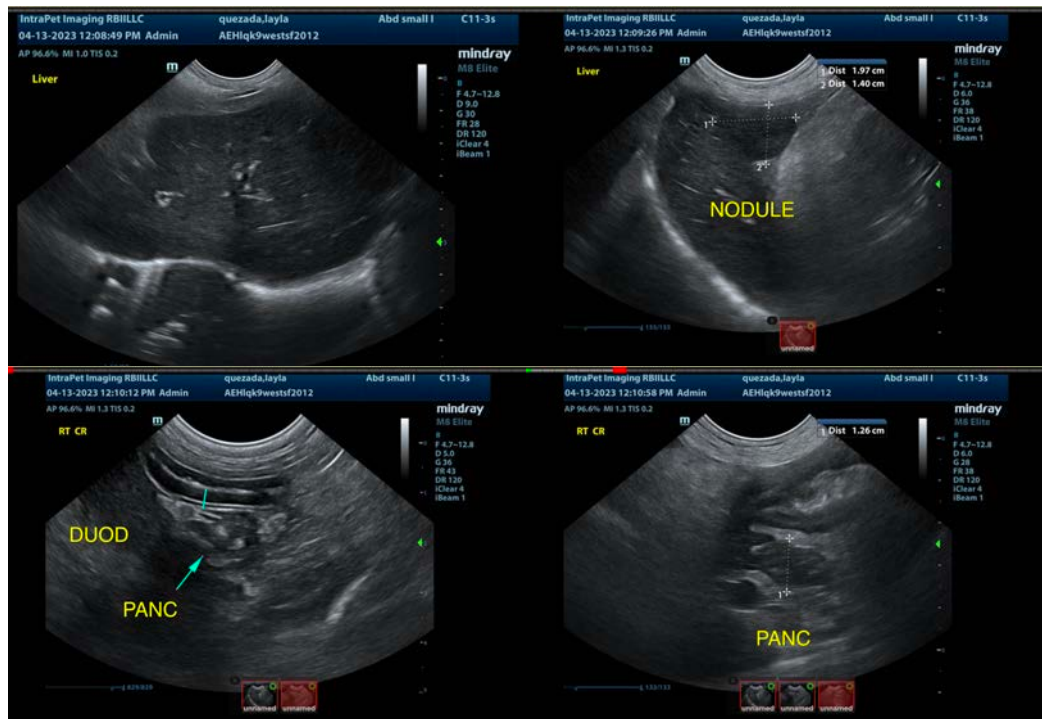
- Moderate fluid distention of the stomach with a prominent pylorus – Correlate findings with feeding history. If the patient was adequately fasted, consider such differentials as delayed gastric emptying or a partial pyloric outflow tract obstruction (none observed). The pyloric wall is somewhat prominent with intact wall layering. This is likely secondary to the pancreatitis.
- Ringdown artifact visualized at the level of the diaphragm – Recommend 3-view thoracic radiographs, looking for pulmonary parenchymal disease.

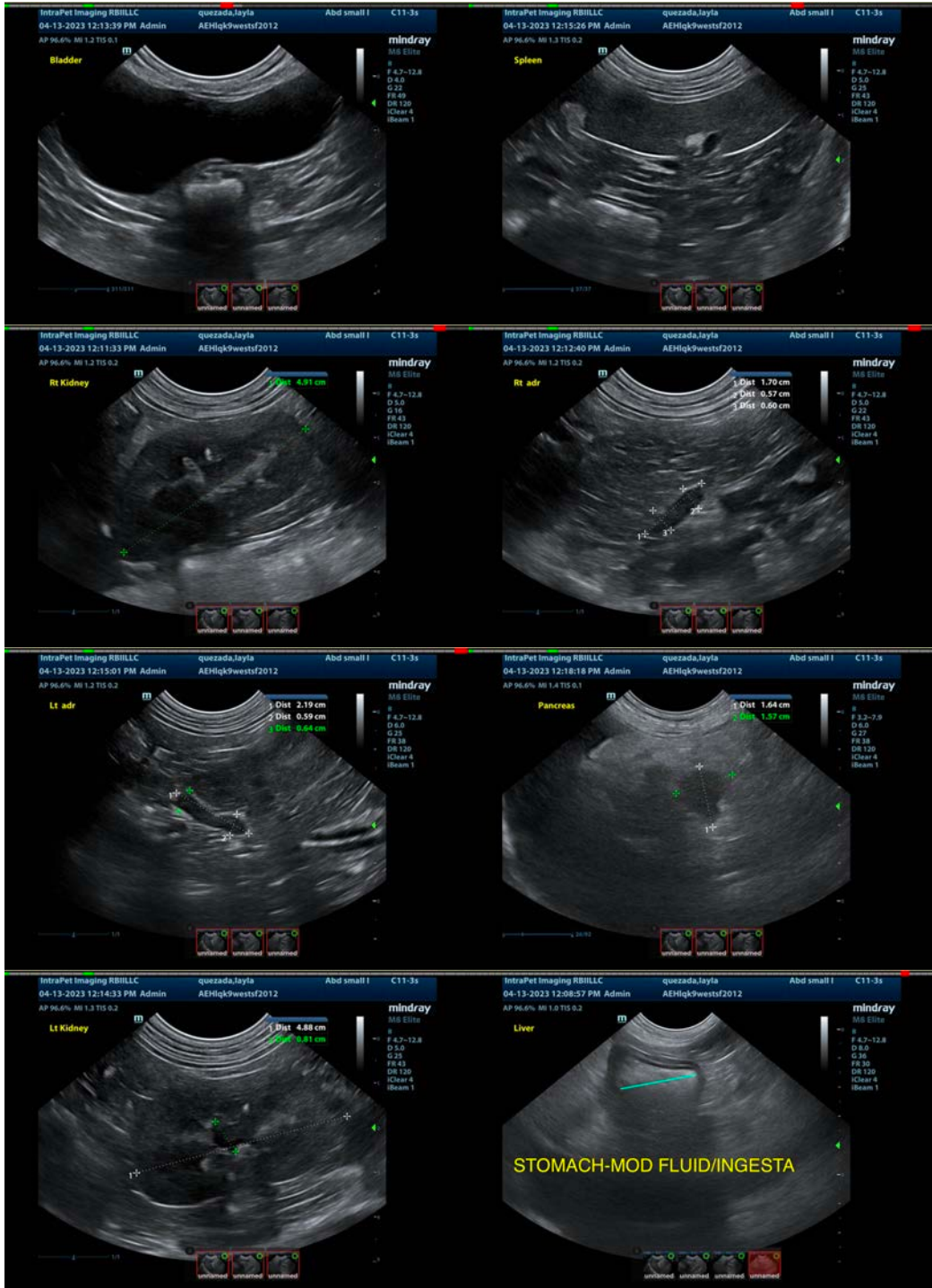
INTERPRETATION OF THE FINDINGS & FURTHER RECOMMENDATIONS

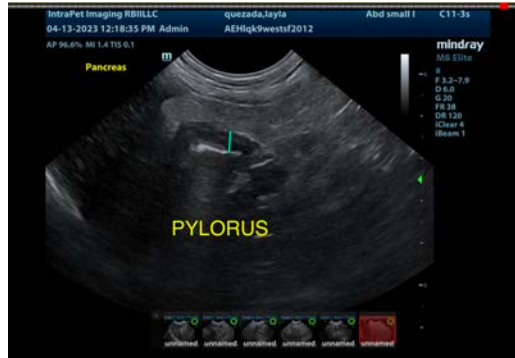
The pancreas is large, irregular, and hypoechoic with surrounding hyperechoic mesentery. Findings are most consistent with moderate pancreatitis. Recommend medical treatment for pancreatitis with pain medications, fluids, nausea medications, etc. If the patient is not improving as would be expected, consider reevaluation for the possible development of an abscess or progression of this lesion.

Additionally, the liver is hypoechoic and heterogeneous. this can be associated with inflammatory disease, infiltrative disease, etc. If significant liver enzyme elevations are present beyond what would be expected for a diabetic hepatopathy, consider a liver function test and a fine needle aspirate of the liver (provided coagulation parameters are normal).

The stomach is somewhat fluid dilated and there is a prominent pyloric wall. I suspect this is secondary to gastric ileus and the pancreatitis noted. Consider reevaluation of these areas if the patient is not improving.







The information and recommendations provided are based on the images presented by the referring veterinarian/sonographer. No evaluation can be communicated regarding pathology that was not visible in the image/video clips provided.

Thank you for this referral. If the clinical or image interpretation does not parallel your findings or if I can be of any further assistance please contact me.

Kathleen Sennello DVM,MS, Diplomate ACVIM (Small animal Internal Medicine)
kathleen.sennello@sonopath.com