

**DATE PRESENTING CLINICAL SIGNS**

4/13/22

Presenting complaint was for not having bowel movements. no vomiting, coughing, appetite is normal, attitude is normal. Just had arthritis. On exam, could palpate the caudal aspect of something large and rounded on the right, but did not feel like a kidney. After reviewing the rads, suspect it was the liver I was palpating. Radiographs also revealed an enlarged globoid heart.

PATIENT

Daisy Malamphy

SPECIES

Canine

Current Medications: None listed.

Lab Results: Slightly elevated ALP and ALT, Anemia of chronic dz

Date of Previous IntraPet Ultrasound: No previous.

Sedation: Not required to complete full diagnostic ultrasound.

Stat Report: STAT Requested by DVM.

BREED

Norwich Terrier

ULTRASONOGRAPHIC EXAMINATION OF THE ABDOMEN**SEX**

Spayed Female

Urinary System

The urinary bladder is moderately distended with anechoic urine. The Bladder wall, trigone, ureteral papillae and visible urethra (to a depth of 2cm) appear normal with no evidence of wall thickening, mucosal irregularities, masses or cystic calculi.

AGE

2/2/08

The left kidney is large and irregular, measuring 5.71 cm. It has decreased corticomedullary distinction. There is no evidence of perinephric inflammation or effusion. There is no evidence of pyelectasia, nephroliths, infarcts or hydroureter. Renal vasculature is normal. The kidney is irregular in shape and has an iso- to hypoechoic mass effect visualized towards the caudal pole, measuring 2.02 cm x 1.68 cm.

WEIGHT

19.2 Pounds

The right kidney is large and irregular in shape at 6.84 cm with pyelectasia at 0.39 cm. Overall echogenicity is slightly hyperechoic with poor corticomedullary distinction and a typical 1:3 cortex:medulla ratio. There is no evidence of perinephric inflammation or effusion. There is no evidence of nephroliths, infarcts or hydroureter. Renal vasculature is normal. There are multiple mass effects on the kidneys. There is a large, irregular, hyperechoic lesion on the cranial aspect of the kidney measuring 3.67 cm x 2.76 cm. Additionally, there is a hypoechoic, rounded mass lesion measuring 2.22 cm in diameter.

INTERPRETED BY

Kathleen Sennello DVM,
MS, Diplomate ACVIM
(Small Animal Internal
Medicine)

Adrenal Glands

The left adrenal gland is normal in size measuring 0.67 cm at the caudal pole. It is observed in its normal position cranial to the left renal artery. It is normal in appearance (uniformly hypoechoic) and shape with no evidence of a mass effect.

IMAGING PERFORMED BY

Rachel Brillhart RDMS

The right adrenal gland is normal in size measuring 0.78 cm at the caudal pole. It is observed in its normal position between the cranial aspect of the right kidney and the caudal vena cava. It is normal in appearance (uniformly hypoechoic) and shape with no evidence of a mass effect.

HOSPITAL NAME

Paradise AH

Spleen

The spleen is subjectively normal in size. The spleen echotexture is heterogenous and mottled, the splenic capsule is smooth with no irregularities. The blood flow through the hilus and splenic parenchyma appears normal. There is a small, hypoechoic nodule visualized measuring 0.73 cm.

REFERRING VET

Dr. Pearson

Liver**INVOICE**

36820

The liver is large in size and irregular. The parenchyma is heterogenous in echotexture with subtle, indistinct focal mottling. Prominent dilated vasculature is present. There are numerous discreet iso- to hypoechoic masses throughout the hepatic parenchyma. Many of these mass effects deviate the splenic margins. One is measured at 2.35 cm x 1.23 cm, one measures 3.82 cm in diameter, one measures 1.38 cm in diameter, one measures 2.4 cm in diameter, and a larger peripheral mass lesion is 4.31 cm x 3.03 cm.

The gallbladder lumen is moderately distended. The wall of the gall bladder is not thickened and has a smooth mucosal surface. Luminal contents are primarily anechoic. The cystic and common bile ducts are normal/not visible.

Gastrointestinal

The stomach contains minimal luminal contents. It measures at a normal thickness of <0.7cm with some variability due to the presence of rugal folds. The distinction of the gastric wall layers is adequate and there is no impression of reduced peristaltic activity. No masses or focal lesions were observed.

The visualized areas of duodenum, jejunum and ileum have a relatively uniform diameter with minimal fluid distension. Wall thickness is normal. Bowel loops follow a curvilinear path with distinct wall layering maintaining the typical 1:3 muscularis:mucosa layer ratio. The duodenum measured as normal (between 0.3-0.5cm in wall thickness) and the jejunum measured as normal (between 0.2-0.47cm.) Visualized peristalsis appears appropriate. There were no focal lesions consistent with obstruction or a mass effect observed.

The ileocecal junction was visualized and exhibited normal intact wall layering and is subjectively of normal thickness. Sections of colon are visualized with formed fecal material and gas shadowing distally. There is no observed focal or generalized colon wall thickening or loss of layering.

Pancreas

The pancreas is normal and isoechoic to surrounding mesentery. There is no evidence of nodules or cystic lesions. There is no evidence of regional mesenteric inflammation or fluid.

Free Abdomen

There is a moderate amount of anechoic free fluid. There is no lymphadenomegaly and the omentum is generally of normal echogenicity.

Other

A brief view of the heart was submitted. No significant pericardial effusion was seen.

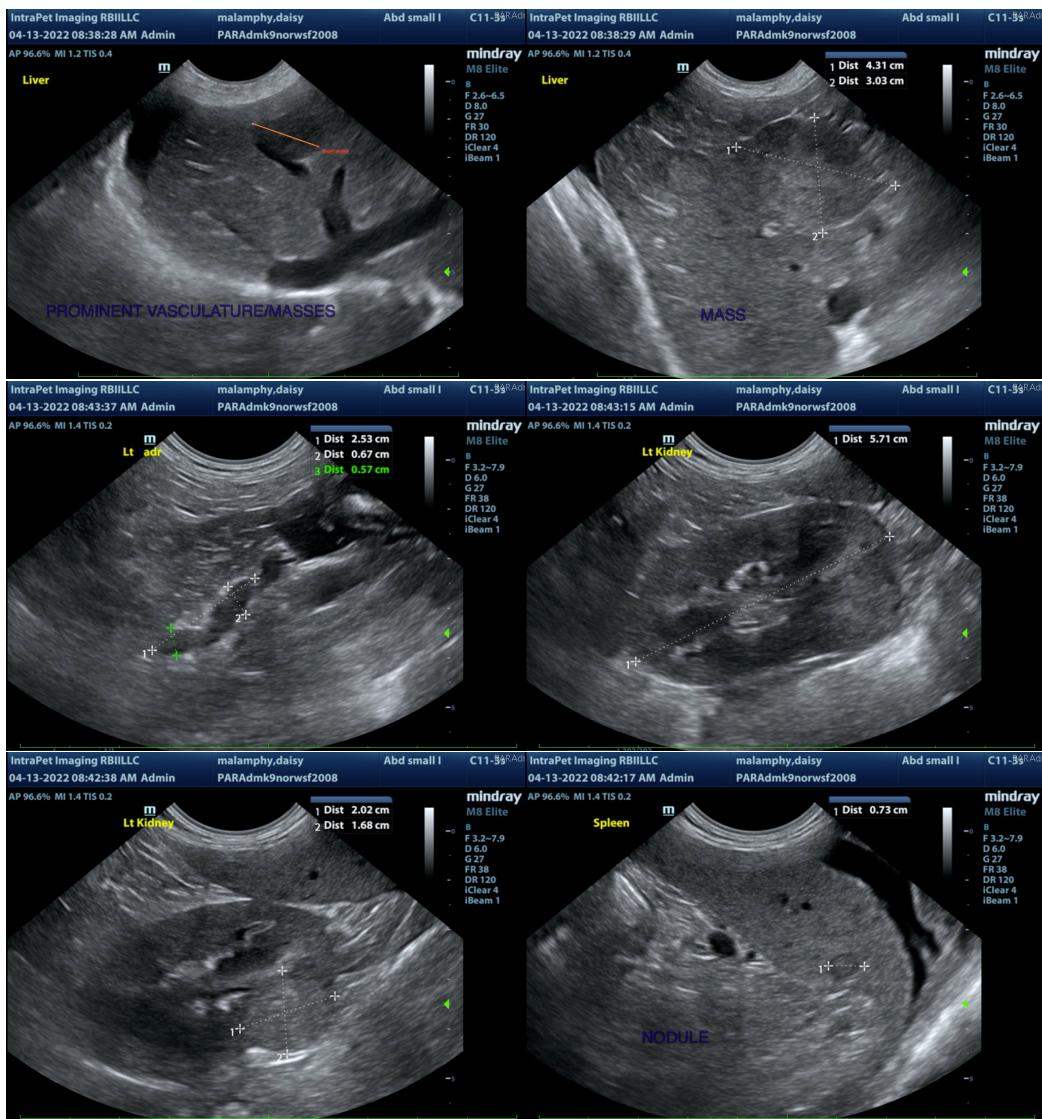
ULTRASONOGRAPHIC FINDINGS

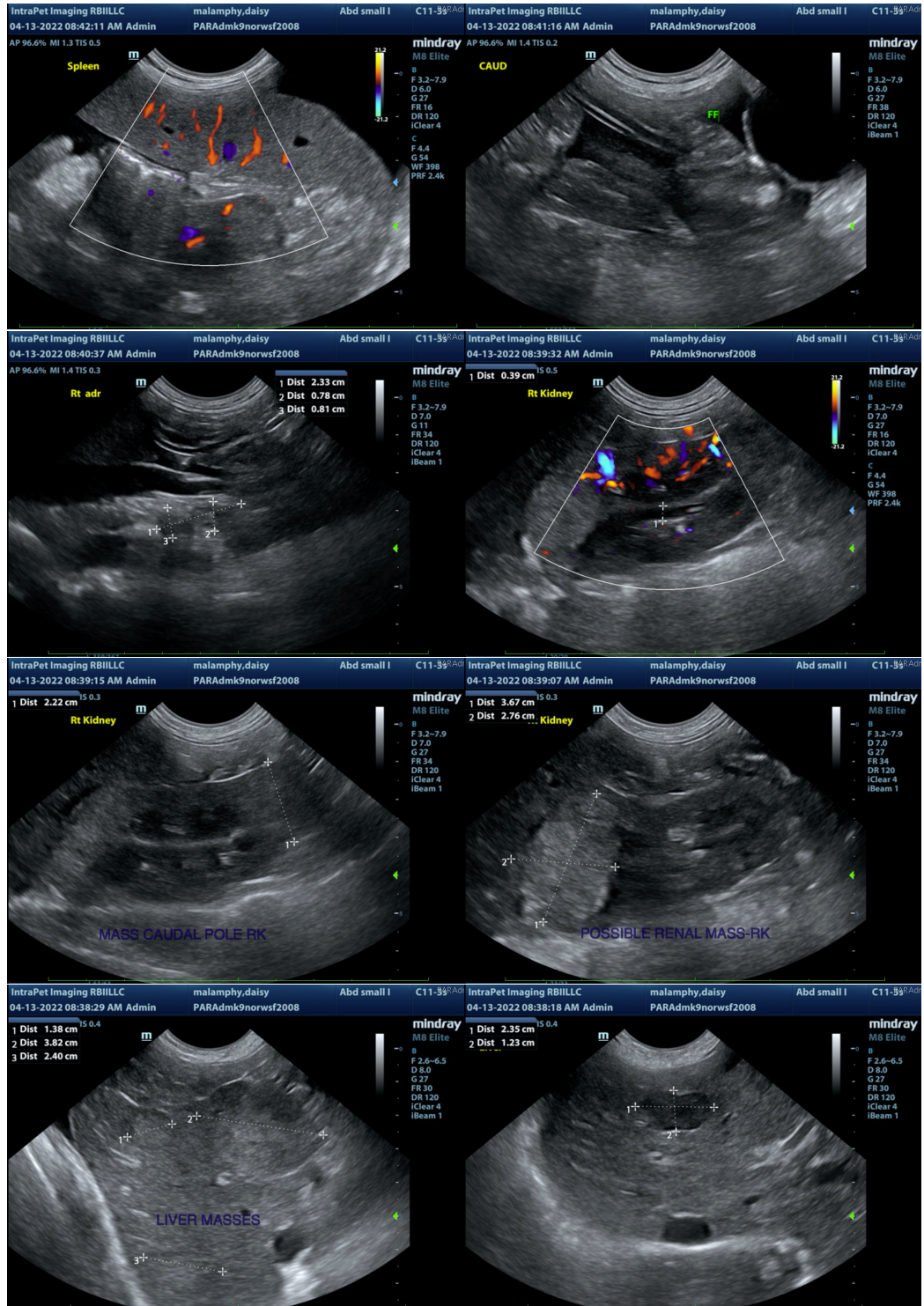
- Bilateral renal masses with mild right-sided pyelectasia – Findings are concerning for metastatic neoplasia. Consider a fine needle aspirate.
- Large, heterogeneous liver with dilated vasculature and multiple discrete liver masses – Findings are concerning for hepatic congestion and possible metastatic neoplasia, although other differentials exist. Consider a fine needle aspirate of the liver, and cardiac evaluation.
- Mottled spleen with hypoechoic nodule – There is a non-cavitated, hypoechoic splenic nodule visualized. Differentials include lymphoid hyperplasia, extramedullary hematopoiesis, infiltrative neoplasia, inflammation, other. Cytology or histopathology would be necessary to get a definitive diagnosis.
- Free abdominal fluid – Based on the appearance of this scan, most likely differentials would be congestion secondary to heart disease, or a vascular obstruction due to a mass effect. Alternately, a neoplastic effusion is possible.

INTERPRETATION OF THE FINDINGS & FURTHER RECOMMENDATIONS

There are multiple mass effects visualized within the kidneys and in the liver. Recommend a fine needle aspirate of both of these locations, as metastatic disease is of high concern. There is a moderate amount of free abdominal fluid in the abdomen, and the vasculature in the liver appears somewhat dilated. This could be due to congestion due to right-sided heart failure, a mass effect compressing the vasculature, or this could be consistent with a neoplastic effusion. Recommend sampling and fluid analysis with cytology.

Consider three view thoracic radiographs to rule out concurrent thoracic disease/involvement.





The information and recommendations provided are based on the images presented by the referring veterinarian/sonographer. No evaluation can be communicated regarding pathology that was not visible in

the image/video clips provided.

Thank you for this referral. If the clinical or image interpretation does not parallel your findings or if I can be of any further assistance please contact me.

Kathleen Sennello DVM,MS, Diplomate ACVIM (Small animal Internal Medicine)
kathleen.sennello@sonopath.com