

**DATE PRESENTING CLINICAL SIGNS**

4/12/23

O think pt may have lost some weight, otherwise pt is doing well. E/D normally, no v/d/c/s, activity level normal, pt indoor/outdoor. Did bloodwork for dental.

PATIENT

Pepper Shea

Current Medications: None.

Lab Results: Elevated SDMA, BUN, Creat and UA of 3+ blood, USG 1.018, lymphocytosis.

Date of Previous IntraPet Ultrasound: No previous.

Sedation: Not required to complete full diagnostic ultrasound.

Stat Report: Not requested.

Imaging Performed By: Rachel Brillhart, RDMS.

SPECIES

Feline

BREED

DSH

SEX

Spayed Female

AGE

3/13/13

WEIGHT

10.9 Pounds

INTERPRETED BY

Kathleen Sennello DVM,
MS, Diplomate ACVIM
(Small Animal Internal
Medicine)

HOSPITAL NAME

Eldersburg Vet

REFERRING VET

Dr. Jamed

INVOICE

46604

ULTRASONOGRAPHIC EXAMINATION OF THE ABDOMEN**Urinary System**

The urinary bladder is moderately distended with anechoic urine. The Bladder wall, trigone, ureteral papillae and visible urethra (to a depth of 2cm) appear normal with no evidence of wall thickening, mucosal irregularities, masses or cystic calculi.

The left kidney has a normal shape and size (2.93 cm) with mild pyelectasia at 0.15 cm. Overall echogenicity is slightly hyperechoic with poor corticomedullary distinction and a typical 1:3 cortex:medulla ratio. There is no evidence of focal perinephric inflammation or effusion. There is no evidence of nephroliths, infarcts or hydroureter. Renal vasculature is normal.

The right kidney has a normal shape and size (2.95 cm) with mild pyelectasia at 0.30 cm. Overall echogenicity is slightly hyperechoic with poor corticomedullary distinction and a typical 1:3 cortex:medulla ratio. There is no evidence of focal perinephric inflammation or effusion. There is no evidence of nephroliths, infarcts or hydroureter. Renal vasculature is normal.

Adrenal Glands

The left adrenal gland is normal in size measuring 0.40 cm at the caudal pole. It is observed in its normal position cranial to the left renal artery. It is normal in appearance (uniformly hypoechoic) and shape with no evidence of a mass effect.

The right adrenal gland is normal in size measuring 0.48 cm at the caudal pole. It is observed in its normal position between the cranial aspect of the right kidney and the caudal vena cava. It is normal in appearance (uniformly hypoechoic) and shape with no evidence of a mass effect.

Spleen

The spleen is subjectively normal in size (0.64 cm), echotexture is homogenous, and the splenic capsule is smooth with no irregularities. The blood flow through the hilus and splenic parenchyma appears normal. No focal parenchymal abnormalities are visualized.

Liver

The liver is subjectively normal in size, and echogenicity with smooth peripheral margins. The parenchyma is homogenous echotexture. The visible portions of the vasculature and biliary tract appear normal. No focal nodules or cystic lesions are observed.

The gallbladder lumen is moderately distended. The wall of the gall bladder is not thickened and has a smooth mucosal surface. Luminal contents are mild and primarily anechoic. The cystic and common bile ducts are normal/not visible.

Gastrointestinal

The stomach contains minimal luminal contents. It measures at a normal thickness of <0.36cm with some variability due to the presence of rugal folds. The distinction of the gastric wall layers is adequate and there is no impression of reduced peristaltic activity. No masses or focal lesions were observed.

The visualized areas of duodenum, jejunum and ileum have a uniform diameter with minimal fluid distension. Wall thickness is normal to slightly increased. Bowel loops follow a typical curvilinear path with distinct wall layering, but some areas display a prominent muscularis layer which does not display the typical 1:3 muscularis:mucosa layer ratio. Duodenum wall measures 0.29 cm. Jejunum wall measures 0.35 cm. Visualized peristalsis appears appropriate. There were no focal lesions consistent with obstruction or a mass effect observed.

The ileocecal junction was visualized and exhibited normal intact wall layering and is subjectively of normal thickness. Sections of colon are visualized with formed fecal material and gas shadowing distally. There is no observed focal or generalized colon wall thickening or loss of layering.

Pancreas

The pancreas is prominent and mottled compared to the surrounding isoechoic mesentery. There is no evidence of nodules or cystic lesions. There is no evidence of regional mesenteric inflammation or fluid.

Free Abdomen

Evaluation of the peritoneal cavity did not reveal any evidence of effusion. There are occasional prominent mesenteric lymph nodes. Example of these measure at 0.41, 0.35 cm. Additionally, there is a small cluster of prominent lymph nodes near the ileocecal junction. One of these measures at 0.25 cm. The omentum is slightly hyperechoic around these lymph nodes.

ULTRASONOGRAPHIC FINDINGS

- Decreased corticomedullary distinction in both kidneys with mild pyelectasia – Mild loss of corticomedullary distinction in both kidneys could be consistent with chronic degenerative disease or interstitial nephrosis. Pyelectasia of the kidney(s) could be consistent with pyelonephritis, chronic renal disease, secondary to PU/PD or fluid therapy (if applicable), other.
- Prominent, mottled pancreas – The pancreatic changes are most consistent with age-related parenchymal remodeling, potentially secondary to a prior inflammatory episode, early fibrosis or chronic pancreatitis.
- Mildly prominent muscularis layer in some areas of the small intestine – The small intestinal wall changes could be consistent with an underlying inflammatory process. These types of changes can sometimes be seen in normal older cats. Correlate with clinical signs.
- Visible/slightly prominent mesenteric lymph nodes – The prominent abdominal lymph nodes are most consistent with reactive lymphadenitis or lymphoid hyperplasia. Neoplastic infiltration is considered less likely.

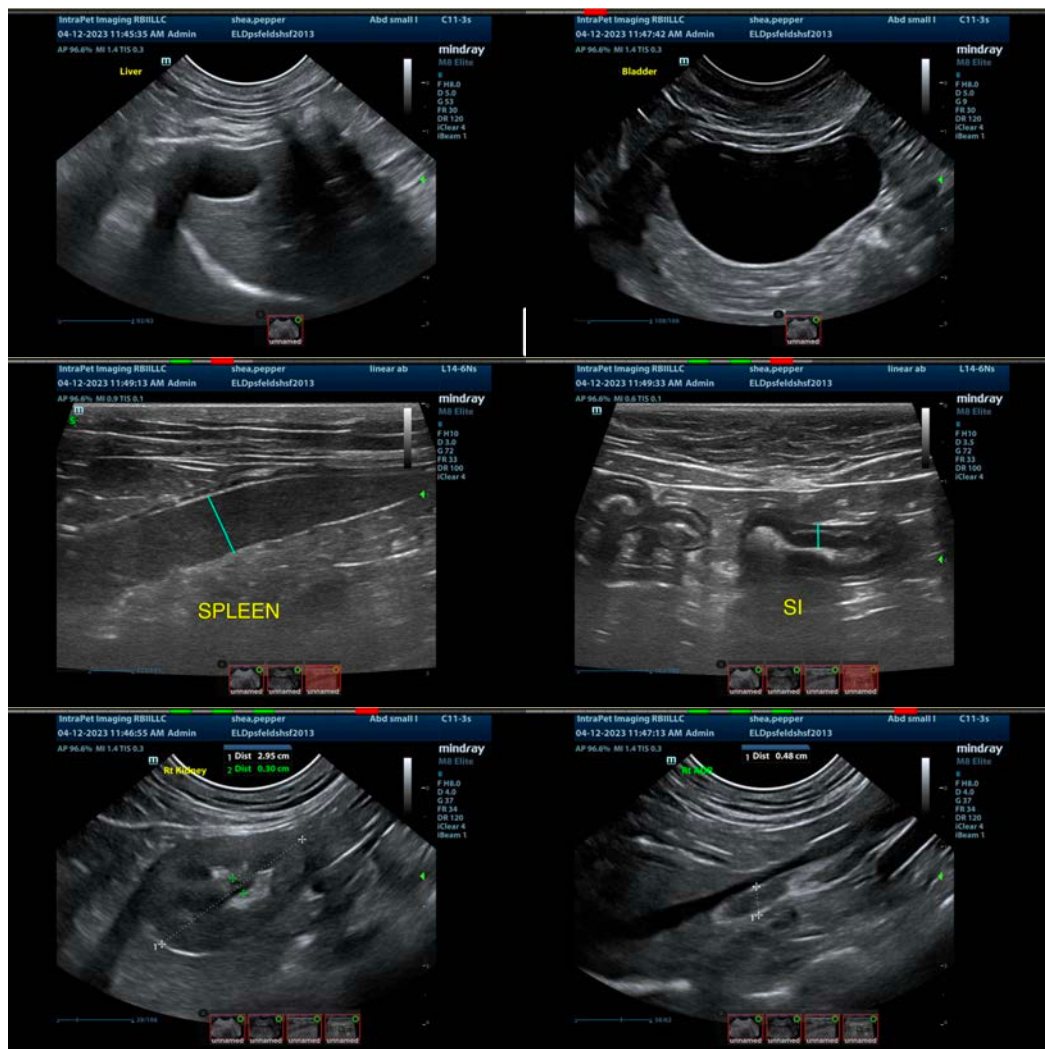
INTERPRETATION OF THE FINDINGS & FURTHER RECOMMENDATIONS

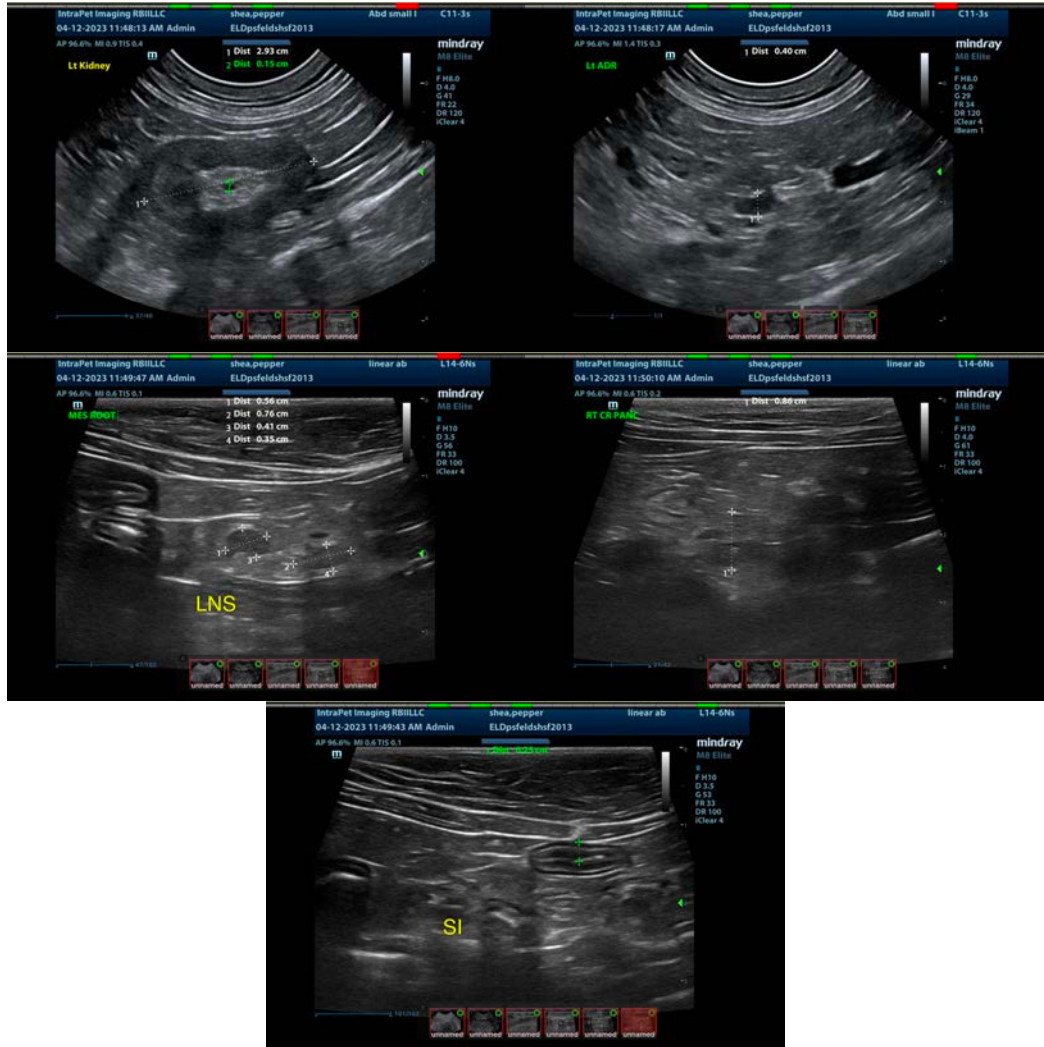
The changes in the kidneys are most consistent with age related chronic renal disease. No focal lesions are visualized. No stones or mass lesions, etc. Recommend a urinalysis, culture, and blood pressure to obtain a baseline.

The pancreas is slightly prominent and mottled with no overt inflammation. This is likely most consistent with previous episodes of pancreatic inflammation. Additionally, the muscularis layer of the small intestine is slightly prominent. This can be a normal finding in some older cats, but if there is significant GI disease present, this could be an indicator of a primary enteropathy.

The mesenteric lymph nodes are slightly prominent and visible. Recommend continued monitoring.

No focal lesions are visualized associated with the urinary bladder to explain the hematuria reported. Consider possible iatrogenic hemorrhage at the time of cystocentesis. Correlate with a free catch urinalysis.





The information and recommendations provided are based on the images presented by the referring veterinarian/sonographer. No evaluation can be communicated regarding pathology that was not visible in the image/video clips provided.

Thank you for this referral. If the clinical or image interpretation does not parallel your findings or if I can be of any further assistance please contact me.

Kathleen Sennello DVM,MS, Diplomate ACVIM (Small animal Internal Medicine)
 kathleen.sennello@sonopath.com