



**PATIENT PRESENTING CLINICAL SIGNS**

Hermione Sweeney

Constant vomiting for approximately 10 days. Unable to keep anything down. Used to vomit occasionally on empty stomach but now so much worse. Has been on Omeprazole.

**SPECIES**

Canine

Abnormal PE/Chem/CBC/UA Results: CPL normal, ALT 865, ALKP 1959, GGT 44, Cholesterol 12.6, RBCs 9.6, MCV 57.3, MCH 20.7.

**BREED**

Collie X

**ULTRASONOGRAPHIC EXAMINATION OF THE ABDOMEN**

**Urinary System**

**SEX**

Spayed Female

The urinary bladder is mildly to moderately distended with anechoic urine. The Bladder wall appears somewhat irregular and thickened, particularly in the ventral wall, where there is the appearance of a mass effect measuring approximately 1.18 cm x 2.53 cm. This appears to extend from the mid body of the bladder towards the trigone, where there is a focal mass effect measuring 0.76 cm x 1.38 cm. There is some mild irregularity on the dorsal wall as well, with wall thickness being 0.61 cm. No calculi are observed.

**AGE**

11 Years

**WEIGHT**

31.9 kg

The left kidney has a normal shape and size (6.44 cm). Overall echogenicity is normal with adequate corticomedullary distinction and a typical 1:3 cortex:medulla ratio. There is no evidence of focal perinephric inflammation or effusion. There is no evidence of pyelectasia, nephroliths, infarcts or hydroureter. Renal vasculature is normal.

**INTERPRETED BY**

Kathleen Sennello DVM,  
MS, Diplomate ACVIM  
(Small Animal Internal  
Medicine)

The right kidney has a normal shape and size (6.6 cm). Overall echogenicity is normal with adequate corticomedullary distinction and a typical 1:3 cortex:medulla ratio. There is no evidence of focal perinephric inflammation or effusion. There is no evidence of pyelectasia, nephroliths, infarcts or hydroureter. Renal vasculature is normal.

**IMAGING PERFORMED BY**

Crystal Hill

**Adrenal Glands**

The left adrenal gland is normal in size measuring 0.53 cm at the caudal pole. It is observed in its normal position cranial to the left renal artery. It is normal in appearance (uniformly hypoechoic) and shape with no evidence of a mass effect.

**HOSPITAL NAME**

Buck Animal Hospital

The right adrenal gland is normal in size measuring 0.72 cm at the caudal pole. It is observed in its normal position between the cranial aspect of the right kidney and the caudal vena cava. It is normal in appearance (uniformly hypoechoic) and shape with no evidence of a mass effect.

**REFERRING VET**

Dr. Sommers

**Spleen**

The spleen is subjectively normal in size, echotexture is homogenous, and the splenic capsule is smooth with no irregularities. The blood flow through the hilus and splenic parenchyma appears normal. No focal parenchymal abnormalities are visualized.

**INVOICE**

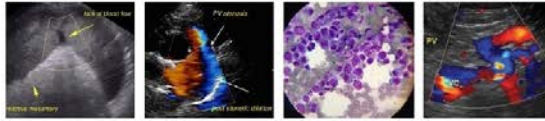
46615

**Liver**

**DATE**

4/12/23

The liver is subjectively normal in size, and echogenicity with smooth peripheral margins. The parenchyma is homogenous echotexture. The visible portions of the vasculature and biliary tract appear normal. No focal nodules or cystic lesions are observed.



**PATIENT**

Hermione Sweeney

The gallbladder lumen is moderately distended. The wall of the gall bladder is not thickened and has a smooth mucosal surface. Luminal contents are mild and primarily anechoic. The cystic and common bile ducts are normal/not visible.

**SPECIES**

Canine

**Gastrointestinal**

**BREED**

Collie X

The stomach contains minimal luminal contents. It measures at a normal thickness of <0.7cm with some variability due to the presence of rugal folds. The distinction of the gastric wall layers is adequate and there is no impression of reduced peristaltic activity. No masses or focal lesions were observed.

**SEX**

Spayed Female

The visualized areas of duodenum, jejunum and ileum have a relatively uniform diameter with minimal fluid distension. Wall thickness is normal. Bowel loops follow a curvilinear path with distinct wall layering maintaining the typical 1:3 muscularis:mucosa layer ratio. Jejunum wall measures 0.40 cm. Visualized peristalsis appears appropriate. There were no focal lesions consistent with obstruction or a mass effect observed.

**AGE**

11 Years

The ileocecal junction was visualized and exhibited normal intact wall layering and is subjectively of normal thickness. Sections of colon are visualized with formed fecal material and gas shadowing distally. There is no observed focal or generalized colon wall thickening or loss of layering.

**WEIGHT**

31.9 kg

**Pancreas**

**INTERPRETED BY**

Kathleen Sennello DVM,  
MS, Diplomate ACVIM  
(Small Animal Internal  
Medicine)

There is a significant amount of inflammation visualized medial to the spleen in the region of the left limb of the pancreas. In this area, hypoechoic mottled pancreas is visualized. These findings are most consistent with moderate pancreatitis. No evidence of nodules or cystic lesions are visualized.

**Free Abdomen**

There is a scant amount of free abdominal fluid. No lymphadenopathy. The omentum is diffusely hyperechoic, particularly irregular and mottled in the region of the left limb of the pancreas.

**IMAGING PERFORMED BY**

Crystal Hill

**ULTRASONOGRAPHIC FINDINGS**

**HOSPITAL NAME**

Buck Animal Hospital

- Thickened, irregular ventral urinary bladder wall – Findings are concerning for a bladder mass. Primary differential would include a transitional cell carcinoma, other.
- Severe inflammation and mottled mesentery with a hypoechoic pancreas in the region of the left limb – The pancreatic changes are most consistent with moderate/severe pancreatitis/pancreatic inflammation. Recommend fPLI testing and continued monitoring for improvement or possible development of a pancreatic abscess. Consider fine needle aspirate if not improving.

**REFERRING VET**

Dr. Sommers

**INVOICE**

46615

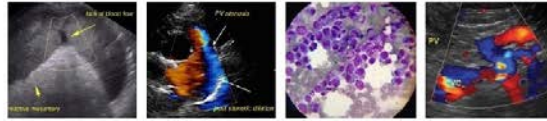
- Scant free abdominal fluid.

**DATE**

4/12/23

**INTERPRETATION OF THE FINDINGS & FURTHER RECOMMENDATIONS**

There is a large amount of inflammation in the abdomen, and this appears most severe and irregular in the region of the left limb of the pancreas, which is hypoechoic and prominent. These findings are suggestive of moderate pancreatitis, and some free abdominal fluid is visualized. Correlate these findings with a quantitative cPLI level, and recommend aggressive treatment for pancreatitis, with continued monitoring +/- serial imaging if not responding to therapy, as ingested foreign material cannot be definitively ruled out.



**PATIENT**

Hermione Sweeney

No focal lesions are visualized associated with the liver, and the gallbladder appears within normal limits. The liver enzyme elevations could be secondary to the pancreatitis (reactive hepatitis) or could be a concurrent primary hepatopathy. The liver enzyme elevations seem subjectively more elevated than I would expect for a reactive hepatopathy. Consider the following:

**SPECIES**

Canine

- Consider close evaluation of history for possible toxic changes examine medications, diet, dietary indiscretion etc...

**BREED**

Collie X

- Consider PCR on urine/serum for leptospirosis (if not on antibiotics)/serology if recent antibiotic history

**SEX**

Spayed Female

- If not already done, consider pre and post prandial bile acids to evaluate liver function
- If the ALP is significantly elevated relative to the ALT and symptoms consistent with Cushing's are present, consider adrenal function testing (ACTH stim)

**AGE**

11 Years

- Consider Fine needle aspirate if round cell neoplasia is on your differentia list (25 g needle, normal coags)

**WEIGHT**

31.9 kg

- If no response to supportive care (Denamarin, fluids, antibiotics, +/- ursodiol etc.) Consider liver biopsy with samples obtained for histopathology, culture, and copper levels.

**INTERPRETED BY**

Kathleen Sennello DVM,  
MS, Diplomate ACVIM  
(Small Animal Internal  
Medicine)

Recommend three view thoracic radiographs to evaluate for possible concurrent thoracic disease/involvement.

**IMAGING PERFORMED BY**

Crystal Hill

There is irregular tissue associated with the urinary bladder wall. This is concerning for a possible mass effect. When this patient is feeling better, recommend a urinalysis and culture. If an infection is present, recommend treatment of that and repeat ultrasound to see if any of these lesions have resolved. Otherwise, consider a traumatic catheterization or cystoscopy to obtain biopsies from the bladder wall.

**HOSPITAL NAME**

Buck Animal Hospital

Additionally, you could consider a urine BRAF test. If this test is positive, this would increase the likelihood that the changes observed are due to a transitional cell carcinoma. You can get false positives with an active sediment, and a negative test result is inconclusive and requires additional evaluation.

**REFERRING VET**

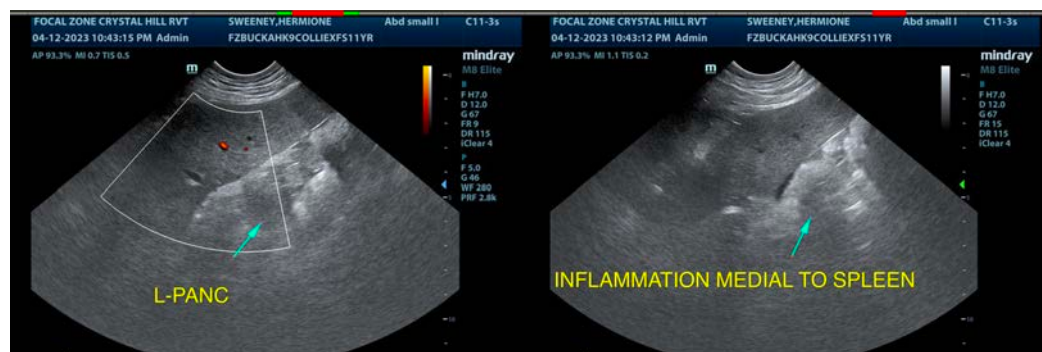
Dr. Sommers

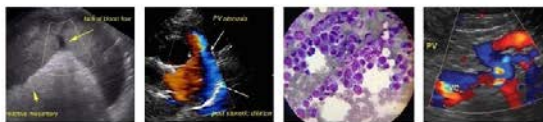
**INVOICE**

46615

**DATE**

4/12/23





**PATIENT**

Hermione Sweeney

**SPECIES**

Canine

**BREED**

Collie X

**SEX**

Spayed Female

**AGE**

11 Years

**WEIGHT**

31.9 kg

**INTERPRETED BY**

Kathleen Sennello DVM,  
MS, Diplomate ACVIM  
(Small Animal Internal  
Medicine)

**IMAGING  
PERFORMED BY**

Crystal Hill

**HOSPITAL NAME**

Buck Animal Hospital

**REFERRING VET**

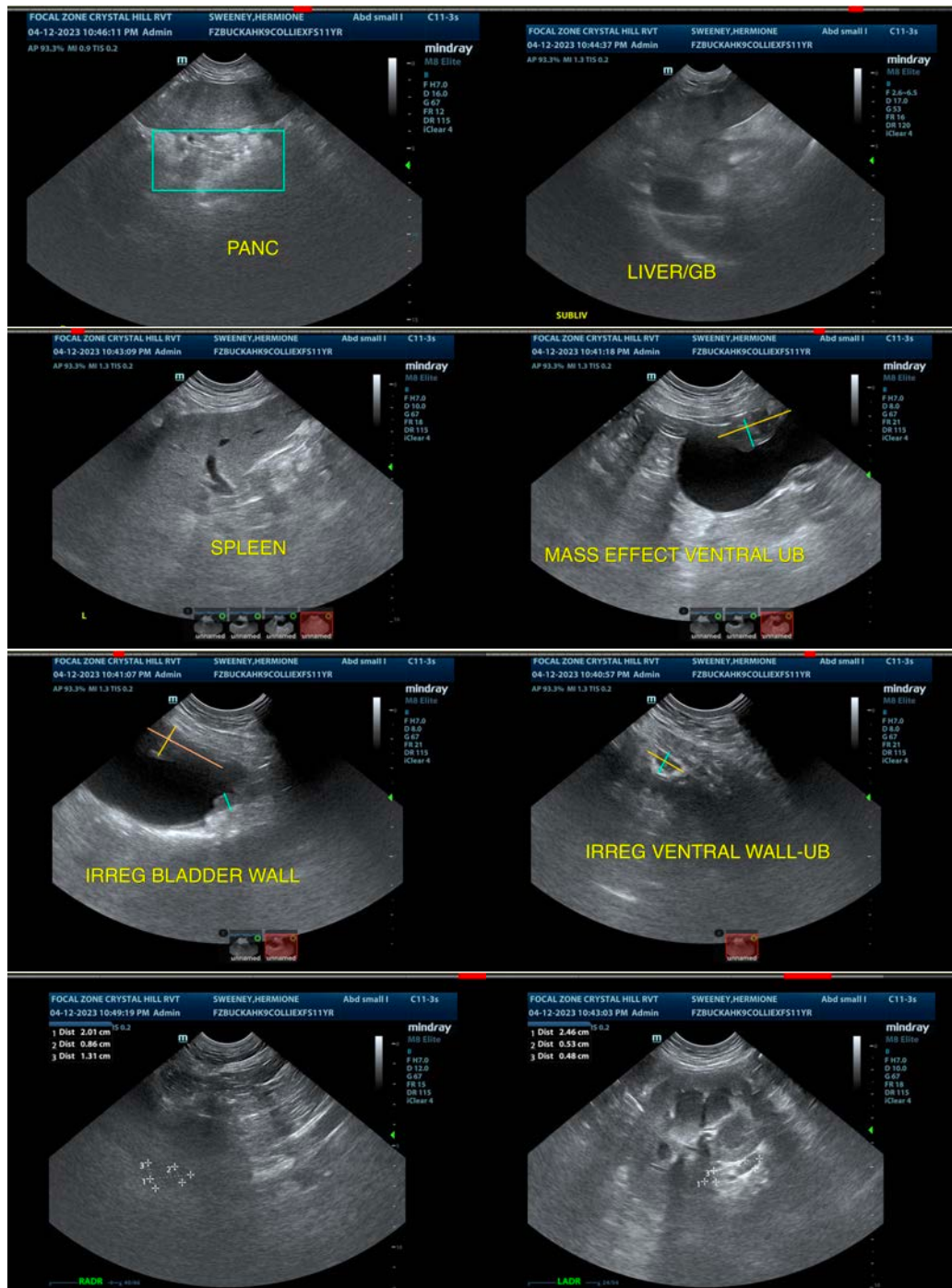
Dr. Sommers

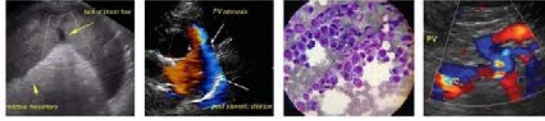
**INVOICE**

46615

**DATE**

4/12/23





**PATIENT**

Hermione Sweeney

**SPECIES**

Canine

**BREED**

Collie X

**SEX**

Spayed Female

**AGE**

11 Years

**WEIGHT**

31.9 kg

**INTERPRETED BY**

Kathleen Sennello DVM,  
MS, Diplomate ACVIM  
(Small Animal Internal  
Medicine)

**IMAGING  
PERFORMED BY**

Crystal Hill

**HOSPITAL NAME**

Buck Animal Hospital

**REFERRING VET**

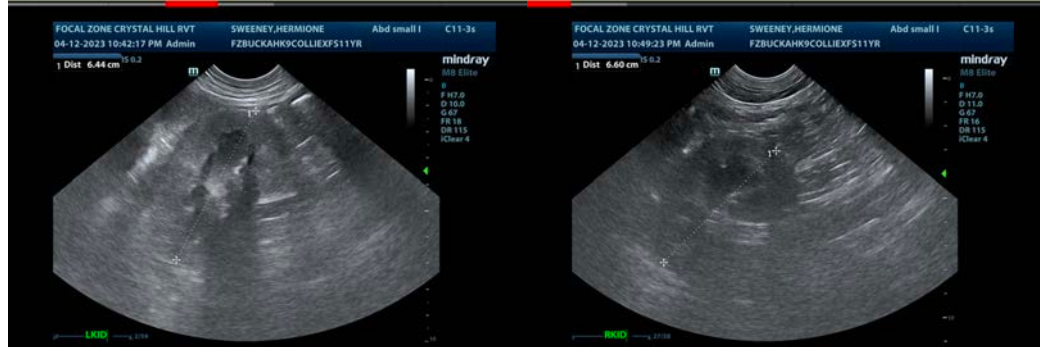Dr. Sommers

**INVOICE**

46615

**DATE**

4/12/23



The information and recommendations provided are based on the images presented by the referring veterinarian/sonographer. No evaluation can be communicated regarding pathology that was not visible in the image/video clips provided.

Thank you for this referral. If the clinical or image interpretation does not parallel your findings or if I can be of any further assistance please contact me.

Kathleen Sennello DVM,MS, Diplomate ACVIM (Small animal Internal Medicine)

kathleen.sennello@sonopath.com