



**PATIENT**

Annie Reese

**SPECIES**

Canine

**BREED**

Australian Shep X

**SEX**

Spayed Female

**AGE**

6 Years

**WEIGHT**

6.2 kg

**INTERPRETED BY**

Kathleen Sennello DVM,  
MS, Diplomate ACVIM  
(Small Animal Internal  
Medicine)

**IMAGING PERFORMED BY**

Amber Goldman, RVT

**HOSPITAL NAME**

Appalachian Vet  
Ultrasound

**REFERRING VET**

Dr. Wolverton

**INVOICE**

46567

**DATE**

4/12/23

**PRESENTING CLINICAL SIGNS**

P presents with v+, lethargic, not eating on Sunday p got sick and v+ their food, since then p has been v+ around 2-3x a day. it appears to be like yellow bile p also gets car sick, v+ on the way here o doesn't think p got into anything or ingested a fb has sleeping all day and is not showing any interest in chasing her ball like usual NUTD, no preventative

Abnormal PE/Chem/CBC/UA Results: CREA 13.3 mg/dL 0.5 - 1.8 HIGH BUN > 130 mg/dL 7 - 27 HIGH PHOS > 16.1 mg/dL 2.5 - 6.8 HIGH Na 143 mmol/L 144 - 160 LOW Cl 103 mmol/L 109 - 122 LOW MCHC 38.0 g/dL 32.0 - 37.9 HIGH RETIC 4.8 K/ $\mu$ L 10.0 - 110.0 LOW LEPTO Positive

**ULTRASONOGRAPHIC EXAMINATION OF THE ABDOMEN**

**Urinary System**

The urinary bladder is moderately distended with anechoic urine. The bladder wall appears slightly thickened and irregular with some dependent debris and focal mineralizations most consistent with small stones/sandy debris.

The left kidney has a normal shape and size (3.94 cm) with mild pyelectasia at 0.25 cm and free fluid around the kidney. Overall echogenicity is slightly hyperechoic with poor corticomedullary distinction and a typical 1:3 cortex:medulla ratio. There is no evidence of nephroliths, infarcts or hydronephrosis. Renal vasculature is normal.

The right kidney has a normal shape and size (4.56 cm) with fluid around the kidney. Overall echogenicity is slightly hyperechoic with poor corticomedullary distinction and a typical 1:3 cortex:medulla ratio. There is no evidence of pyelectasia, nephroliths, infarcts or hydronephrosis. Renal vasculature is normal.

**Adrenal Glands**

The left adrenal gland is normal in size measuring 0.40 cm at the caudal pole. It is observed in its normal position cranial to the left renal artery. It is normal in appearance (uniformly hypoechoic) and shape with no evidence of a mass effect.

The right adrenal gland is normal in size measuring 0.37 cm at the caudal pole. It is observed in its normal position between the cranial aspect of the right kidney and the caudal vena cava. It is normal in appearance (uniformly hypoechoic) and shape with no evidence of a mass effect.

**Spleen**

The spleen is subjectively normal in size, echotexture is homogenous, and the splenic capsule is smooth with no irregularities. The blood flow through the hilus and splenic parenchyma appears normal. No focal parenchymal abnormalities are visualized.

**Liver**

The liver is subjectively normal in size, and echogenicity with smooth peripheral margins. The parenchyma is homogenous echotexture. The visible portions of the vasculature and biliary tract appear normal. No focal nodules or cystic lesions are observed.

The gallbladder lumen is moderately distended. The wall of the gall bladder is not thickened and has a smooth mucosal surface. Luminal contents are mild and primarily anechoic. The cystic and common bile ducts are normal/not visible.



**PATIENT**

Annie Reese

**SPECIES**

Canine

**BREED**

Australian Shep X

**SEX**

Spayed Female

**AGE**

6 Years

**WEIGHT**

6.2 kg

**INTERPRETED BY**

Kathleen Sennello DVM,  
MS, Diplomate ACVIM  
(Small Animal Internal  
Medicine)

**IMAGING  
PERFORMED BY**

Amber Goldman, RVT

**HOSPITAL NAME**

Appalachian Vet  
Ultrasound

**REFERRING VET**

Dr. Wolverton

**INVOICE**

46567

**DATE**

4/12/23

**Gastrointestinal**

The stomach contains minimal luminal contents. It measures at a normal thickness of 0.36 cm with some variability due to the presence of rugal folds. The distinction of the gastric wall layers is adequate and there is no impression of reduced peristaltic activity. No masses or focal lesions were observed.

The visualized areas of duodenum, jejunum and ileum have a relatively uniform diameter with minimal fluid distension. Wall thickness is normal. Bowel loops follow a curvilinear path with distinct wall layering maintaining the typical 1:3 muscularis:mucosa layer ratio. Duodenum wall measures 0.35 cm. Jejunum wall measures 0.22 cm. Visualized peristalsis appears appropriate. There were no focal lesions consistent with obstruction or a mass effect observed.

The ileocecal junction was visualized and exhibited normal intact wall layering and is subjectively of normal thickness. Sections of colon are visualized with formed fecal material and gas shadowing distally. There is no observed focal or generalized colon wall thickening or loss of layering.

**Pancreas**

The area of the pancreas is normal and isoechoic to surrounding mesentery. There is no evidence of nodules or cystic lesions. There is no evidence of regional mesenteric inflammation or fluid.

**Free Abdomen**

There is a small to moderate amount of anechoic free fluid. No lymphadenopathy. The omentum is of normal echogenicity.

**ULTRASONOGRAPHIC FINDINGS**

- Mildly thickened urinary bladder wall with echogenic debris and small mineralizations/stones – Findings could be consistent with cystitis. Recommend a urinalysis and culture.
- Decreased corticomedullary distinction in both kidneys – Mild loss of corticomedullary distinction in both kidneys could be consistent with chronic degenerative disease or interstitial nephrosis.
- Free abdominal fluid – This could be consistent with fluid overload due to anuric renal failure or inflammation, etc.

**INTERPRETATION OF THE FINDINGS & FURTHER RECOMMENDATIONS**

The changes observed in the kidneys are relatively mild. There is a small amount of debris in the urinary bladder. Recommend a urinalysis and culture to look for evidence of cystitis/pyelonephritis. Additionally, recommend quantitating urine output, as there is concern for fluid overload with the free abdominal fluid noted. Additionally, with Leptospirosis you can sometimes see perinephric fluid and inflammation. There is no significant inflammation noted, but there is some fluid. Correlate your positive test results with vaccination history. If antibiotics haven't been started, consider a PCR on the urine.



**PATIENT**

Annie Reese

**SPECIES**

Canine

**BREED**

Australian Shep X

**SEX**

Spayed Female

**AGE**

6 Years

**WEIGHT**

6.2 kg

**INTERPRETED BY**

Kathleen Sennello DVM,  
MS, Diplomate ACVIM  
(Small Animal Internal  
Medicine)

**IMAGING  
PERFORMED BY**

Amber Goldman, RVT

**HOSPITAL NAME**

Appalachian Vet  
Ultrasound

**REFERRING VET**

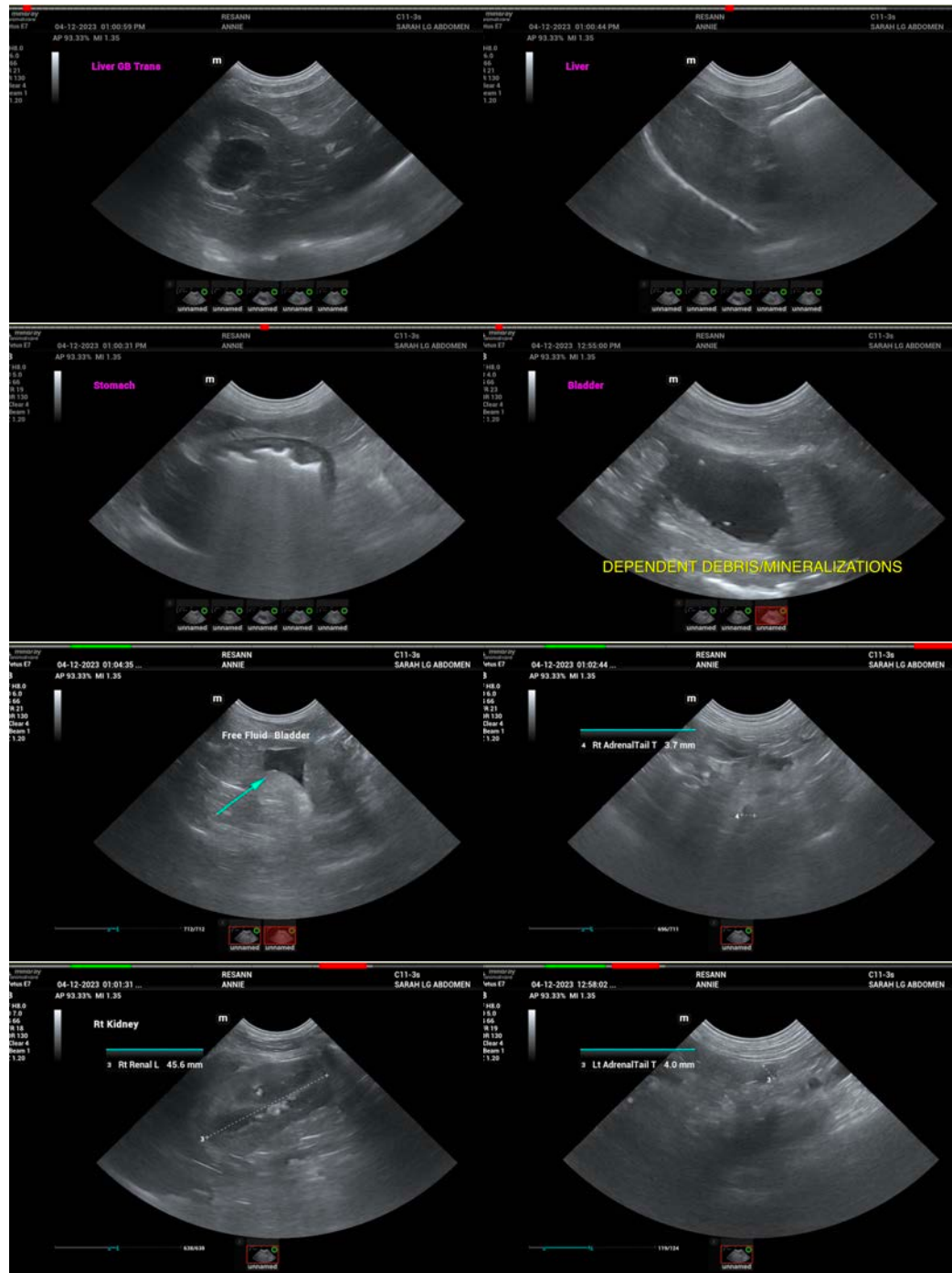
Dr. Wolverton

**INVOICE**

46567

**DATE**

4/12/23





**PATIENT**

Annie Reese

**SPECIES**

Canine

**BREED**

Australian Shep X

**SEX**

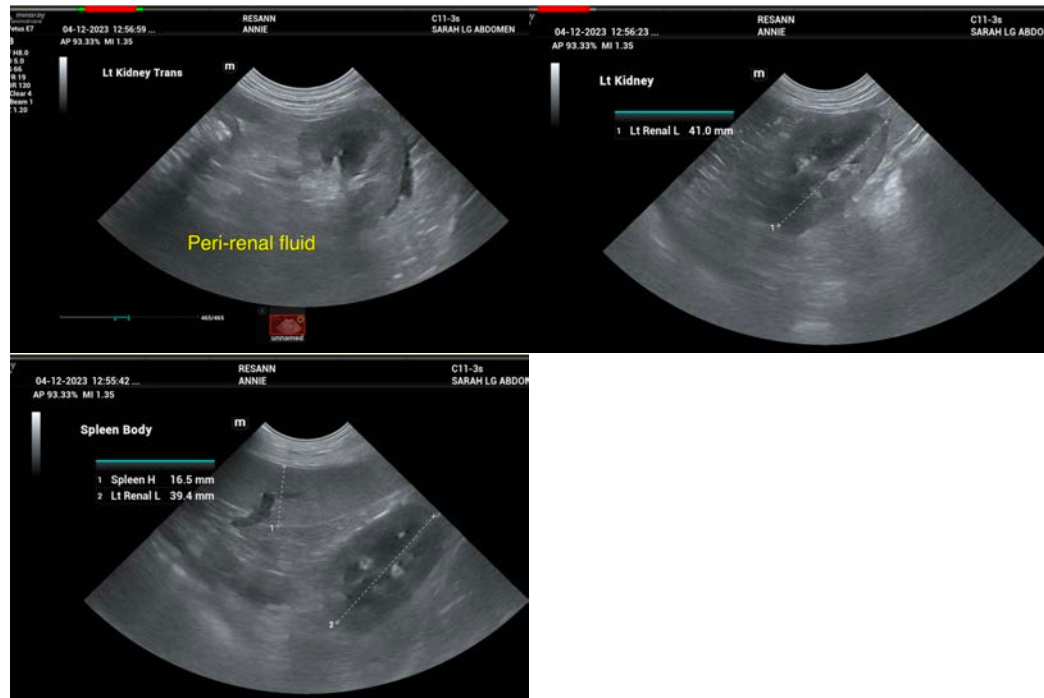
Spayed Female

**AGE**

6 Years

**WEIGHT**

6.2 kg



**INTERPRETED BY**

Kathleen Sennello DVM,  
MS, Diplomate ACVIM  
(Small Animal Internal  
Medicine)

The information and recommendations provided are based on the images presented by the referring veterinarian/sonographer. No evaluation can be communicated regarding pathology that was not visible in the image/video clips provided.

Thank you for this referral. If the clinical or image interpretation does not parallel your findings or if I can be of any further assistance please contact me.

**IMAGING PERFORMED BY**

Amber Goldman, RVT

Kathleen Sennello DVM,MS, Diplomate ACVIM (Small animal Internal Medicine)

kathleen.sennello@sonopath.com

**HOSPITAL NAME**

Appalachian Vet  
Ultrasound

**REFERRING VET**

Dr. Wolverton

**INVOICE**

46567

**DATE**

4/12/23