

**DATE PRESENTING CLINICAL SIGNS**

4/12/22 Has had chronic diarrhea since being a kitten. Treated for multiple parasites but continues to have diarrhea.

**PATIENT**

Current Medications: None listed.  
Date of Previous IntraPet Ultrasound: No previous.  
Leo Smith Sedation: Not required to complete full diagnostic ultrasound.  
Stat Report: Not requested.

**SPECIES**

Feline

**ULTRASONOGRAPHIC EXAMINATION OF THE ABDOMEN****Urinary System****BREED**

The urinary bladder is moderately distended with anechoic urine. The Bladder wall, trigone, ureteral papillae and visible urethra (to a depth of 2cm) appear normal with no evidence of wall thickening, mucosal irregularities, masses or cystic calculi.

DSH

**SEX**

Neutered Male

The left kidney has a normal shape and size (4.09 cm). Overall echogenicity is normal with adequate corticomedullary distinction and a typical 1:3 cortex:medulla ratio. There is no evidence of perinephric inflammation or effusion. There is no evidence of pyelectasia, nephroliths, infarcts or hydroureter. Renal vasculature is normal.

**AGE**

9/10/21

The right kidney is normal in size (3.31 cm), but slightly irregular in shape. Overall echogenicity is normal with adequate corticomedullary distinction and a typical 1:3 cortex:medulla ratio. There is no evidence of perinephric inflammation or effusion. There is no evidence of pyelectasia, nephroliths or hydroureter. Renal vasculature is normal. The caudal pole of the right kidney appears somewhat irregular, most consistent with either a congenital irregularity or a previous infarct.

**WEIGHT**

9.2 Pounds

**INTERPRETED BY**

Kathleen Sennello DVM,  
MS, Diplomate ACVIM  
(Small Animal Internal  
Medicine)

**Adrenal Glands**

The left adrenal gland is normal in size measuring 0.36 cm at the caudal pole. It is observed in its normal position cranial to the left renal artery. It is normal in appearance (uniformly hypoechoic) and shape with no evidence of a mass effect.

The region of the right adrenal (between right cranial kidney and vena cava) is unremarkable, but the adrenal is not distinctly visualized. No evidence of a mass effect.

**IMAGING PERFORMED BY**

Rachel Brilhart RDMS

**HOSPITAL NAME**

Homeward Bound VS

**Spleen**

The spleen is borderline large in size (1.02 cm in width at the level of the hilus), echotexture is homogenous, and the splenic capsule is smooth with no irregularities. The blood flow through the hilus and splenic parenchyma appears normal. No focal parenchymal abnormalities are visualized.

**REFERRING VET**

Dr. Vance

**Liver**

The liver is subjectively normal in size, and echogenicity with smooth peripheral margins. The parenchyma is homogenous echotexture. The visible portions of the vasculature and biliary tract appear normal. No focal nodules or cystic lesions are observed.

The gallbladder lumen is moderately distended. The wall of the gall bladder is not thickened and has a smooth mucosal surface. Luminal contents are primarily anechoic. The cystic and common bile ducts are normal/not visible.

**INVOICE**

36814

**Gastrointestinal**

The stomach contains minimal luminal contents. It measures at a normal thickness of <0.36cm with some variability due to the presence of rugal folds. The distinction of the gastric wall layers is adequate and there is no impression of reduced peristaltic activity. No masses or focal lesions were observed.

The visualized areas of duodenum, jejunum and ileum have a relatively uniform diameter with minimal fluid distension. Wall thickness is normal. Bowel loops follow a curvilinear path with distinct wall layering maintaining the typical 1:3 muscularis:mucosa layer ratio. Jejunum wall measured 0.23 cm. Visualized peristalsis appears appropriate. There were no focal lesions consistent with obstruction or a mass effect observed.

The ileocecal junction was visualized and exhibited normal intact wall layering and is subjectively of normal thickness. Sections of colon are visualized with formed fecal material and gas shadowing distally. There is no observed focal or generalized colon wall thickening or loss of layering.

### ***Pancreas***

The pancreas is prominent and hypoechoic as compared to the surrounding isoechoic mesentery. There is no evidence of nodules or cystic lesions. Prominent pancreatic duct noted measuring 0.1 cm. There is no evidence of regional mesenteric inflammation or fluid.

### ***Free Abdomen***

Evaluation of the peritoneal cavity did not reveal any evidence of effusion. There are numerous prominent to enlarged mesenteric lymph nodes measuring 0.49, 0.49, and 0.87 cm. The omentum appears of increased echogenicity around the prominent lymph nodes.

## **PRIMARY FINDINGS**

- Prominent, hypoechoic pancreas – The pancreatic changes are most consistent with age-related parenchymal remodeling, potentially secondary to a prior inflammatory episode, early fibrosis or chronic pancreatitis.
- Mild mesenteric lymphadenopathy – The prominent abdominal lymph nodes are most consistent with reactive lymphadenitis or lymphoid hyperplasia. Neoplastic infiltration is considered less likely.

## **SECONDARY FINDINGS**

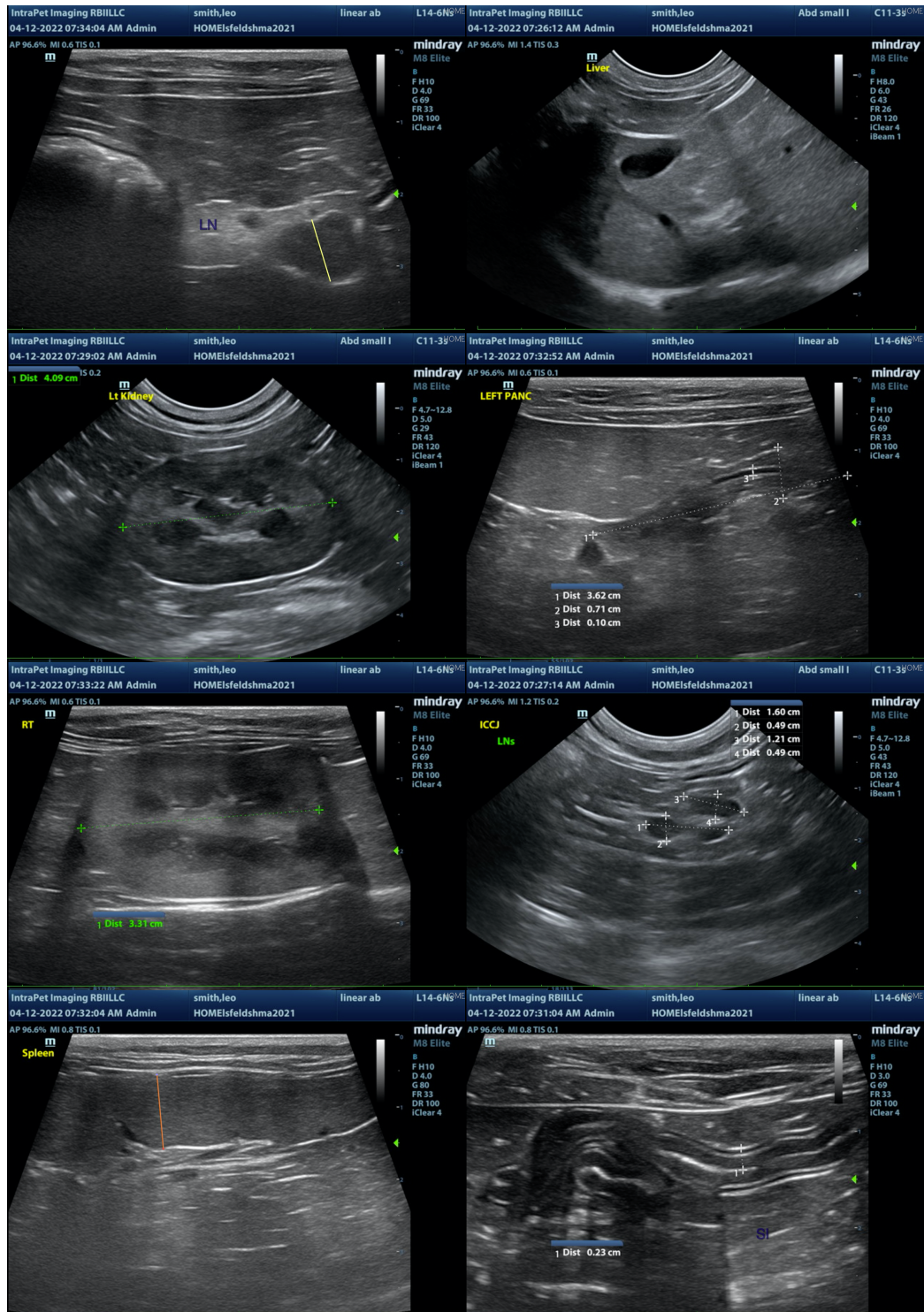
- Slightly irregular shape of the right kidney
- Borderline large spleen – The spleen appears normal and this is a relatively large cat, so this is likely within normal limits. A fine needle aspirate could be considered if lymphoma is high on your differential list.

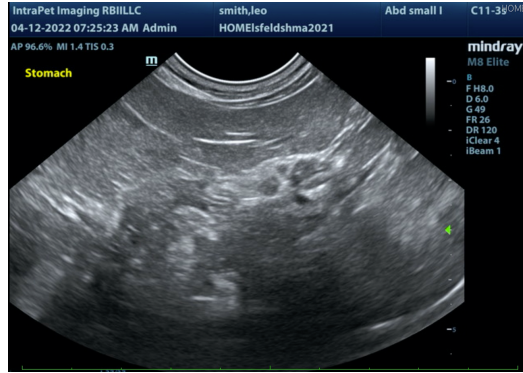## **INTERPRETATION OF THE FINDINGS & FURTHER RECOMMENDATIONS**

No focal bowel lesions are observed. Possible differentials to consider for chronic small bowel diarrhea in this young of a patient would include food allergy/dietary intolerance, GI parasitism (consider difficult to diagnose protozoal parasites such as tritrichomonas, etc.), dysbiosis, exocrine pancreatic insufficiency, etc.

- Consider a novel protein/hydrolyzed protein prescription diet
- Consider a GI panel to Texas A&M for a qualitative fPLI, TLI, cobalamin and folate to screen for exocrine pancreatic insufficiency, B12 deficiency, etc.
- Recommend chronic probiotic therapy.
- If not already done, consider screening for protozoal parasitism.

Additionally, you could consider screening for Addison's disease, evaluating a liver function test, and if FIP is high on your differential list based on bloodwork findings, a fine needle aspirate of a mesenteric lymph node and testing could be considered.





The information and recommendations provided are based on the images presented by the referring veterinarian/sonographer. No evaluation can be communicated regarding pathology that was not visible in the image/video clips provided.

Thank you for this referral. If the clinical or image interpretation does not parallel your findings or if I can be of any further assistance please contact me.

Kathleen Sennello DVM,MS, Diplomate ACVIM (Small animal Internal Medicine)  
kathleen.sennello@sonopath.com