

**DATE PRESENTING CLINICAL SIGNS**

4/12/22

Dog in good general health with no history of medical issues but dog is cryptorchid (unilateral) and owner would like to know location of retained testes to minimize surgery time. Make sure no other abnormalities are present in urinary/reproductive tract.

PATIENT

Brady Griffy

Date of Previous IntraPet Ultrasound: No previous.
Sedation: Not required to complete full diagnostic ultrasound.
Stat Report: Not requested.

SPECIES

Canine

LIMITED ULTRASONOGRAPHIC EXAMINATION**BREED**

Welsh Spaniel

The urinary bladder is moderately distended with a large amount of echogenic material present. The Bladder wall, trigone, ureteral papillae and visible urethra (to a depth of 2cm) appear normal with no evidence of wall thickening, mucosal irregularities, masses or calculi. Echogenic debris of this type can be associated with small crystals, cellular debris and proteinaceous debris.

SEX

Intact Male

The prostate is large and hyperechoic for a normal intact male dog, measuring 2.02 cm in height in the sagittal view.

AGE

3/14/21

The left kidney has a normal shape and size (6.41 cm). Overall echogenicity is normal with adequate corticomedullary distinction and a typical 1:3 cortex:medulla ratio. There is no evidence of perinephric inflammation or effusion. There is no evidence of pyelectasia, nephroliths, infarcts or hydroureter. Renal vasculature is normal.

WEIGHT

54 Pounds

The right kidney has a normal shape and size (6.32 cm). Overall echogenicity is normal with adequate corticomedullary distinction and a typical 1:3 cortex:medulla ratio. There is no evidence of perinephric inflammation or effusion. There is no evidence of pyelectasia, nephroliths, infarcts or hydroureter. Renal vasculature is normal.

INTERPRETED BY

Kathleen Sennello DVM,
MS, Diplomate ACVIM
(Small Animal Internal
Medicine)

The right testicle is visualized in its normal location, measuring 3.38 cm in length. The left testicle is visualized and appears to be sliding back and forth in the inguinal canal.

IMAGING PERFORMED BY

Stephanie Pearce
RDCS, RVT

ULTRASONOGRAPHIC FINDINGS

- Left cryptorchid testicle – appears mobile in the inguinal canal.
- Large, hyperechoic prostate – most consistent with BPH or prostatitis.
- Large volume echogenic debris within the urinary bladder – recommend urinalysis and culture.

HOSPITAL NAME

Fork Vet Hospital

INTERPRETATION OF THE FINDINGS & FURTHER RECOMMENDATIONS

There is a very large amount of echogenic debris within the urinary bladder. Recommend urinalysis and culture. If this culture is positive, recommend treatment for prostatitis with a prolonged course of appropriate antibiotics and a probiotic.

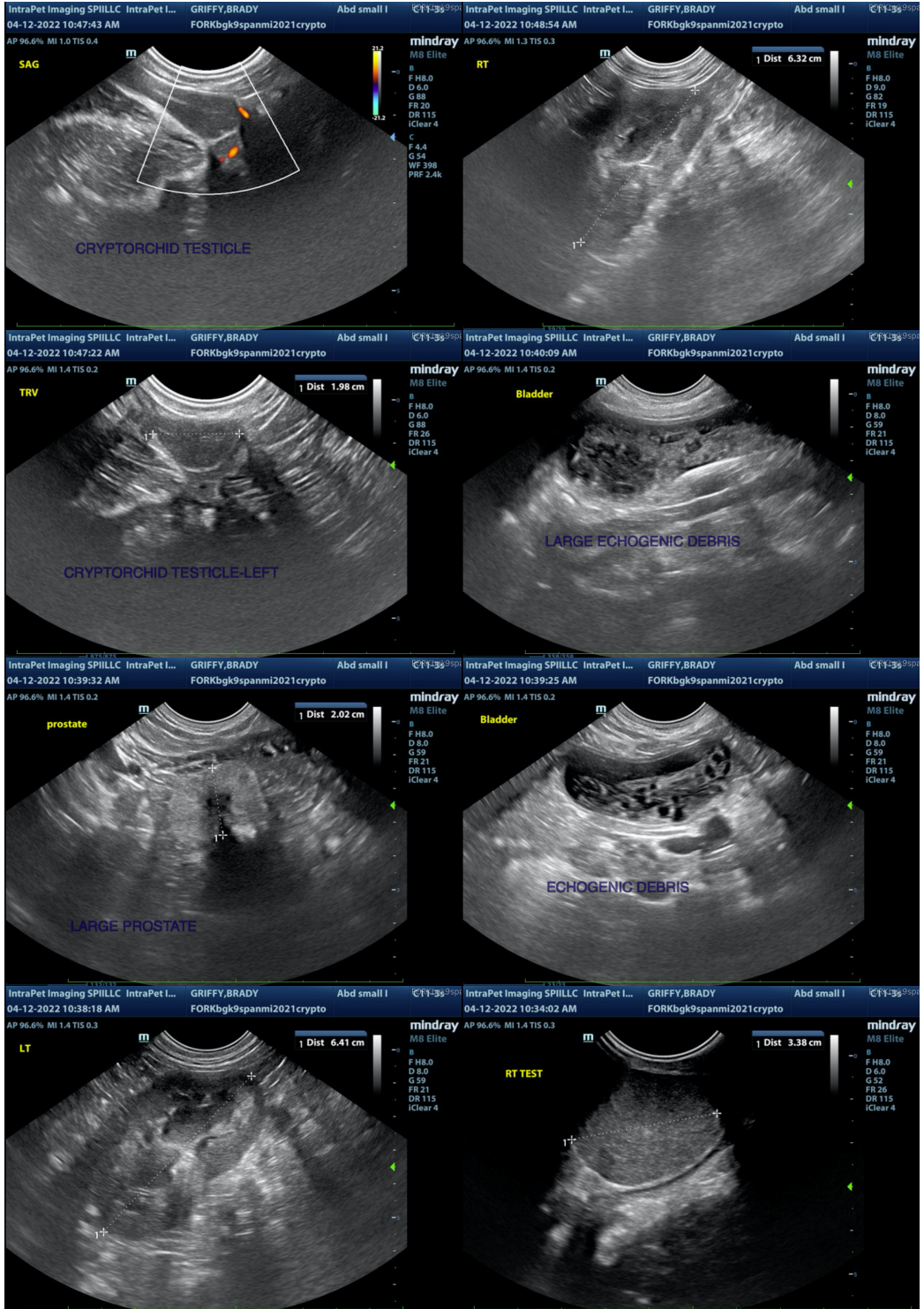
REFERRING VET

Dr. Doherty

The right testicle appears normal. The left appears to be a cryptorchid testicle and is visualized sliding back and forth through the inguinal canal.

INVOICE

36819



The information and recommendations provided are based on the images presented by the referring veterinarian/sonographer. No evaluation can be communicated regarding pathology that was not visible in the image/video clips provided.

Thank you for this referral. If the clinical or image interpretation does not parallel your findings or if I can be of any further assistance please contact me.

Kathleen Sennello DVM,MS, Diplomate ACVIM (Small animal Internal Medicine)
kathleen.sennello@sonopath.com