



PATIENT

Watson Lischka

SPECIES

Canine

BREED

Golden Retriever x
Collie

SEX

Neutered Male

AGE

9 Years

WEIGHT

22 kg

INTERPRETED BY

Kathleen Sennello DVM,
MS, Diplomate ACVIM
(Small Animal Internal
Medicine)

**IMAGING
PERFORMED BY**

Dr. Sarah Barthelemy

HOSPITAL NAME

Bridgeland Vet Clinic

REFERRING VET

Dr Elock

INVOICE

46572

DATE

4/11/23

PRESENTING CLINICAL SIGNS

Recurrent and very sporadic (maybe 2-3 per year) episodes of intense lip licking (almost compulsive for 1-2 hours) and hypersalivation. Will sometimes vomit during the episode or have diarrhea. Will also pace or seem restless during the episode. Started 2 years ago.

ULTRASONOGRAPHIC EXAMINATION OF THE ABDOMEN

Urinary System

The urinary bladder is moderately distended with anechoic urine. The Bladder wall, trigone, ureteral papillae and visible urethra (to a depth of 2cm) appear normal with no evidence of wall thickening, mucosal irregularities, masses or cystic calculi.

The prostate is normal in size (0.94 cm) and shape for this neutered male dog. The parenchyma is homogenous and the external margins are smooth. The prostatic urethra appears normal with no evidence of irregularity, invasion, mass effect or calculi.

The left kidney has a normal shape and size (5.32 cm). Overall echogenicity is normal with adequate corticomedullary distinction and a typical 1:3 cortex:medulla ratio. There is no evidence of focal perinephric inflammation or effusion. There is no evidence of pyelectasia, nephroliths, infarcts or hydroureter. Renal vasculature is normal.

The right kidney has a normal shape and size (5.55 cm). Overall echogenicity is normal with adequate corticomedullary distinction and a typical 1:3 cortex:medulla ratio. There is no evidence of focal perinephric inflammation or effusion. There is no evidence of pyelectasia, nephroliths, infarcts or hydroureter. Renal vasculature is normal.

Adrenal Glands

The left adrenal gland is normal in size measuring 0.58 cm at the caudal pole. It is observed in its normal position cranial to the left renal artery. It is normal in appearance (uniformly hypoechoic) and shape with no evidence of a mass effect.

The right adrenal gland is normal in size measuring 0.70 cm at the caudal pole. It is observed in its normal position between the cranial aspect of the right kidney and the caudal vena cava. It is normal in appearance (uniformly hypoechoic) and shape with no evidence of a mass effect.

Spleen

The spleen is subjectively normal in size, echotexture is homogenous, and the splenic capsule is smooth with no irregularities. The blood flow through the hilus and splenic parenchyma appears normal. No focal parenchymal abnormalities are visualized.

Liver

The liver is normal/borderline small in size, with normal echogenicity and smooth peripheral margins. The parenchyma is homogenous echotexture. The visible portions of the vasculature and biliary tract appear normal. No focal nodules or cystic lesions are observed.

The gallbladder lumen is moderately distended. The wall of the gall bladder is not thickened and has a smooth mucosal surface. Luminal contents are mild and primarily anechoic. The cystic and common bile ducts are normal/not visible.



PATIENT

Watson Lischka

SPECIES

Canine

BREED

Golden Retriever x
Collie

SEX

Neutered Male

AGE

9 Years

WEIGHT

22 kg

INTERPRETED BY

Kathleen Sennello DVM,
MS, Diplomate ACVIM
(Small Animal Internal
Medicine)

**IMAGING
PERFORMED BY**

Dr. Sarah Barthelemy

HOSPITAL NAME

Bridgeland Vet Clinic

REFERRING VET

Dr Elock

INVOICE

46572

DATE

4/11/23

Gastrointestinal

The stomach contains minimal luminal contents. It measures at a normal thickness of <0.7cm with some variability due to the presence of rugal folds. The distinction of the gastric wall layers is adequate and there is no impression of reduced peristaltic activity. No masses or focal lesions were observed.

The visualized areas of duodenum, jejunum and ileum have a relatively uniform diameter with minimal fluid distension. Wall thickness is normal. Bowel loops follow a curvilinear path with distinct wall layering maintaining the typical 1:3 muscularis:mucosa layer ratio. Duodenum wall measures 0.43 cm. Jejunum wall measures 0.34 cm. Visualized peristalsis appears appropriate. There were no focal lesions consistent with obstruction or a mass effect observed.

The ileocecal junction was visualized and exhibited normal intact wall layering and is subjectively of normal thickness. Sections of colon are visualized with formed fecal material and gas shadowing distally. There is no observed focal or generalized colon wall thickening or loss of layering.

Pancreas

The pancreas is normal and isoechoic to surrounding mesentery. There is no evidence of nodules or cystic lesions. There is no evidence of regional mesenteric inflammation or fluid.

Free Abdomen

Evaluation of the peritoneal cavity did not reveal any evidence of effusion, or subjective lymphadenomegaly. The Medial iliac nodes appear normal and there was no evidence of a caudal aortic thrombus at the bifurcation. The omentum is of normal uniform echogenicity.

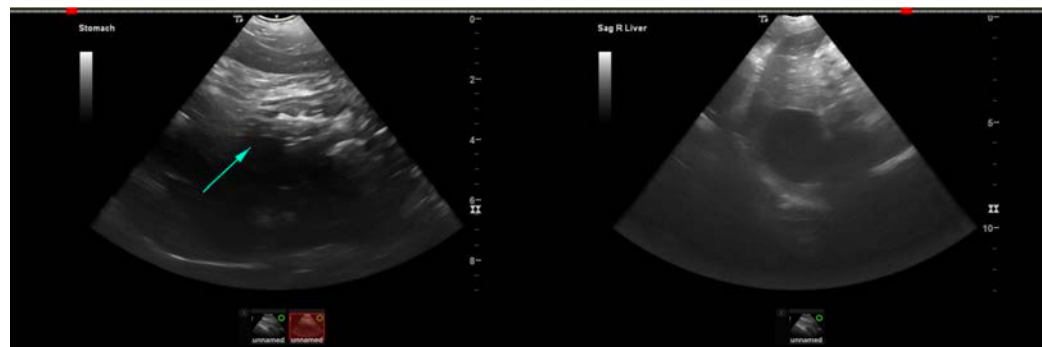
ULTRASONOGRAPHIC FINDINGS

- Borderline small liver – The liver parenchyma appears relatively normal. I suspect this is due to this being a deep chested dog. Consider a liver function test if there is concern.

INTERPRETATION OF THE FINDINGS & FURTHER RECOMMENDATIONS

No focal lesions are visualized to associate with the episodes of licking reported. Unfortunately, significant GI disease can still be present despite lack of significant ultrasonographic lesions. In this situation, I would also consider the possibility of focal seizures and recommend videoing an episode and having it reviewed by a neurologist in case anti-seizure therapy is warranted.

If additional evaluation for possible GI disease is desired, I would consider a GI panel to Texas A&M for a qualitative PLI, TLI, cobalamin and folate. Additionally, you could consider a change to a hydrolyzed protein or novel protein prescription diet, although I would suspect food allergy symptoms to be more consistent, unless these episodes can be linked to a specific intermittent treat, etc. Upper GI endoscopy could be considered during these episodes to look for evidence of inflammation, ulceration, etc.





PATIENT

Watson Lischka

SPECIES

Canine

BREED

Golden Retriever x
Collie

SEX

Neutered Male

AGE

9 Years

WEIGHT

22 kg

INTERPRETED BY

Kathleen Sennello DVM,
MS, Diplomate ACVIM
(Small Animal Internal
Medicine)

**IMAGING
PERFORMED BY**

Dr. Sarah Barthelemy

HOSPITAL NAME

Bridgeland Vet Clinic

REFERRING VET

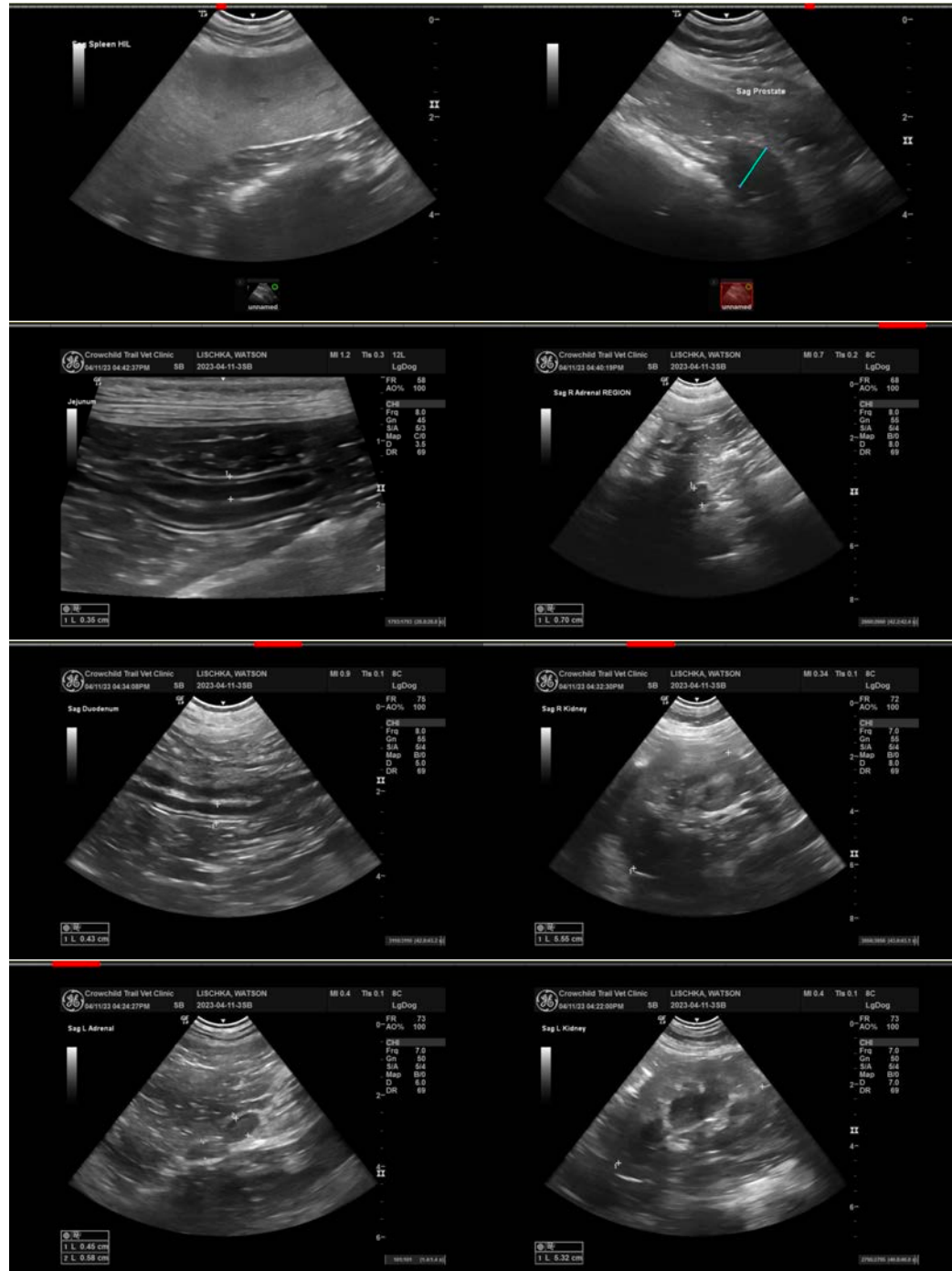
Dr Elock

INVOICE

46572

DATE

4/11/23



The information and recommendations provided are based on the images presented by the referring veterinarian/sonographer. No evaluation can be communicated regarding pathology that was not visible in the image/video clips provided.

Thank you for this referral. If the clinical or image interpretation does not parallel your findings or if I can be of any further assistance please contact me.

Kathleen Sennello DVM,MS, Diplomate ACVIM (Small animal Internal Medicine)

kathleen.sennello@sonopath.com