



PATIENT PRESENTING CLINICAL SIGNS

Scooter Walter

SPECIES

Canine

BREED

Chihuahua X

SEX

Neutered Male

No sedation- Squirmy and panting- Becomes cyanotic easily during scan but recovers quickly- History of heart disease and collapsing trachea. Last radiographs 1/18/23 showed redundant dorsal tracheal membrane, normal cardiovascular structures, moderate to severe hepatomegaly, and mild diffuse bronchointerstitial lung pattern. History of liver value elevations (continuing to rise) and proteinuria. Please compare to last ultrasound dated 8/16/22. MEDS: Enalapril 5 mg tablet: 2 tablets q24hrs; Hydrocodone 1/4 tab BID, Ursodiol 70 mg SID, Pimobendan 1.25 mg BID, Heartgard and Nexgard, Milk Thistle 175mg 1 cap SID AM

Abnormal PE/Chem/CBC/UA Results: 3/7/23: BUN slightly elevated at 35, TP 7.8, ALT 192, ALP 1547, very mild thrombocytosis, USG 1.041, UPC 2.9; Labwork was repeated today and not yet available - will be back 4/12/23. BP 132mmHg

ULTRASONOGRAPHIC EXAMINATION OF THE ABDOMEN

AGE

11/6/21

WEIGHT

6.3 kg

Urinary System

The urinary bladder is moderately distended with anechoic urine. The Bladder wall, trigone, ureteral papillae and visible urethra (to a depth of 2cm) appear normal with no evidence of wall thickening, mucosal irregularities, masses or cystic calculi.

The prostate is normal in size (0.71 cm) and shape for this neutered male dog. The parenchyma is homogenous and the external margins are smooth. The prostatic urethra appears normal with no evidence of irregularity, invasion, mass effect or calculi.

INTERPRETED BY

Kathleen Sennello DVM,
MS, Diplomate ACVIM
(Small Animal Internal
Medicine)

The left kidney has a normal shape and size (4.88 cm) with a 0.44 cm cortical cyst. Overall echogenicity is normal with adequate corticomedullary distinction and a typical 1:3 cortex:medulla ratio. There is no evidence of focal perinephric inflammation or effusion. There is no evidence of pyelectasia, nephroliths, infarcts or hydroureter. Renal vasculature is normal.

IMAGING PERFORMED BY

Loetitia Saint-Jacques,
LVT

The right kidney has a normal shape and size (4.59 cm). Overall echogenicity is normal with adequate corticomedullary distinction and a typical 1:3 cortex:medulla ratio. There is no evidence of focal perinephric inflammation or effusion. There is no evidence of pyelectasia, nephroliths, infarcts or hydroureter. Renal vasculature is normal.

HOSPITAL NAME

Advanced PetCare of
Nevada

Adrenal Glands

The left adrenal gland is normal in size measuring 0.41 cm at the caudal pole. It is observed in its normal position cranial to the left renal artery. It is normal in appearance (uniformly hypoechoic) and shape with no evidence of a mass effect.

REFERRING VET

Dr. Alexis Hazelwood

The right adrenal gland is normal in size measuring 0.69 cm at the caudal pole. It is observed in its normal position between the cranial aspect of the right kidney and the caudal vena cava. It is normal in appearance (uniformly hypoechoic) and shape with no evidence of a mass effect.

INVOICE

46587

Spleen

The spleen is subjectively normal in size, echotexture is homogenous, and the splenic capsule is smooth with no irregularities. The blood flow through the hilus and splenic parenchyma appears normal. No focal parenchymal abnormalities are visualized.

DATE

4/11/23


PATIENT *Liver*

Scooter Walter

SPECIES

Canine

BREED

Chihuahua X

SEX

Neutered Male

AGE

11/6/21

WEIGHT

6.3 kg

INTERPRETED BY

 Kathleen Sennello DVM,
 MS, Diplomate ACVIM
 (Small Animal Internal
 Medicine)

IMAGING PERFORMED BY

 Loetitia Saint-Jacques,
 LVT

HOSPITAL NAME

 Advanced PetCare of
 Nevada

REFERRING VET

Dr. Alexis Hazelwood

INVOICE

46587

DATE

4/11/23

The liver is large in size, and normal in echogenicity with smooth peripheral margins. The parenchyma is heterogenous in echotexture with subtle, indistinct focal mottling. The visible portions of the vasculature and biliary tract appear normal. There are too numerous to count, very ill-defined, largely hyperechoic nodules, examples of which measure 1.01 cm in diameter, 0.82 cm in diameter, and 1.8 cm in diameter. There are occasional hypoechoic nodules visualized as well.

The gallbladder lumen is moderately distended. The wall of the gall bladder is not thickened and has a smooth mucosal surface. Luminal contents are mild and primarily anechoic. The cystic and common bile ducts are normal/not visible.

Gastrointestinal

The stomach contains minimal luminal contents. It measures at a normal thickness of <0.7cm with some variability due to the presence of rugal folds. The distinction of the gastric wall layers is adequate and there is no impression of reduced peristaltic activity. No masses or focal lesions were observed.

The visualized areas of duodenum, jejunum and ileum have a uniform diameter with minimal fluid distension. Wall appears subjectively, mildly increased. Bowel loops follow a typical curvilinear path with distinct wall layering. Duodenum wall measures 0.35 cm. Jejunum wall measures 0.38 cm. There is mild mucosal speckling visualized in some areas. Visualized peristalsis appears appropriate. There were no focal lesions consistent with obstruction or a mass effect observed.

The ileocecal junction was visualized and exhibited normal intact wall layering and is subjectively of normal thickness. Sections of colon are visualized with formed fecal material and gas shadowing distally. There is no observed focal or generalized colon wall thickening or loss of layering.

Pancreas

The pancreas is prominent and mottled compared to the surrounding isoechoic mesentery. There is no evidence of nodules or cystic lesions. There is no evidence of regional mesenteric inflammation or fluid.

Free Abdomen

Evaluation of the peritoneal cavity did not reveal any evidence of effusion, or subjective lymphadenomegaly. The Medial iliac nodes appear normal and there was no evidence of a caudal aortic thrombus at the bifurcation. The omentum is of normal uniform echogenicity.

ULTRASONOGRAPHIC FINDINGS

- Prominent, mottled pancreas – The pancreatic changes are most consistent with age-related parenchymal remodeling, potentially secondary to a prior inflammatory episode, early fibrosis or chronic pancreatitis.
- Large, heterogeneous liver with ill-defined hyper- and occasional hypoechoic nodules – The diffuse hepatic changes are non-specific and could be consistent with vacuolar hepatopathy, nodular hyperplasia, inflammatory/immune-mediated disease, fibrosis, extramedullary hematopoiesis, toxic hepatopathy (e.g., copper), infiltrative neoplasia (less likely) or other hepatopathy. The appearance of the nodules is most consistent with a benign process, although an underlying neoplastic process cannot be ruled out.



PATIENT

Scooter Walter

- Subjectively thickened small intestine with mild mucosal speckling – Bright mucosal speckling has been postulated to represent dilated lacteals or focal accumulations of mucus, cellular debris, etc.. in the mucosal crypts.

SPECIES

Canine

INTERPRETATION OF THE FINDINGS & FURTHER RECOMMENDATIONS

Today's scan appears relatively stable from the previous scan on 8/16/22. The changes in the liver are most consistent with a vacuolar hepatopathy based on the primary ALP elevation reported. These are my recommendations for further evaluation of an elevation in ALP.

BREED

Chihuahua X

- Induction phenomena are the most common cause for an elevation in ALP. These are systemic illnesses that 'turn on' the liver enzyme. Causes of this include Cushing's disease, dental disease, arthritis, and numerous others. In many cases the exact cause is unclear but as long as ultrasound and bile acids tests are normal most patients do not have progressive changes in their liver. While liver biopsy is not routinely performed, vacuolar hepatopathy, is noted on most biopsies. This is often non-progressive but in rare cases can be more severe and lead to liver failure.

SEX

Neutered Male

AGE

11/6/21

- If signs of cushings disease are present recommend endocrine function testing to evaluate for cushings disease.

WEIGHT

6.3 kg

- Consider fine needle aspirate to rule out round cell neoplasia -if this is a concern.
- If a cause for the ALP elevation is not identified: I recommend recheck general blood work every 6 months, ultrasound once per year, and bile acids test every 1-2 years based on other results. If the ALP continues to climb a biopsy could be considered.

INTERPRETED BY

Kathleen Sennello DVM,
MS, Diplomate ACVIM
(Small Animal Internal
Medicine)

- Consider long term use of denamarin, and monitoring for the signs of cushings developing.
- A primary vacuolar hepatopathy can be breed related and is seen in Scottish Terriers, Schnauzers, Cocker spaniels etc..

IMAGING PERFORMED BY

Loetitia Saint-Jacques,
LVT

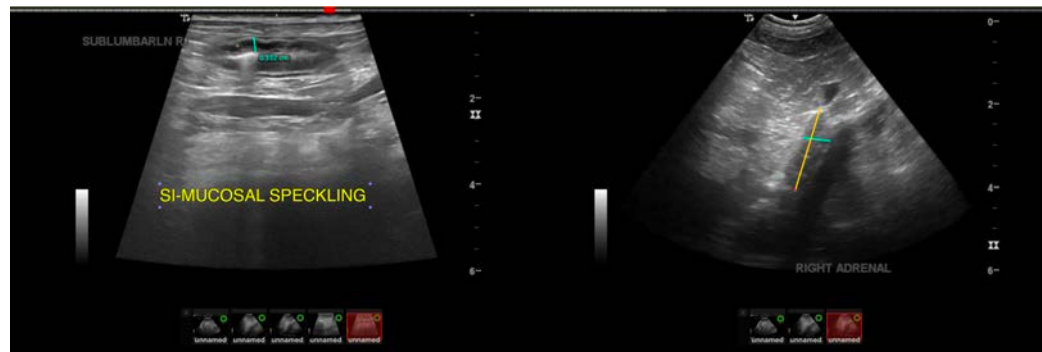The significance of the mucosal speckling is questionable, given the lack of GI signs reported.

HOSPITAL NAME

Advanced PetCare of
Nevada

REFERRING VET

Dr. Alexis Hazelwood



INVOICE

46587

DATE

4/11/23



PATIENT

Scooter Walter

SPECIES

Canine

BREED

Chihuahua X

SEX

Neutered Male

AGE

11/6/21

WEIGHT

6.3 kg

INTERPRETED BY

Kathleen Sennello DVM,
MS, Diplomate ACVIM
(Small Animal Internal
Medicine)

IMAGING PERFORMED BY

Loetitia Saint-Jacques,
LVT

HOSPITAL NAME

Advanced PetCare of
Nevada

REFERRING VET

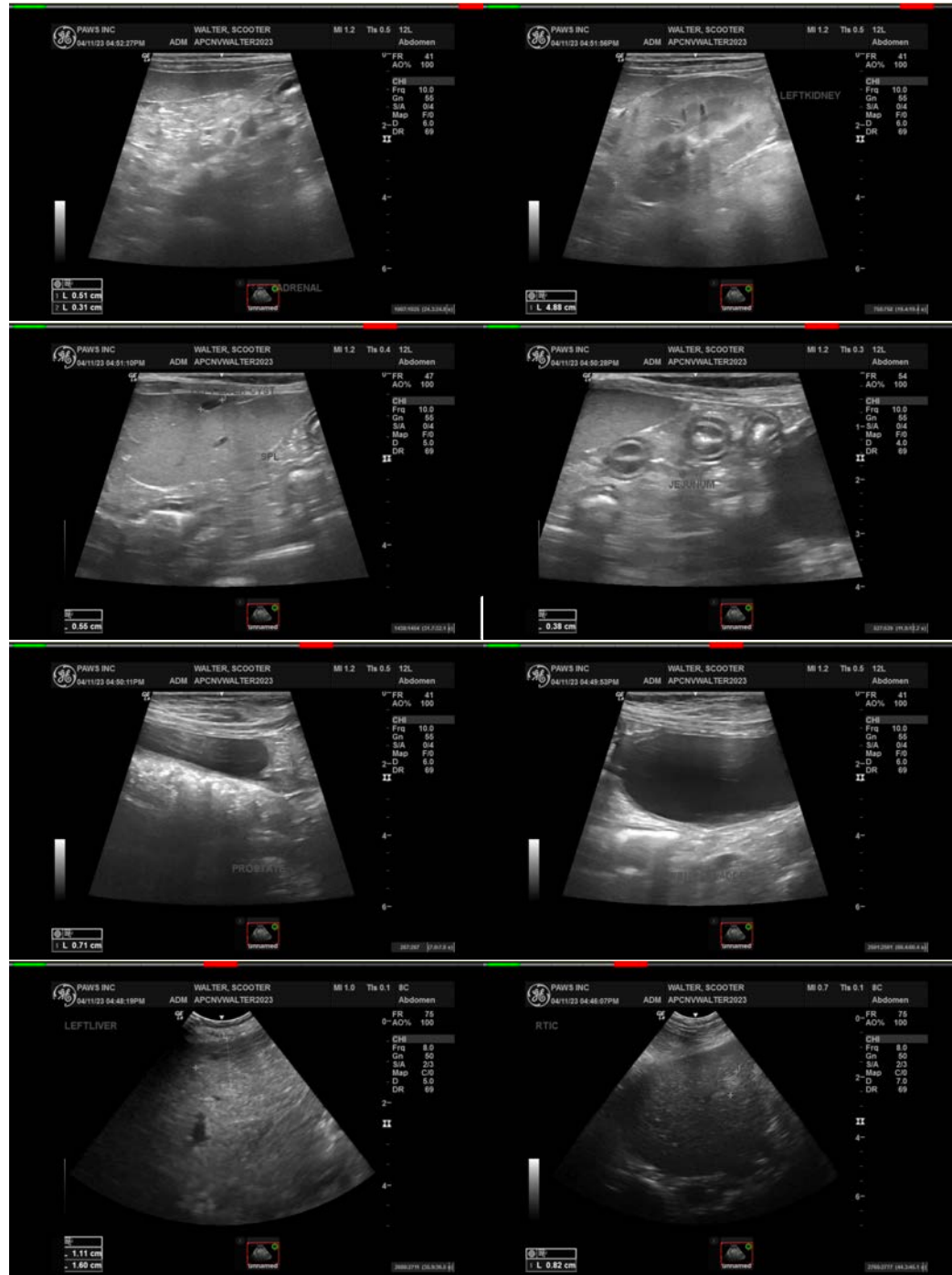
Dr. Alexis Hazelwood

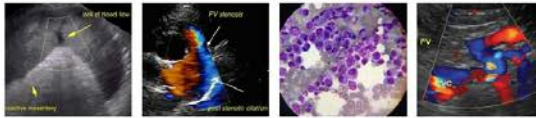
INVOICE

46587

DATE

4/11/23





PATIENT

Scooter Walter

SPECIES

Canine

BREED

Chihuahua X

SEX

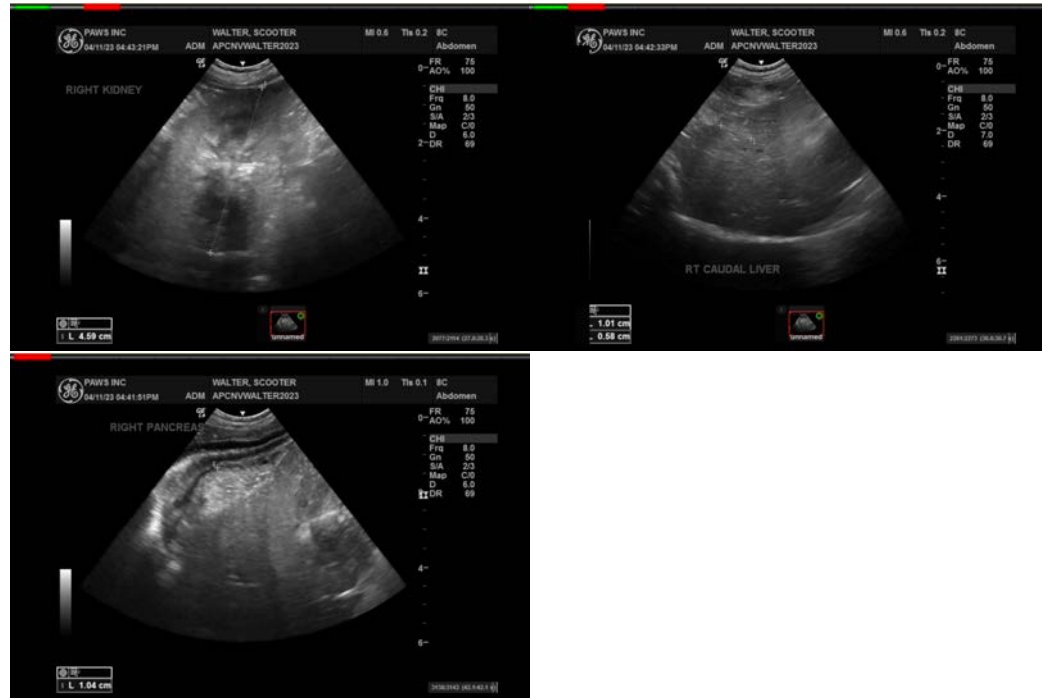
Neutered Male

AGE

11/6/21

WEIGHT

6.3 kg



INTERPRETED BY

Kathleen Sennello DVM,
MS, Diplomate ACVIM
(Small Animal Internal
Medicine)

IMAGING PERFORMED BY

Loetitia Saint-Jacques,
LVT

HOSPITAL NAME

Advanced PetCare of
Nevada

REFERRING VET

Dr. Alexis Hazelwood

INVOICE

46587

DATE

4/11/23

The information and recommendations provided are based on the images presented by the referring veterinarian/sonographer. No evaluation can be communicated regarding pathology that was not visible in the image/video clips provided.

Thank you for this referral. If the clinical or image interpretation does not parallel your findings or if I can be of any further assistance please contact me.

Kathleen Sennello DVM,MS, Diplomate ACVIM (Small animal Internal Medicine)

kathleen.sennello@sonopath.com