

**DATE PRESENTING CLINICAL SIGNS**

4/11/23 Not eating well, losing weight.

PATIENT

Current Medications: Mirataz once daily.
 Lab Results: See attached.
 Oreo Grayson
 Date of Previous IntraPet Ultrasound: No previous.
 Sedation: Telazol/Torbugesic IV
 Stat Report: Not requested.
 Imaging Performed By: Stephanie Warga RDCS, RVT.

SPECIES

Feline

ULTRASONOGRAPHIC EXAMINATION OF THE ABDOMEN**BREED**

DSH

SEX

Neutered Male

AGE

4/4/17

WEIGHT

10.1 Pounds

INTERPRETED BY

Kathleen Sennello DVM,
 MS, Diplomate ACVIM
 (Small Animal Internal
 Medicine)

HOSPITAL NAME

Edgewood VH

REFERRING VET

Dr. Wright

INVOICE

46543

Urinary System

The urinary bladder is moderately distended with mild primarily suspended echogenic debris present. The Bladder wall, trigone, ureteral papillae and visible urethra (to a depth of 2cm) appear normal with no evidence of wall thickening, mucosal irregularities, masses or calculi. Echogenic debris of this type can be associated with small crystals, cellular debris and proteinaceous debris.

The left kidney has a normal shape and size (3.98 cm). Overall echogenicity is normal with adequate corticomedullary distinction and a typical 1:3 cortex:medulla ratio. There is no evidence of focal perinephric inflammation or effusion. There is no evidence of pyelectasia, nephroliths, infarcts or hydroureter. Renal vasculature is normal.

The right kidney has a normal shape and size (3.91 cm). Overall echogenicity is normal with adequate corticomedullary distinction and a typical 1:3 cortex:medulla ratio. There is no evidence of focal perinephric inflammation or effusion. There is no evidence of pyelectasia, nephroliths, infarcts or hydroureter. Renal vasculature is normal.

Adrenal Glands

The left adrenal gland is normal in size measuring 0.31 cm at the caudal pole. It is observed in its normal position cranial to the left renal artery. It is normal in appearance (uniformly hypoechoic) and shape with no evidence of a mass effect.

The right adrenal gland is normal in size measuring 0.27 cm at the caudal pole. It is observed in its normal position between the cranial aspect of the right kidney and the caudal vena cava. It is normal in appearance (uniformly hypoechoic) and shape with no evidence of a mass effect.

Spleen

The spleen is subjectively normal in size (0.78 cm), echotexture is homogenous, and the splenic capsule is smooth with no irregularities. The blood flow through the hilus and splenic parenchyma appears normal. No focal parenchymal abnormalities are visualized.

Liver

The liver is subjectively normal in size with smooth peripheral margins. The parenchyma is mildly hyperechoic and homogenous in echotexture. The visible portions of the vasculature and biliary tract appear normal. No focal nodules or cystic lesions are observed.

The gallbladder lumen is moderately distended. The wall of the gall bladder is not thickened and has a smooth mucosal surface. Luminal contents are mild and primarily anechoic. The cystic and common bile ducts are normal/not visible.

Gastrointestinal

The stomach contains minimal luminal contents. It measures at a normal thickness of <0.36cm with some variability due to the presence of rugal folds. The distinction of the gastric wall layers is adequate and there is no impression of reduced peristaltic activity. No masses or focal lesions were observed.

The visualized areas of duodenum, jejunum and ileum have a uniform diameter with minimal fluid distension. Wall thickness is normal to slightly increased. Bowel loops follow a typical curvilinear path with distinct wall layering, but some areas display a prominent muscularis layer which does not display the typical 1:3 muscularis:mucosa layer ratio. Duodenum wall measures 0.30 cm. Jejunum wall measures 0.24 cm. Visualized peristalsis appears appropriate. There were no focal lesions consistent with obstruction or a mass effect observed.

The ileocecal junction was visualized and exhibited normal intact wall layering and is subjectively of normal thickness. Sections of colon are visualized with formed fecal material and gas shadowing distally. There is no observed focal or generalized colon wall thickening or loss of layering.

Pancreas

The pancreas is prominent and mottled compared to the surrounding isoechoic mesentery. There is no evidence of nodules or cystic lesions. There is no evidence of regional mesenteric inflammation or fluid.

Free Abdomen

Evaluation of the peritoneal cavity did not reveal any evidence of effusion, or subjective lymphadenomegaly. The Medial iliac nodes appear normal and there was no evidence of a caudal aortic thrombus at the bifurcation. The omentum is of normal uniform echogenicity.

ULTRASONOGRAPHIC FINDINGS

- Echogenic debris in the urinary bladder – The echogenic debris in the bladder lumen could be consistent with cells, crystals, and/or mucus.
- Prominent, mottled pancreas – The pancreatic changes are most consistent with age-related parenchymal remodeling, potentially secondary to a prior inflammatory episode, early fibrosis or chronic pancreatitis.
- Mildly hyperechoic liver – Hepatic changes are non-specific and could be consistent with hepatic lipidosis, inflammatory/infectious disease, infiltrative neoplasia, or other hepatopathy.
- Prominent muscularis layer to the small intestine – The small intestinal wall changes could be consistent with an underlying inflammatory process. These types of changes can sometimes be seen in normal older cats. Correlate with clinical signs.

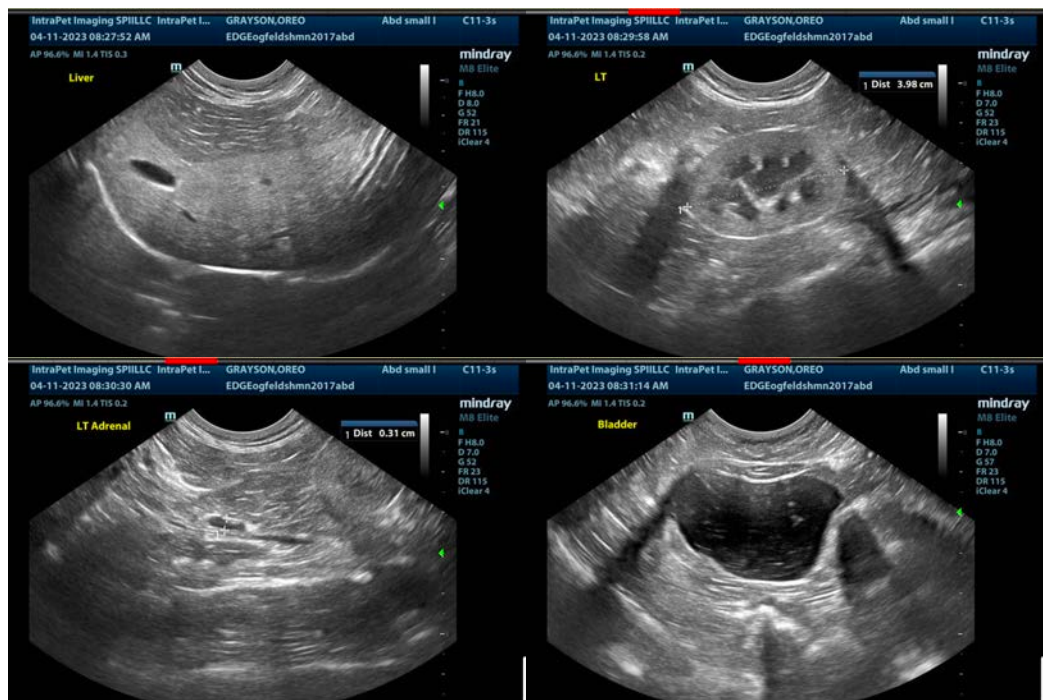
INTERPRETATION OF THE FINDINGS & FURTHER RECOMMENDATIONS

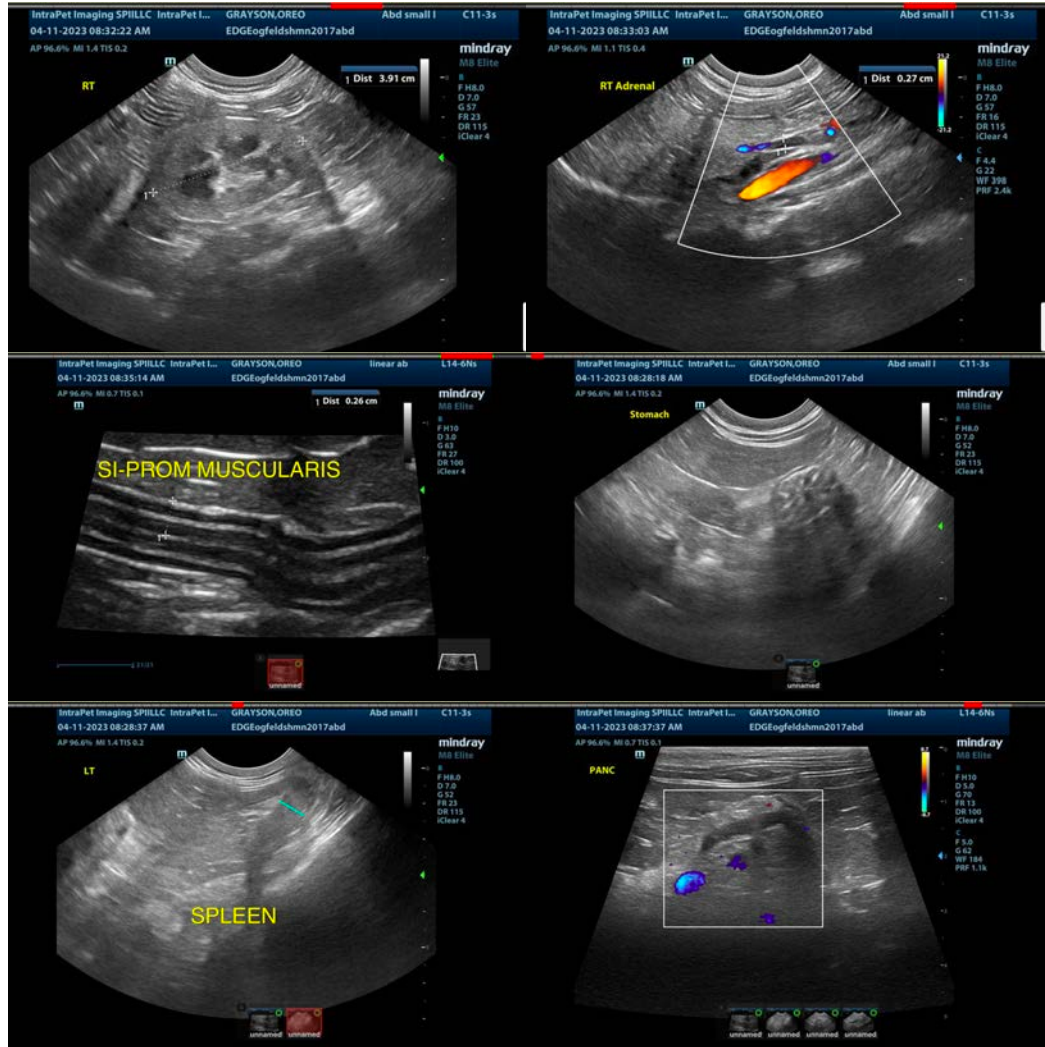
The lesions observed on today's scan are relatively mild. No focal lesions visualized associated with the gastrointestinal tract to explain the anorexia and weight loss reported.

The pancreas is slightly prominent and mottled. Correlate these findings with a quantitative fPLI level. There is no significant inflammation surrounding the pancreas, so I suspect these changes are consistent with previous episodes of pancreatic inflammation, but mild current inflammation cannot be ruled out. The significance of a slightly hyperechoic liver is uncertain. This could be secondary to fat deposition in an overweight cat or could be secondary to early lipidotic or inflammatory type changes. Recommend continued monitoring of liver values.

Unfortunately, you can still have significant gastrointestinal disease despite a relatively normal ultrasound. The muscularis layer appears somewhat prominent on today's scan, which could be an indicator of underlying inflammation. If primary gastrointestinal disease is thought likely, then consider the following:

- Consider a novel protein/hydrolyzed protein diet (exclusively at least 4-6 weeks)
- Consider a GI panel to Texas A&M for evaluation of B12 levels, folate, PLI/TLI etc.. to further evaluate for pancreatic/small intestinal disease.
- Recommend chronic probiotic therapy.
- Consider empirical treatment for pancreatitis.
- Recommend 3-view thoracic radiographs.
- If symptoms persist and primary gastrointestinal disease is thought likely, then consider obtaining GI biopsies.
- If liver enzymes continue to rise, then consider a liver function test and a fine needle aspirate of the liver (provided coagulation parameters are normal).





The information and recommendations provided are based on the images presented by the referring veterinarian/sonographer. No evaluation can be communicated regarding pathology that was not visible in the image/video clips provided.

Thank you for this referral. If the clinical or image interpretation does not parallel your findings or if I can be of any further assistance please contact me.

Kathleen Sennello DVM,MS, Diplomate ACVIM (Small animal Internal Medicine)
 kathleen.sennello@sonopath.com