

**DATE PRESENTING CLINICAL SIGNS**

4/11/23 Persistently elevated liver values on recent bloodwork.

PATIENT Current Medications: Denamarin advanced- 1 SID for the last month.
Lab Results: ALT 226, ALKP 628.

Hope Daniel Date of Previous IntraPet Ultrasound: No previous.
Sedation: Not required to complete full diagnostic ultrasound.

SPECIES Stat Report: Not requested.
Imaging Performed By: Andi Parkinson, BS, RDMS.

Canine

ULTRASONOGRAPHIC EXAMINATION OF THE ABDOMEN**BREED****Urinary System**

Mixed

The urinary bladder is moderately distended with anechoic urine. The Bladder wall, trigone, ureteral papillae and visible urethra (to a depth of 2cm) appear normal with no evidence of wall thickening, mucosal irregularities, masses or cystic calculi.

SEX

Spayed Female

The left kidney has a normal shape and size (6.8 cm). Overall echogenicity is slightly hyperechoic with poor corticomedullary distinction and a typical 1:3 cortex:medulla ratio. There is no evidence of focal perinephric inflammation or effusion. There is no evidence of pyelectasia, nephroliths, infarcts or hydroureter. Renal vasculature is normal.

AGE

8/26/11

The right kidney has a normal shape and size (6.3 cm). Overall echogenicity is slightly hyperechoic with poor corticomedullary distinction and a typical 1:3 cortex:medulla ratio. There is no evidence of focal perinephric inflammation or effusion. There is no evidence of pyelectasia, nephroliths, infarcts or hydroureter. Renal vasculature is normal.

WEIGHT

67 Pounds

INTERPRETED BY

Kathleen Sennello DVM,
MS, Diplomate ACVIM
(Small Animal Internal
Medicine)

Adrenal Glands

The left adrenal gland is slightly large in size measuring 0.48 cm at the cranial pole, 0.94 cm at the caudal pole, and 3.0 cm in length. It is observed in its normal position cranial to the left renal artery. It is slightly abnormal in appearance in that the caudal pole is prominent and somewhat rounded, but isoechoic to the remainder of the adrenal. No evidence of vascular invasion is visualized.

HOSPITAL NAME

Banfield Timonium

The right adrenal gland is normal in size measuring 0.64 cm at the caudal pole. It is observed in its normal position between the cranial aspect of the right kidney and the caudal vena cava. It is normal in appearance (uniformly hypoechoic) and shape with no evidence of a mass effect.

REFERRING VET

Dr. Crakes

Spleen

The spleen is subjectively normal in size, echotexture is homogenous, and the splenic capsule is smooth with no irregularities. The blood flow through the hilus and splenic parenchyma appears normal. No focal parenchymal abnormalities are visualized.

INVOICE

46553

Liver

The liver is large in size and irregular in shape. The parenchyma is mildly heterogenous in echotexture with subtle, indistinct focal mottling. The visible portions of the vasculature and biliary tract appear normal. There is a mixed echogenic, slightly cystic mass effect visualized in what appears to be the right medial aspect of the liver measuring approximately 6.94 cm x 4.41 cm. Additionally, there is a subtle isoechoic mass effect in the right caudoventral aspect of the liver measuring 2.76 cm x 2.33 cm.

The gallbladder lumen is moderately distended. The wall of the gall bladder is not thickened and has a smooth mucosal surface. Luminal contents are mild and primarily anechoic. The cystic and common bile ducts are normal/not visible.

Gastrointestinal

The stomach contains minimal luminal contents. It measures at a normal thickness of <0.7cm with some variability due to the presence of rugal folds. The distinction of the gastric wall layers is adequate and there is no impression of reduced peristaltic activity. No masses or focal lesions were observed.

The visualized areas of duodenum, jejunum and ileum have a relatively uniform diameter with minimal fluid distension. Wall thickness is normal. Bowel loops follow a curvilinear path with distinct wall layering maintaining the typical 1:3 muscularis:mucosa layer ratio. Jejunum wall measures 0.37 cm. Visualized peristalsis appears appropriate. There were no focal lesions consistent with obstruction or a mass effect observed.

The ileocecal junction was visualized and exhibited normal intact wall layering and is subjectively of normal thickness. Sections of colon are visualized with formed fecal material and gas shadowing distally. There is no observed focal or generalized colon wall thickening or loss of layering.

Pancreas

The pancreas is normal and isoechoic to surrounding mesentery. There is no evidence of nodules or cystic lesions. There is no evidence of regional mesenteric inflammation or fluid.

Free Abdomen

Evaluation of the peritoneal cavity did not reveal any evidence of effusion, or subjective lymphadenomegaly. The Medial iliac nodes appear normal and there was no evidence of a caudal aortic thrombus at the bifurcation. The omentum is of normal uniform echogenicity.

ULTRASONOGRAPHIC FINDINGS

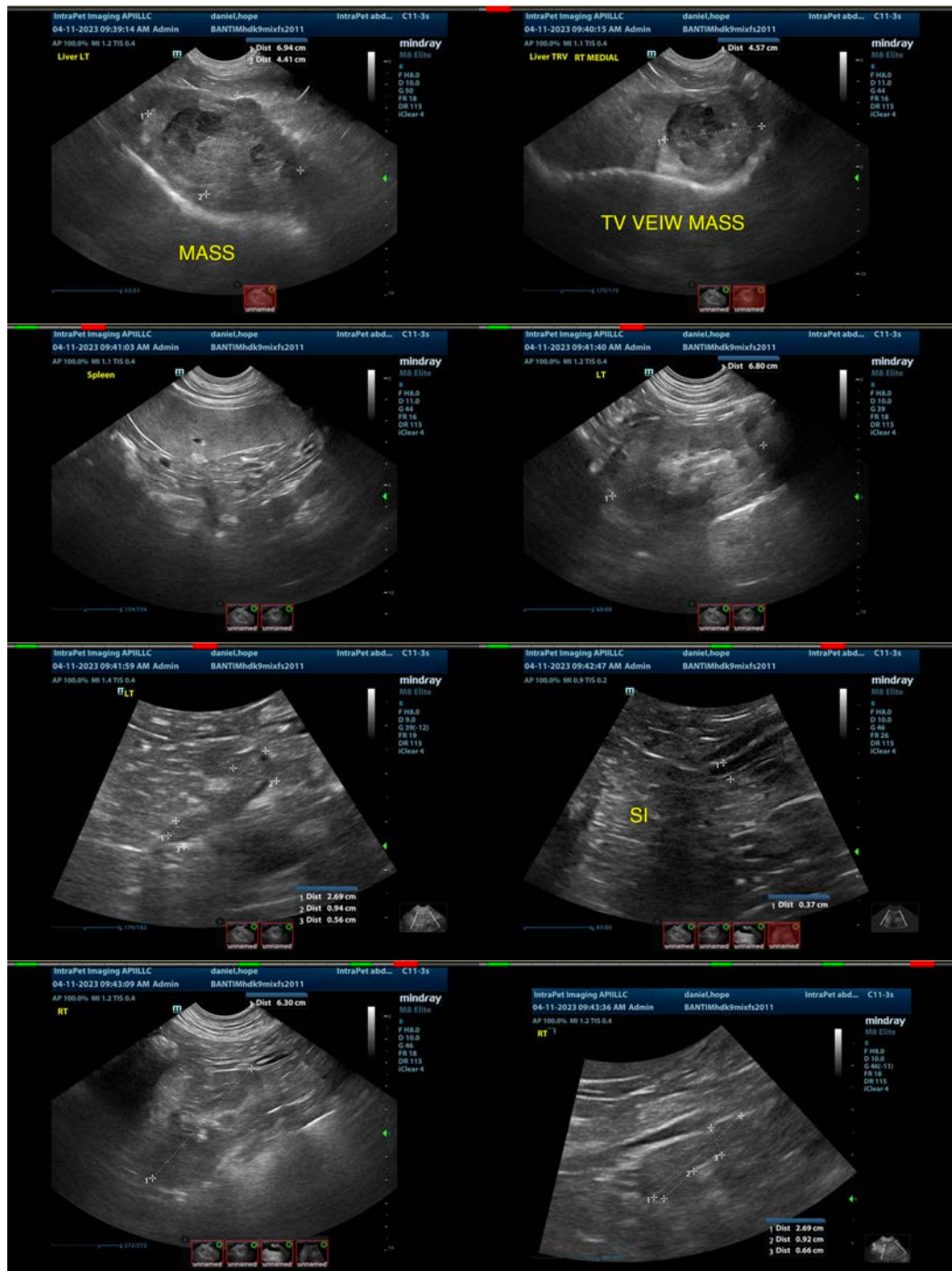
- Prominent caudal pole of the left adrenal – This is not an overt mass effect at this time, but continued monitoring and a blood pressure evaluation is warranted.
- Mildly heterogeneous liver with a mixed echogenic/cavitated mass effect and a subtle isoechoic mass effect – The diffuse hepatic changes are non-specific and could be consistent with vacuolar hepatopathy, nodular hyperplasia, inflammatory/immune-mediated disease, fibrosis, extramedullary hematopoiesis, toxic hepatopathy (e.g., copper), infiltrative neoplasia (less likely) or other hepatopathy. There is a large, irregular, mixed echogenic mass effect that is concerning for a possible neoplastic lesion, although a benign lesion is also possible (carcinoma, adenoma, other). The isoechoic mass lesion is less concerning and more consistent with a possible benign mass lesion, but sampling would be necessary to confirm.
- Decreased corticomedullary distinction in both kidneys – The bilateral renal findings are consistent with age-related change.

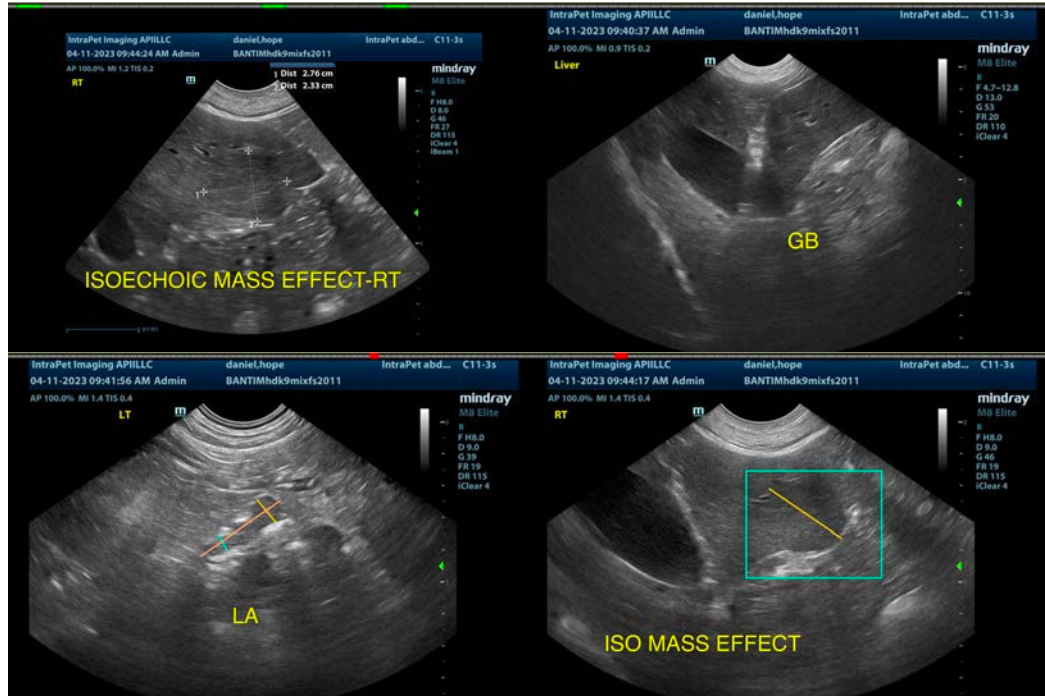
INTERPRETATION OF THE FINDINGS & FURTHER RECOMMENDATIONS

There are two lesions associated with the liver. The mixed echogenic large, irregular, cavitated lesion is more concerning and appears to be in the region of the right medial lobe. Additionally, there is an isoechoic mass effect in the right caudal liver, which is somewhat less concerning in appearance. If possible, consider a fine needle aspirate of the mixed echogenic lesion (or both). Additionally, consider a contrast CT scan to further evaluate these lesions for possible surgical removal.

Recommend three view thoracic radiographs to evaluate for possible concurrent thoracic disease/involvement.

The caudal pole of the left adrenal gland is subtly rounded and enlarged. This is isoechoic, and no discrete mass effect is visualized. This could represent normal anatomic variation, hyperplasia, or an early mass lesion. Recommend a blood pressure evaluation and reevaluation of the left adrenal gland in 8-12 weeks, looking for any evidence of progression.





The information and recommendations provided are based on the images presented by the referring veterinarian/sonographer. No evaluation can be communicated regarding pathology that was not visible in the image/video clips provided.

Thank you for this referral. If the clinical or image interpretation does not parallel your findings or if I can be of any further assistance please contact me.

Kathleen Sennello DVM,MS, Diplomate ACVIM (Small animal Internal Medicine)
kathleen.sennello@sonopath.com