



PATIENT

Emmie Brecheen

SPECIES

Canine

BREED

Mixed

SEX

Spayed Female

AGE

15 Years

WEIGHT

21 Pounds

INTERPRETED BY

Kathleen Sennello DVM,
MS, Diplomate ACVIM
(Small Animal Internal
Medicine)

IMAGING PERFORMED BY

Dr. Ferrer

HOSPITAL NAME

Pasos Vet Center

REFERRING VET

Dr. Perez

INVOICE

46545

DATE

4/11/23

PRESENTING CLINICAL SIGNS

The patient presented as a referral for an abdominal ultrasound with a history of pancreatitis and renal failure.

Abnormal PE/Chem/CBC/UA Results: U/A: Done today and showed rods and cocci Urine culture pending CHEM: CREA: 1.7 BUN: 40 SDMA: 17 AMYL: 3,000 CA: 11.4

ULTRASONOGRAPHIC EXAMINATION OF THE ABDOMEN

Urinary System

The urinary bladder is moderately distended with mildly echogenic urine. The Bladder wall largely appears within normal limits, but is slightly irregular and thickened in the dependent region. Additionally, there is some pinpoint hyperechoic foci most consistent with small mineralized debris. The area of the trigone, ureteral papillae and proximal urethra appear normal with no evidence of any mass lesions or calculi.

The left kidney has a normal shape and size (5.11cm) with numerous cortical cysts and pyelectasia at 0.56 cm. Overall echogenicity is slightly hyperechoic with poor corticomedullary distinction and a typical 1:3 cortex:medulla ratio. There is no evidence of focal perinephric inflammation or effusion. There is no evidence of nephroliths, infarcts or hydroureter. Renal vasculature is normal.

The right kidney has a normal shape and size (4.83 cm) with numerous cortical cysts and pyelectasia at 0.52 cm. Overall echogenicity is slightly hyperechoic with poor corticomedullary distinction and a typical 1:3 cortex:medulla ratio. There is no evidence of focal perinephric inflammation or effusion. There is no evidence of nephroliths, infarcts or hydroureter. Renal vasculature is normal.

Adrenal Glands

The left adrenal gland is normal in size measuring 0.78 cm at the caudal pole. It is observed in its normal position cranial to the left renal artery. It is normal in appearance (uniformly hypoechoic) and shape with no evidence of a mass effect.

The right adrenal gland is normal in size measuring 0.65 cm at the caudal pole. It is observed in its normal position between the cranial aspect of the right kidney and the caudal vena cava. It is normal in appearance (uniformly hypoechoic) and shape with no evidence of a mass effect.

Spleen

The spleen is subjectively normal in size and the echotexture is homogenous. The splenic capsule is smooth with no visible irregularities. Rare discrete focal hyperechoic, perivascular parenchymal abnormalities are present. The appearance of these lesions is most consistent with benign splenic myelolipomas. The blood flow through the hilus and splenic parenchyma appears normal.

Liver

The liver is large in size and irregular. The parenchyma is heterogenous in echotexture with subtle, indistinct focal mottling. The visible portions of the vasculature and biliary tract appear normal. There are numerous ill-defined coalescing hyperechoic nodules visualized within the parenchyma. Examples measure 1.52, 1.22, and 1.41 cm in diameter.

The gall bladder lumen is moderately distended. The wall of the gall bladder is not thickened and has a smooth mucosal surface. There is a moderate amount of non-organized echogenic debris. The cystic and common bile ducts are normal/not visible.



PATIENT

Emmie Brecheen

SPECIES

Canine

BREED

Mixed

SEX

Spayed Female

AGE

15 Years

WEIGHT

21 Pounds

INTERPRETED BY

Kathleen Sennello DVM,
MS, Diplomate ACVIM
(Small Animal Internal
Medicine)

**IMAGING
PERFORMED BY**

Dr. Ferrer

HOSPITAL NAME

Pasos Vet Center

REFERRING VET

Dr. Perez

INVOICE

46545

DATE

4/11/23

Gastrointestinal

The stomach contains moderate ingesta. It measures at a normal thickness of <0.7cm with some variability due to the presence of rugal folds. The distinction of the gastric wall layers is adequate and there is no impression of reduced peristaltic activity. No masses or focal lesions were observed.

The visualized areas of duodenum, jejunum and ileum have a uniform diameter with minimal fluid distension. Wall appears subjectively, mildly increased. Bowel loops follow a typical curvilinear path with distinct wall layering. Duodenum wall measures 0.65 cm. Jejunum wall measures 0.45 cm. Visualized peristalsis appears appropriate. There were no focal lesions consistent with obstruction or a mass effect observed.

The ileocecal junction was visualized and exhibited normal intact wall layering and is subjectively of normal thickness. Sections of colon are visualized with formed fecal material and gas shadowing distally. There is no observed focal or generalized colon wall thickening or loss of layering.

Pancreas

The pancreas is large and hypoechoic to surrounding mesentery. There is no evidence of nodules or cystic lesions. There is evidence of regional mesenteric inflammation. Consistent with mild pancreatitis.

Free Abdomen

Evaluation of the peritoneal cavity did not reveal any evidence of effusion. There is an occasional visible mesenteric lymph node. One such lymph node is measured at 0.47 cm. The omentum is slightly hyperechoic in the region around the pancreas.

ULTRASONOGRAPHIC FINDINGS

- Mildly thickened urinary bladder wall with echogenic debris – The echogenic debris in the bladder lumen could be consistent with cells, crystals, and/or mucus.
- Decreased corticomedullary distinction in both kidneys with cortical cysts and bilateral pyelectasia – Mild loss of corticomedullary distinction in both kidneys could be consistent with chronic degenerative disease or interstitial nephrosis. Pyelectasia of the kidney(s) could be consistent with pyelonephritis, chronic renal disease, secondary to PU/PD or fluid therapy (if applicable), other.
- Hyperechoic nodules visualized within the spleen – Findings are most consistent with benign myelolipomas. Recommend continued monitoring.
- Hypoechoic, irregular, mottled pancreas with surrounding hyperechoic mesentery – The pancreatic changes are most consistent with moderate pancreatitis/pancreatic inflammation. Recommend fPLI testing and continued monitoring for improvement or possible development of a pancreatic abscess. Consider fine needle aspirate if not improving.
- Large, heterogeneous liver with irregular coalescing hyperechoic nodules – The diffuse hepatic changes are non-specific and could be consistent with vacuolar hepatopathy, nodular hyperplasia, inflammatory/immune-mediated disease, fibrosis, extramedullary hematopoiesis, toxic hepatopathy (e.g., copper), infiltrative neoplasia (less likely) or other hepatopathy. The significance of the hyperechoic nodules is uncertain. The appearance of these lesions trends towards a more benign etiology, but an underlying neoplastic process cannot be ruled out. Recommend continued monitoring.



PATIENT

Emmie Brecheen

- Moderate gallbladder debris – The significance of the aggregated gallbladder debris is unclear. This could represent an early mucocele, cholestasis, or may be secondary to fasting but seems unlikely to be causing a current issue. Recommend continued monitoring.

SPECIES

Canine

- Mildly thickened small intestine – The mild small intestinal wall changes may be a normal variant in this patient or could be consistent with an inflammatory process (e.g., inflammatory bowel disease).

BREED

Mixed

INTERPRETATION OF THE FINDINGS & FURTHER RECOMMENDATIONS

SEX

Spayed Female

The changes observed in both kidneys are consistent with chronic progressive renal disease. The pyelectasia in combination with the active urine sediment is concerning for concurrent pyelonephritis. Recommend urinalysis and culture (I think this is currently pending) in addition to a blood pressure. The changes observed in the urinary bladder could be secondary to cystitis.

AGE

15 Years

The pancreas appears hypoechoic and irregular with some surrounding mildly hyperechoic mesentery. These changes could be consistent with mild pancreatitis or even a previous episode of pancreatic inflammation. Recommend concurrent treatment for pancreatitis.

WEIGHT

21 Pounds

The liver is heterogeneous with ill-defined coalescing hyperechoic nodules. The appearance of these nodules trends towards a more benign etiology. If possible, fine needle aspirate could be considered. Otherwise, continued monitoring is warranted. If significant liver enzyme elevations are present, consider a liver function test. At this time, the debris in the gallbladder is moderate with no significant gallbladder wall thickening. Recommend continued monitoring.

INTERPRETED BY

Kathleen Sennello DVM,
MS, Diplomate ACVIM
(Small Animal Internal
Medicine)

The small intestine subjectively appears somewhat thickened, but there is normal intact wall layering. The significance of this is unclear, but there could be underlying intestinal inflammation. At this time, I would recommend focusing on treatment of the possible urinary tract infection, the renal failure, and the suspected concurrent pancreatitis.

IMAGING PERFORMED BY

Dr. Ferrer

Recommend three view thoracic radiographs to evaluate for possible concurrent thoracic disease/involvement.

HOSPITAL NAME

Pasos Vet Center

REFERRING VET

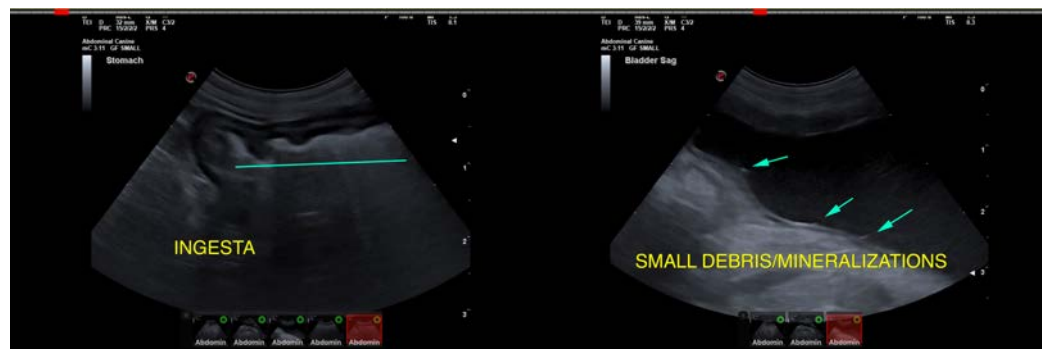Dr. Perez

INVOICE

46545

DATE

4/11/23





PATIENT

Emmie Brecheen

SPECIES

Canine

BREED

Mixed

SEX

Spayed Female

AGE

15 Years

WEIGHT

21 Pounds

INTERPRETED BY

Kathleen Sennello DVM,
MS, Diplomate ACVIM
(Small Animal Internal
Medicine)

**IMAGING
PERFORMED BY**

Dr. Ferrer

HOSPITAL NAME

Pasos Vet Center

REFERRING VET

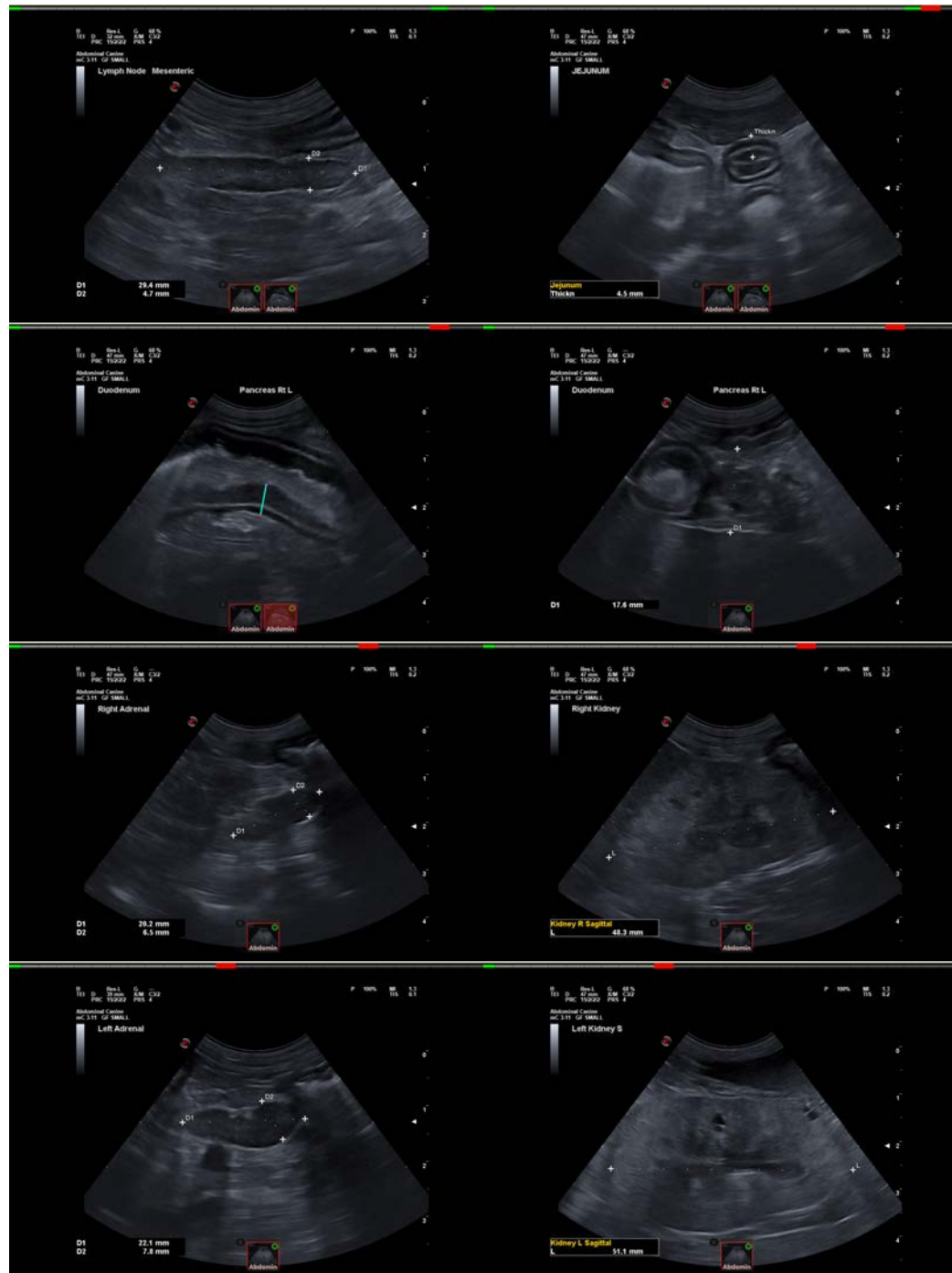
Dr. Perez

INVOICE

46545

DATE

4/11/23





PATIENT

Emmie Brecheen

SPECIES

Canine

BREED

Mixed

SEX

Spayed Female

AGE

15 Years

WEIGHT

21 Pounds

INTERPRETED BY

Kathleen Sennello DVM,
MS, Diplomate ACVIM
(Small Animal Internal
Medicine)

**IMAGING
PERFORMED BY**

Dr. Ferrer

HOSPITAL NAME

Pasos Vet Center

REFERRING VET

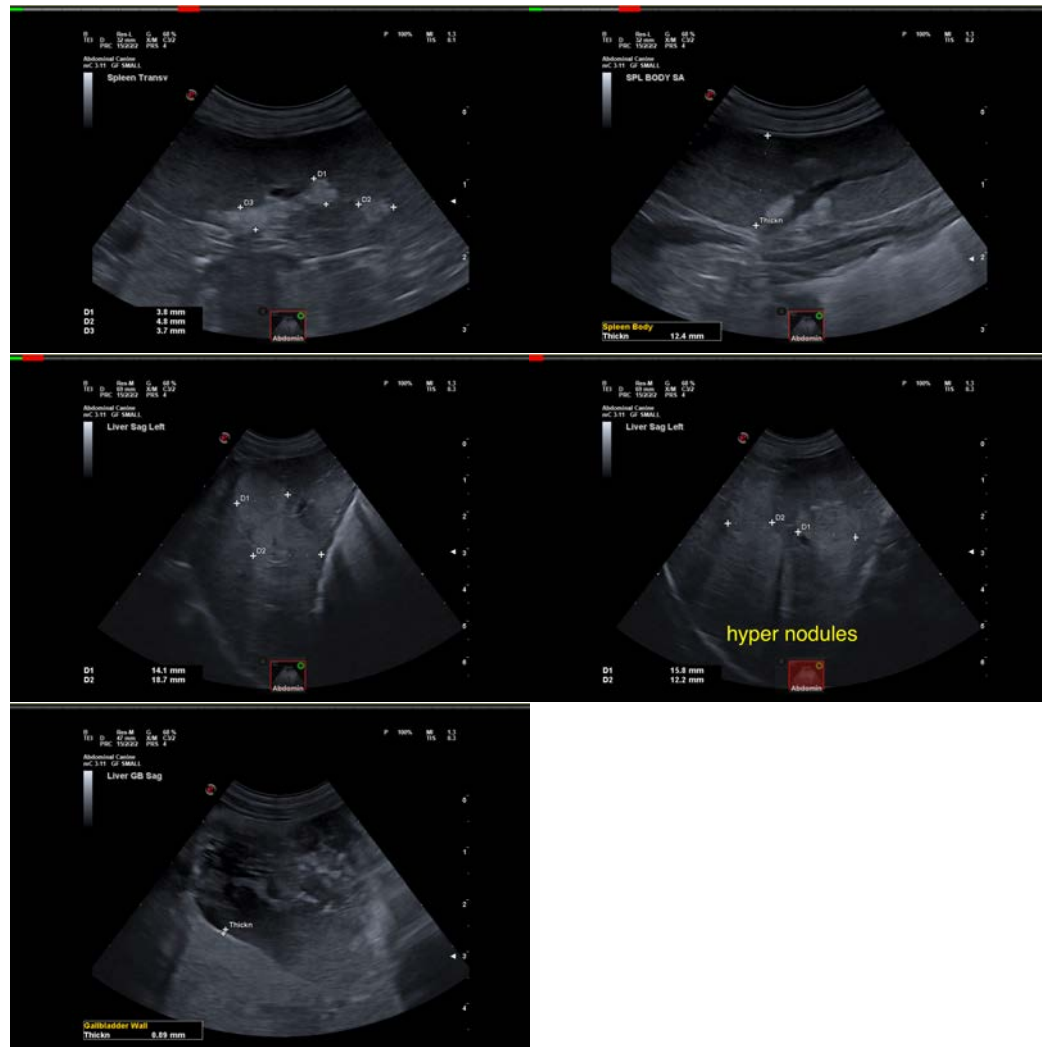
Dr. Perez

INVOICE

46545

DATE

4/11/23



The information and recommendations provided are based on the images presented by the referring veterinarian/sonographer. No evaluation can be communicated regarding pathology that was not visible in the image/video clips provided.

Thank you for this referral. If the clinical or image interpretation does not parallel your findings or if I can be of any further assistance please contact me.

Kathleen Sennello DVM,MS, Diplomate ACVIM (Small animal Internal Medicine)

kathleen.sennello@sonopath.com