**DATE PRESENTING CLINICAL SIGNS**

4/11/23 Weight loss, anorexia.

PATIENT Current Medications: IV fluids 2x main, Enrofloxacin 5mg/kg IV SID, Entyce 3mg/kg PO SID.

Cami Carlin Lab Results: BUN >130, SDMA 24. UA- USG 1.020, 3+ protein.

Date of Previous IntraPet Ultrasound: No previous.

Sedation: Not required to complete full diagnostic ultrasound.

Stat Report: Not requested.

SPECIES Imaging Performed By: Andi Parkinson, BS, RDMS.

Canine

ULTRASONOGRAPHIC EXAMINATION OF THE ABDOMEN**BREED** *Urinary System*

Yorkie The urinary bladder is moderately distended with anechoic urine. The majority of the bladder wall appears relatively normal with smooth mucosal surface and normal wall thickness. The exception to this is a small area involving the ventral aspect of the cystourethral junction where there is focal thickening measuring approximately 0.52 cm in thickness. This thickening extends for at least 0.99 cm and cannot be clearly followed into the urethra. The remainder of the bladder evaluation is normal with no evidence of calculi.

SEX

Spayed Female

AGE

4/10/10

The left kidney has a normal shape and size (3.81 cm) with pinpoint non-obstructive mineralizations. Overall echogenicity is slightly hyperechoic with poor corticomedullary distinction and a typical 1:3 cortex:medulla ratio. There is no evidence of focal perinephric inflammation or effusion. There is no evidence of pyelectasia, nephroliths, infarcts or hydroureter. Renal vasculature is normal.

WEIGHT

8.24 Pounds

The right kidney has a normal shape and size (3.75 cm) with pinpoint non-obstructive mineralizations. Overall echogenicity is slightly hyperechoic with poor corticomedullary distinction and a typical 1:3 cortex:medulla ratio. There is no evidence of focal perinephric inflammation or effusion. There is no evidence of pyelectasia, nephroliths, infarcts or hydroureter. Renal vasculature is normal.

INTERPRETED BYKathleen Sennello DVM,
MS, Diplomate ACVIM
(Small Animal Internal
Medicine)**Adrenal Glands**

The left adrenal gland is normal in size measuring 0.61 cm at the caudal pole. It is observed in its normal position cranial to the left renal artery. It is normal in appearance (uniformly hypoechoic) and shape with no evidence of a mass effect.

HOSPITAL NAME

Eastern AH

The right adrenal gland is normal in size measuring 0.56 cm at the caudal pole. It is observed in its normal position between the cranial aspect of the right kidney and the caudal vena cava. It is normal in appearance (uniformly hypoechoic) and shape with no evidence of a mass effect.

REFERRING VET

Dr. Kaufman

Spleen

The spleen is subjectively normal in size, echotexture is homogenous, and the splenic capsule is smooth with no irregularities. The blood flow through the hilus and splenic parenchyma appears normal. No focal parenchymal abnormalities are visualized.

INVOICE

46547

Liver

The liver is subjectively normal in size, and echogenicity with smooth peripheral margins. The parenchyma is homogenous echotexture. The visible portions of the vasculature and biliary tract appear normal. No focal nodules or cystic lesions are observed.

The gall bladder lumen is moderately distended. The wall of the gall bladder is not thickened and has a smooth mucosal surface. There is a moderate amount of non-organized echogenic debris. The cystic and common bile ducts are normal/not visible.

Gastrointestinal

The stomach contains minimal luminal contents. It measures at a normal thickness of <0.7cm with some variability due to the presence of rugal folds. The distinction of the gastric wall layers is adequate and there is no impression of reduced peristaltic activity. No masses or focal lesions were observed.

The visualized areas of duodenum, jejunum and ileum have a relatively uniform diameter with minimal fluid distension. Wall thickness is normal. Bowel loops follow a curvilinear path with distinct wall layering maintaining the typical 1:3 muscularis:mucosa layer ratio. Duodenum wall measures 0.43 cm. Jejunum wall measures 0.30 cm. Visualized peristalsis appears appropriate. There were no focal lesions consistent with obstruction or a mass effect observed.

The ileocecal junction was visualized and exhibited normal intact wall layering and is subjectively of normal thickness. Sections of colon are visualized with formed fecal material and gas shadowing distally. There is no observed focal or generalized colon wall thickening or loss of layering.

Pancreas

The pancreas is prominent and mottled compared to the surrounding isoechoic mesentery. There is no evidence of nodules or cystic lesions. There is no evidence of regional mesenteric inflammation or fluid.

Free Abdomen

Evaluation of the peritoneal cavity did not reveal any evidence of effusion, or subjective lymphadenomegaly. The Medial iliac nodes appear normal and there was no evidence of a caudal aortic thrombus at the bifurcation. The omentum is of normal uniform echogenicity.

Other

The right auricle and pericardium were visualized and were unremarkable. No obvious pathology is visualized. If cardiac function evaluation is desired a full echocardiogram is warranted.

Ringdown artifact is visualized at the level of the diaphragm. This can be an indicator of pulmonary parenchymal disease. No focal pulmonary lesions were visualized. Recommend 3-view thoracic radiographs.

ULTRASONOGRAPHIC FINDINGS

- Irregular tissue at the ventral portion of the cystourethral junction – This could be benign (hyperplasia, a polyp, etc.), or could represent an early neoplastic lesion.
- Decreased corticomedullary distinction in both kidneys with small non-obstructive mineralizations – Mild loss of corticomedullary distinction in both kidneys could be consistent with chronic degenerative disease or interstitial nephrosis.
- Prominent, mottled pancreas – The pancreatic changes are most consistent with age-related parenchymal remodeling, potentially secondary to a prior inflammatory episode, early fibrosis or chronic pancreatitis.
- Moderate gallbladder debris – The significance of the aggregated gallbladder debris is unclear. This could represent an early mucocele, cholestasis, or may be secondary to fasting but seems unlikely to be causing a current issue. Recommend continued monitoring.
- Ringdown artifact visualized at the level of the diaphragm – This can be seen with pulmonary parenchymal disease. Recommend 3-view thoracic radiographs.

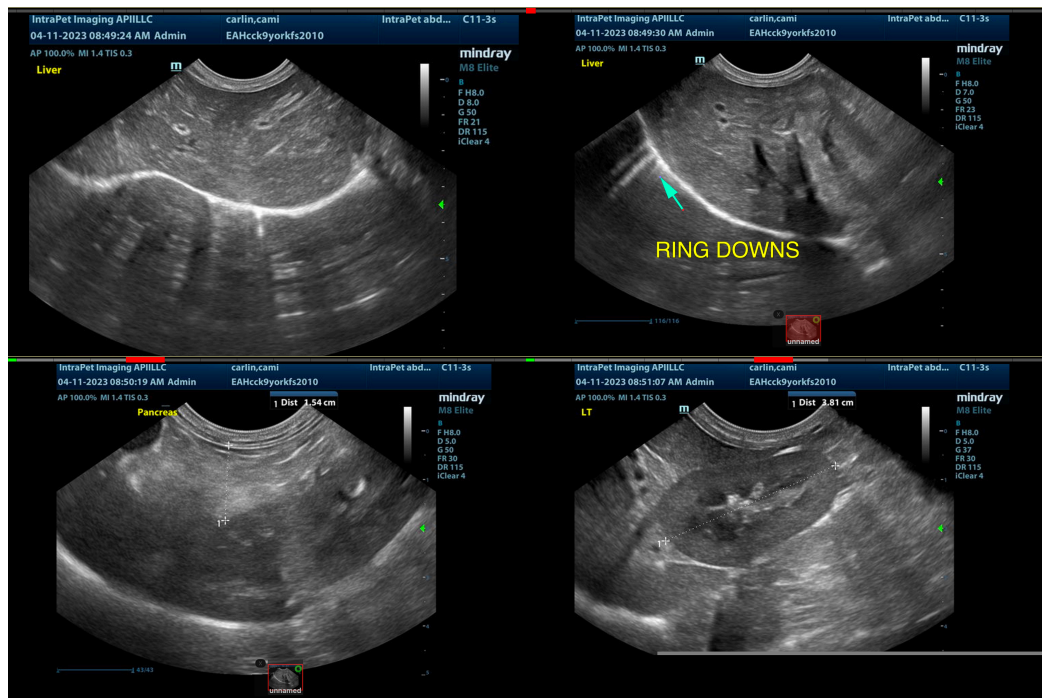
INTERPRETATION OF THE FINDINGS & FURTHER RECOMMENDATIONS

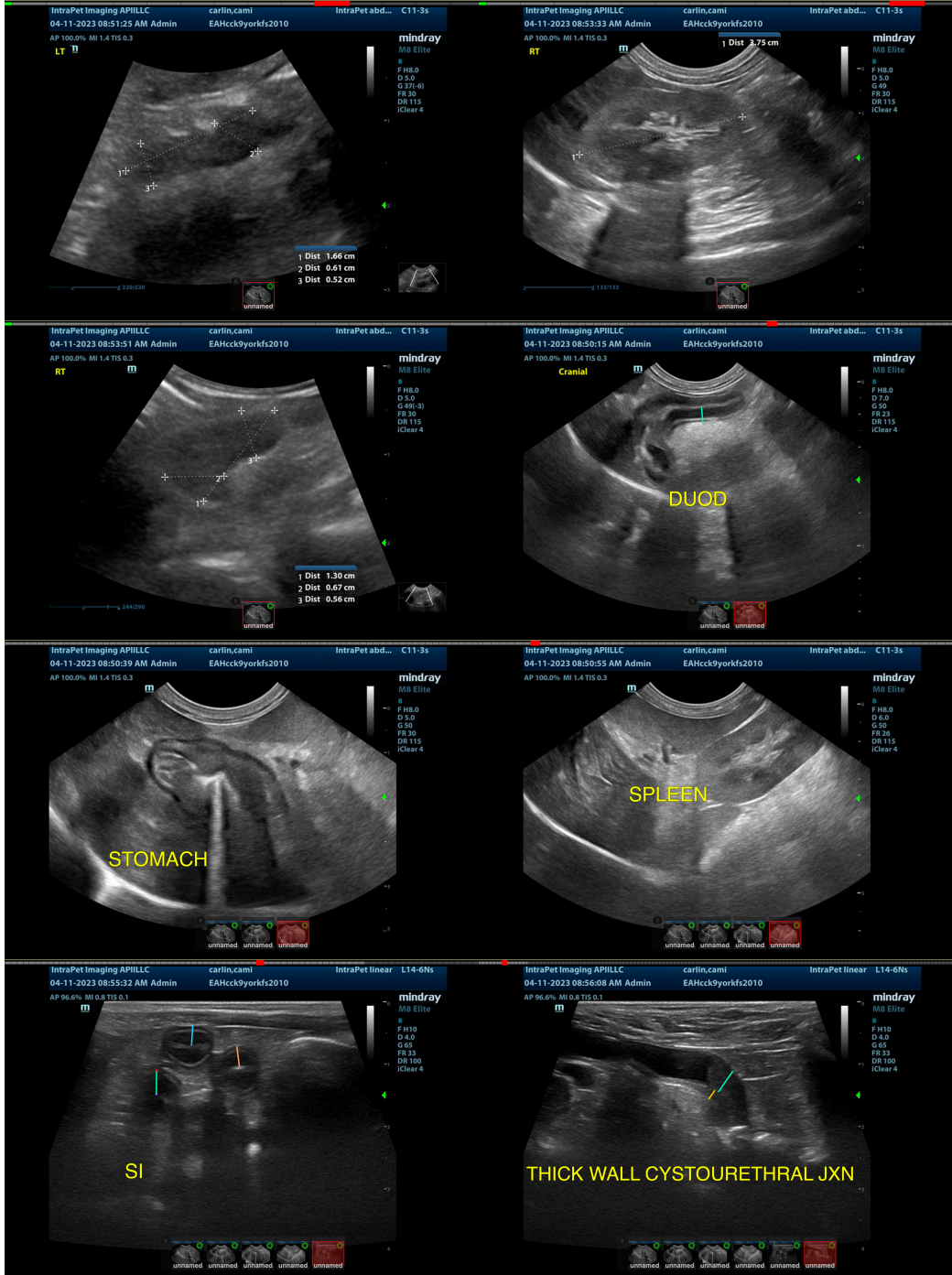
There is some thickened irregular tissue visualized at the ventral aspect of the cystourethral junction. The significance of this is unclear. This could represent normal anatomic variation, a benign polyp, or an early neoplastic lesion. Consider reevaluation of the urinary bladder when it is more distended. Additionally, recommend a urinalysis and culture as well as a urine protein to creatinine ratio if there is an inactive sediment. Options moving forward would include a urine BRAF test. If the test is positive, I would recommend a traumatic catheterization at the level of the cystourethral junction, or cystoscopy. If the test is negative, it is inconclusive, and close continued monitoring is warranted. Recommend recheck evaluation in approximately 6 weeks with a more distended urinary bladder.

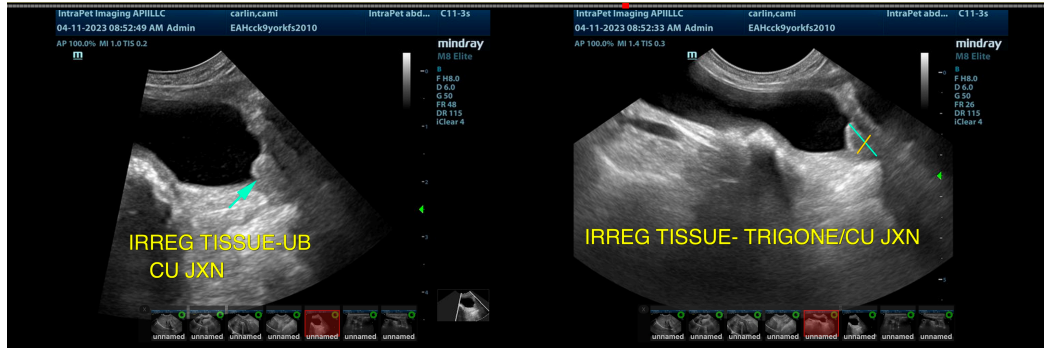
Both kidneys have changes consistent with age related renal disease. Recommend a blood pressure, urinalysis and culture (as previously recommended), looking for evidence of glomerular disease or any contributing factors to contribute to renal disease.

The changes in the gallbladder and pancreas are mild at this time. I suspect they are incidental, but continued monitoring for gastrointestinal signs unrelated to the renal disease is warranted.

Ringdown artifact is seen at the level of the diaphragm. This can be seen with pulmonary parenchymal disease. 3-view thoracic radiographs are recommended.







The information and recommendations provided are based on the images presented by the referring veterinarian/sonographer. No evaluation can be communicated regarding pathology that was not visible in the image/video clips provided.

Thank you for this referral. If the clinical or image interpretation does not parallel your findings or if I can be of any further assistance please contact me.

Kathleen Sennello DVM,MS, Diplomate ACVIM (Small animal Internal Medicine)
kathleen.sennello@sonopath.com