



PATIENT

Ben Fiala

SPECIES

Feline

BREED

DMH

SEX

Neutered Male

AGE

11 Years

WEIGHT

16

INTERPRETED BY

Beth Johnson, DVM
DACVIM

IMAGING PERFORMED BY

Dr. Reyes

HOSPITAL NAME

Mobile Vet Ultrasound

REFERRING VET

Dr. Santiago

INVOICE

46558

DATE

4/11/23

PRESENTING CLINICAL SIGNS

Pet presented yesterday for lack of appetite, lethargy and hiding for the last 10 days. Bloodwork showed non regenerative anemia and decreased WBC and platelet count

Abnormal PE/Chem/CBC/UA Results: RBC: 4.87 HCT: 26.4 HGB: 8.5 WBC: 4.18 Neut: 2.52 (low end of normal) Plt: 145

ULTRASONOGRAPHIC EXAMINATION OF THE ABDOMEN

Urinary System

The urinary bladder is moderately distended with anechoic urine. The Bladder wall, trigone, ureteral papillae and visible urethra (to a depth of 2cm) appear normal with no evidence of wall thickening, mucosal irregularities, masses or cystic calculi.

The left kidney has a normal shape and size (3.64 cm) with questionable pyelectasia at 0.43 cm. Overall echogenicity is normal with adequate corticomedullary distinction and a typical 1:3 cortex:medulla ratio. There is no evidence of focal perinephric inflammation or effusion. There is no evidence of pyelectasia, nephroliths, infarcts or hydroureter. Renal vasculature is normal.

The right kidney has a normal shape and size (3.64 cm). Overall echogenicity is normal with adequate corticomedullary distinction and a typical 1:3 cortex:medulla ratio. There is no evidence of focal perinephric inflammation or effusion. There is no evidence of pyelectasia, nephroliths, infarcts or hydroureter. Renal vasculature is normal.

Adrenal Glands

The region of left adrenal (Cranial to left renal artery) is unremarkable but the adrenal is not distinctly visualized. No evidence of a mass effect is visualized.

The region of the right adrenal (between right cranial kidney and vena cava) is unremarkable, but the adrenal is not distinctly visualized. No evidence of a mass effect is visualized.

Spleen

The spleen is large in size (1.59 cm) The spleen echotexture is heterogenous and mottled, the splenic capsule is smooth with no irregularities. The blood flow through the hilus and splenic parenchyma appears normal. No focal parenchymal abnormalities are visualized.

Liver

The liver is subjectively normal in size, and echogenicity with smooth peripheral margins. The parenchyma is homogenous echotexture. The visible portions of the vasculature and biliary tract appear normal. No focal nodules or cystic lesions are observed.

The gallbladder lumen is moderately distended. The wall of the gall bladder is not thickened and has a smooth mucosal surface. Luminal contents are mild and primarily anechoic. The cystic and common bile ducts are normal/not visible.

Gastrointestinal

The stomach contains minimal luminal contents. It measures at a normal thickness of <0.36cm with some variability due to the presence of rugal folds. The distinction of the gastric wall layers is adequate and there is no impression of reduced peristaltic activity. No masses or focal lesions were observed.



PATIENT

Ben Fiala

SPECIES

Feline

BREED

DMH

SEX

Neutered Male

AGE

11 Years

WEIGHT

16

INTERPRETED BY

Beth Johnson, DVM
DACVIM

IMAGING PERFORMED BY

Dr. Reyes

HOSPITAL NAME

Mobile Vet Ultrasound

REFERRING VET

Dr. Santiago

INVOICE

46558

DATE

4/11/23

The visualized areas of duodenum, jejunum and ileum have a relatively uniform diameter with minimal fluid distension. Wall thickness is normal. Bowel loops follow a curvilinear path with distinct wall layering maintaining the typical 1:3 muscularis:mucosa layer ratio. The duodenum measured as normal (between 0.13-0.38cm in wall thickness) and the jejunum measured as normal (between 0.15-0.36cm.) Visualized peristalsis appears appropriate. There were no focal lesions consistent with obstruction or a mass effect observed.

The ileocecal junction was visualized and exhibited normal intact wall layering and is subjectively of normal thickness. Sections of colon are visualized with formed fecal material and gas shadowing distally. There is no observed focal or generalized colon wall thickening or loss of layering.

Pancreas

The pancreas is normal and isoechoic to surrounding mesentery. There is no evidence of nodules or cystic lesions. There is no evidence of regional mesenteric inflammation or fluid.

Free Abdomen

Evaluation of the peritoneal cavity did not reveal any evidence of effusion, or subjective lymphadenomegaly. The Medial iliac nodes appear normal and there was no evidence of a caudal aortic thrombus at the bifurcation. The omentum is of normal uniform echogenicity.

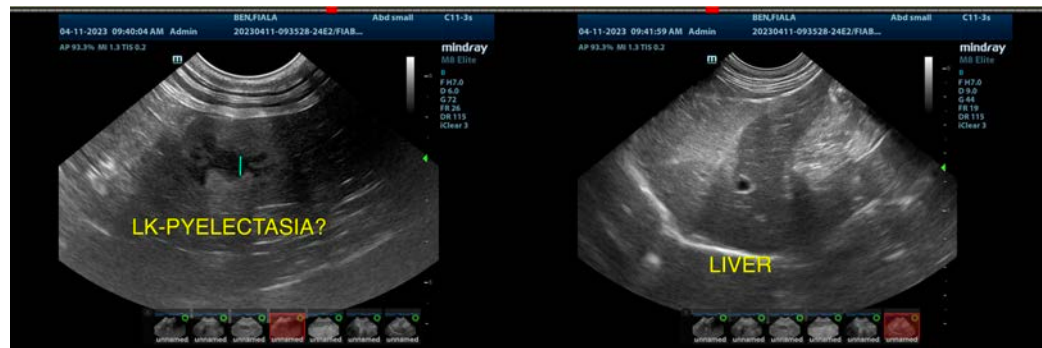
ULTRASONOGRAPHIC FINDINGS

- Large, mottled spleen – The diffuse splenic changes are non-specific and could be consistent with lymphoid hyperplasia, extramedullary hematopoiesis, infiltrative neoplasia, inflammation, other. Cytology or histopathology would be necessary to get a definitive diagnosis.
- Questionable left-sided pyelectasia – This is not 100% clear. Consider color flow in this kidney and evaluation with the high frequency probe. Consider a urinalysis and culture.

INTERPRETATION OF THE FINDINGS & FURTHER RECOMMENDATIONS

The spleen appears large and mottled with scalloped edges. Recommend a fine needle aspirate of the spleen, looking for evidence of round cell neoplasia, evidence of red blood cell regeneration, etc. If cytology is unhelpful, then the anemia is likely associated with an anemia of chronic disease, but consider pathologist review of a blood smear, looking for any evidence of other findings. Additionally, you could consider screening for mycoplasma and 3-view thoracic radiographs.

There is questionable pyelectasia of the left kidney. This could just be a hypoechoic medulla. If possible, consider color flow on this kidney and evaluation with a high frequency probe. Otherwise, consider a urinalysis and culture and continued monitoring.





PATIENT

Ben Fiala

SPECIES

Feline

BREED

DMH

SEX

Neutered Male

AGE

11 Years

WEIGHT

16

INTERPRETED BY

Beth Johnson, DVM
DACVIM

IMAGING PERFORMED BY

Dr. Reyes

HOSPITAL NAME

Mobile Vet Ultrasound

REFERRING VET

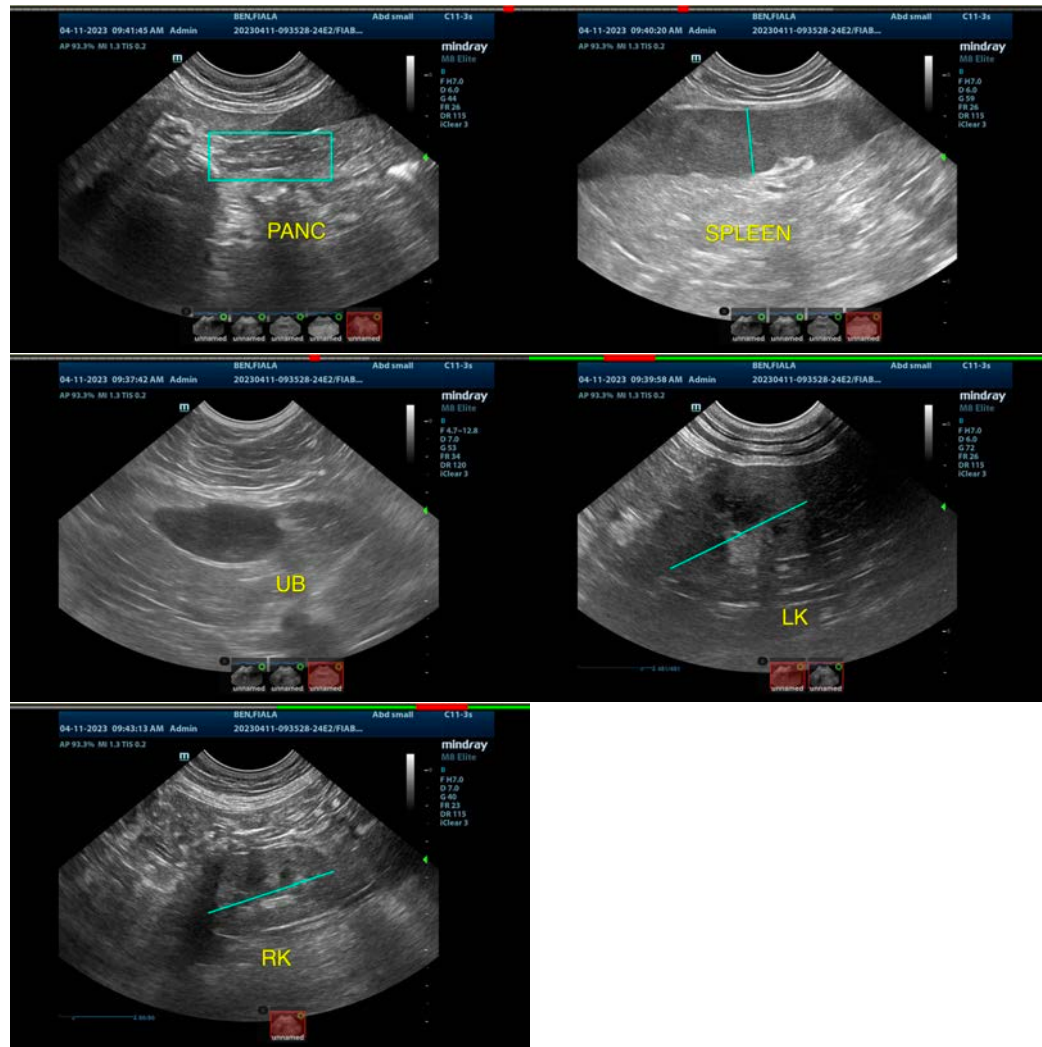
Dr. Santiago

INVOICE

46558

DATE

4/11/23



The information and recommendations provided are based on the images presented by the referring veterinarian/sonographer. No evaluation can be communicated regarding pathology that was not visible in the image/video clips provided.

Thank you for this referral. If the clinical or image interpretation does not parallel your findings or if I can be of any further assistance please contact me.

Kathleen Sennello DVM,MS, Diplomate ACVIM (Small animal Internal Medicine)

kathleen.sennello@sonopath.com