



**DATE PRESENTING CLINICAL SIGNS**

04/10/26

Patient History: End of January: Onset of inappetence and decreased activity - Initially treated at Banfield with prednisone and joint medication with temporary improvement - Symptoms recurred multiple times despite repeated courses of prednisone - Seen at Pet ER: anemia identified, fever noted, ultrasound recommended but not performed - Seen at another clinic (everhart) last week for second opinion:

**PATIENT**

Prince Hollimon

ultrasound recommended: no additional diagnostics performed - Currently on prednisone 20mg PO q24h (started in morning at 8am), has been on steroids intermittently for approximately 2 months - Eating and drinking normally when on prednisone; inappetent when off medication - No coughing, sneezing, vomiting, or diarrhea - Persistent anemia since January; historically "a little on the anemic side his whole life" - White blood cell count: low end of normal in January, below normal in March, normalized one week later - Platelet counts have fluctuated - Radiographs at Banfield: concern for pulmonary bulla, abdomen appeared normal - Pet ER CBC (April 2): showed persistent anemia (specific results pending) - Non-regenerative anemia based on previous CBCs: per owner- the anemia has been chronic- do not have bloodwork results prior to 1/14/26

**SPECIES**

Canine

**BREED**

English Cocker Spaniel

**SEX**

Neutered Male

Current Medications: Gabapentin, Trazodone.  
Labwork Results: Labwork not attached, reported as: PCV 22/8.0.  
Date of Previous IntraPet Ultrasound: No previous.  
Sedation: IV Torb required to complete full diagnostic ultrasound.  
Stat Report: STAT requested.

**AGE**

10/14/16

Imaging Performed by: Rachel Brillhart, RDMS.

**ULTRASONOGRAPHIC EXAMINATION OF THE ABDOMEN**

**WEIGHT**

32.6 pounds

**Urinary System**

The urinary bladder is moderately distended with anechoic urine. The bladder wall appears mildly thickened measuring at 0.45 cm in the apical region with a smooth mucosal surface. The region of the trigone, ureteral papilla and proximal urethra appear within normal limits with no evidence of any mass lesions or calculi.

**INTERPRETED BY**

Kathleen Sennello  
DVM, MS, Diplomate  
ACVIM (Small animal  
Internal Medicine)

The prostate is normal in size (1.04 cm) and shape for this neutered male dog. The parenchyma is homogenous, and the external margins are smooth. The prostatic urethra appears normal with no evidence of irregularity, invasion, mass effect or calculi.

**HOSPITAL NAME**

Animal Emergency  
Hospital

The left kidney has a normal shape and size (6.09 cm). Overall echogenicity is slightly hyperechoic with mildly reduced corticomedullary distinction and a typical 1:3 cortex:medulla ratio. There is no evidence of focal perinephric inflammation or effusion. There is no evidence of pyelectasia, nephroliths, infarcts or hydroureter. Renal vasculature is normal. Occasional pinpoint mineralizations were present.

**REFERRING VET**

Dr. Willer

The right kidney has a normal shape and size (6.12 cm). Overall echogenicity is slightly hyperechoic with mildly reduced corticomedullary distinction and a typical 1:3 cortex:medulla ratio. There is no evidence of focal perinephric inflammation or effusion. There is no evidence of pyelectasia, nephroliths, infarcts or hydroureter. Renal vasculature is normal. Rare pinpoint mineralizations were present.

**INVOICE**

15001

**Adrenal Glands**

The left adrenal gland is normal in size measuring 0.52 cm at the cranial pole and 0.53 cm at the caudal pole. It is observed in its normal position cranial to the left renal artery. It is normal in appearance (uniformly hypoechoic) and shape with no evidence of a mass effect.

The right adrenal gland is normal in size measuring 0.83 cm at the cranial pole and 0.70 cm at the caudal pole. It is observed in its normal position between the cranial aspect of the right kidney and the caudal vena cava. It is normal in appearance (uniformly hypoechoic) and shape with no evidence of a mass effect.

### ***Spleen***

The spleen is subjectively normal in size (1.78 cm in width at the level of the hilus). The spleen echotexture is heterogenous and mottled, the splenic capsule is smooth with no irregularities. The blood flow through the hilus and splenic parenchyma appears normal. No focal parenchymal abnormalities are visualized.

### ***Liver***

The liver is subjectively large in size, and echogenicity with rounded margins. The parenchyma is heterogenous in echotexture with subtle, indistinct focal mottling. The visible portions of the vasculature and biliary tract appear normal. No focal nodules or cystic lesions are observed.

The gall bladder lumen is moderately distended. The wall of the gall bladder is not thickened and has a smooth mucosal surface. There is a mildly amount of non-organized echogenic debris. The cystic and common bile ducts are normal/not visible. There is some hyperechoic dependent debris most consistent with sandy mineralizations such as small stones.

### ***Gastrointestinal***

The stomach contains minimal luminal contents. It measures at a normal thickness of <0.7 cm with some variability due to the presence of rugal folds. The distinction of the gastric wall layers is adequate and there is no impression of reduced peristaltic activity. No masses or focal lesions were observed.

The visualized areas of duodenum, jejunum and ileum have a relatively uniform diameter with minimal fluid distension. Wall thickness is normal. Bowel loops follow a curvilinear path with distinct wall layering maintaining the typical 1:3 muscularis: mucosa layer ratio. The duodenum measured as normal (between 0.3 - 0.5 cm in wall thickness) and the jejunum measured as normal (between 0.2 - 0.47 cm) Visualized peristalsis appears appropriate. There were no focal lesions consistent with obstruction or a mass effect observed.

Sections of colon are visualized with formed fecal material and gas shadowing distally. There is no observed focal or generalized colon wall thickening or loss of layering.

### ***Pancreas***

The pancreas is normal and isoechoic to surrounding mesentery. There is no evidence of nodules or cystic lesions. There is no evidence of regional mesenteric inflammation or fluid.

### ***Free Abdomen***

Evaluation of the peritoneal cavity did not reveal any evidence of effusion, or subjective lymphadenomegaly. The medial iliac nodes appear normal and there was no evidence of a caudal aortic thrombus at the bifurcation. The omentum is of normal uniform echogenicity.

The right auricle and pericardium were visualized and were unremarkable. No obvious pathology is visualized. If cardiac function evaluation is desired a full echocardiogram is warranted.

## **ULTRASONOGRAPHIC FINDINGS**

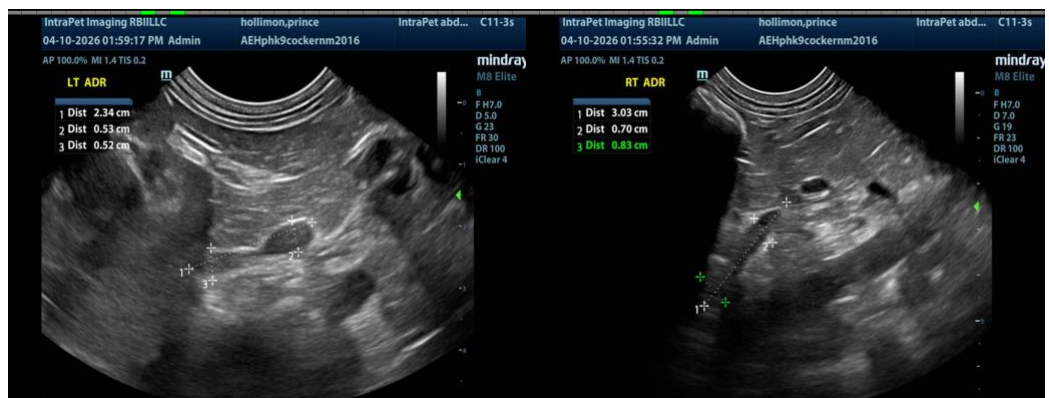- Mildly thickened urinary bladder wall- The bladder mucosal changes could be consistent with cystitis or artifactual due to lack of adequate luminal distension. Bladder neoplasia cannot be ruled out but is considered unlikely in this patient.
- Age-related changes visualized associated with the kidneys.
- Mildly mottled spleen- The diffuse splenic changes are non-specific and could be consistent with lymphoid hyperplasia, extramedullary hematopoiesis, infiltrative neoplasia, inflammation, other. Cytology or histopathology would be necessary to get a definitive diagnosis.
- Large heterogenous rounded liver- findings are most consistent with a vacuolar hepatopathy/steroid hepatopathy. Other hepatopathies are possible.
- Small amount of sandy mineralized debris visualized in the gallbladder.

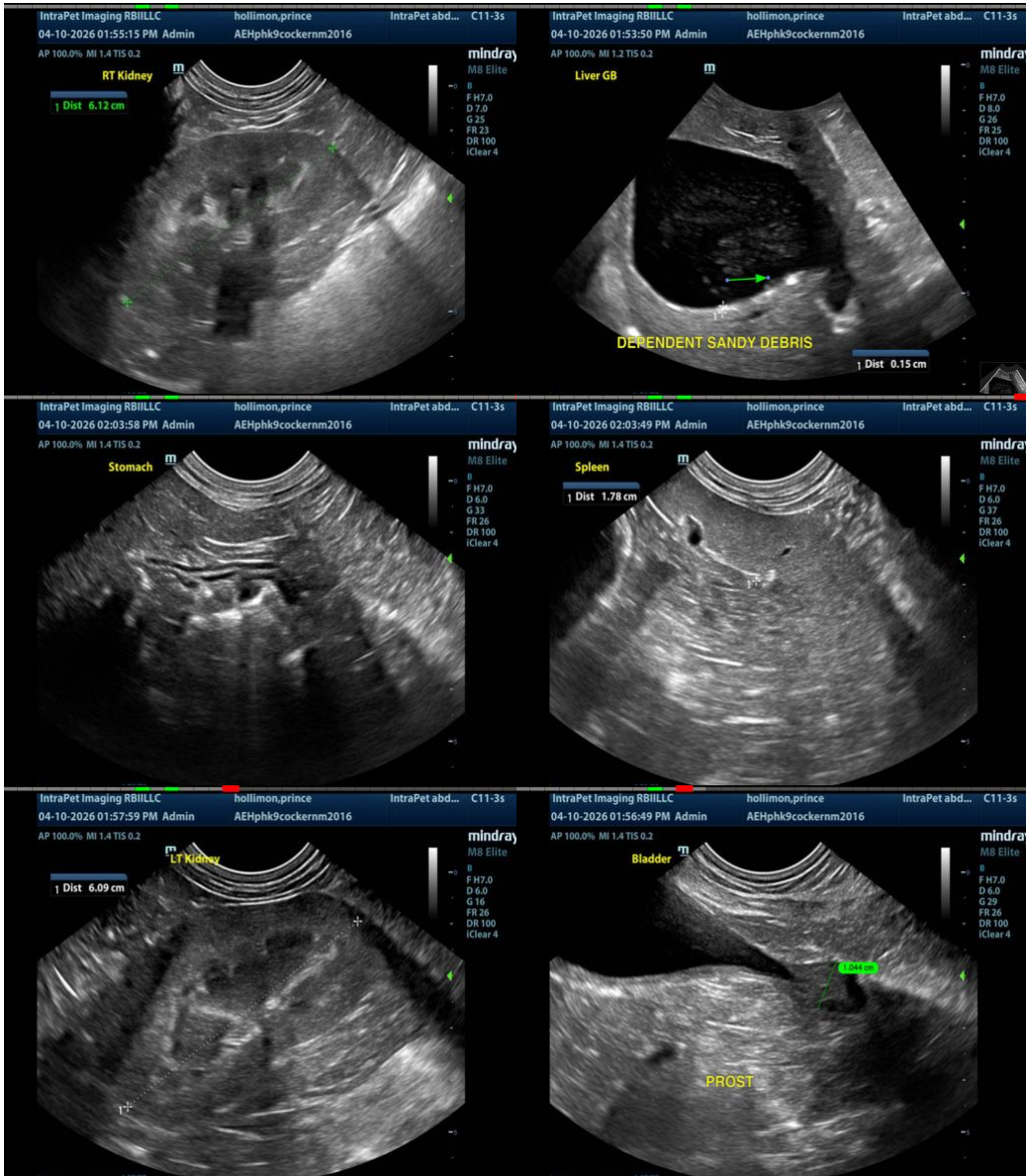
#### INTERPRETATION OF THE FINDINGS & FURTHER RECOMMENDATIONS

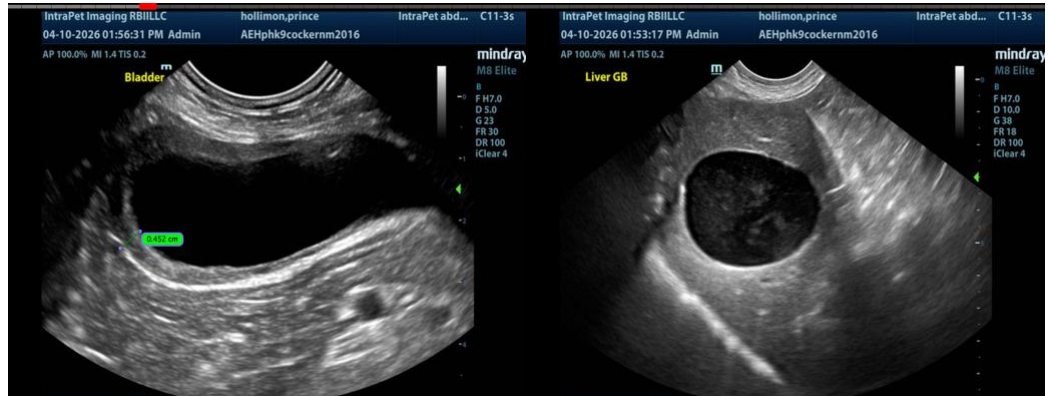
No focal lesions were visualized to explain the symptoms reported. The changes visualized associated with the liver are likely secondary to chronic steroid therapy. No obvious cause for the anemia is reported. This could be an anemia of chronic disease or similar.

It is uncertain if this patient has immune-mediated polyarthritis or similar. If possible, diagnostics should be considered to rule out infection, vector-borne disease, etc. A urinalysis and culture should be considered. If possible, joint taps would be helpful while off of steroids. If this is not an option, a long-term plan should be proposed with a goal of controlling symptoms at the lowest dose of immunosuppression possible. Often this involves the use of multiple immunosuppressives, etc., as every case is different.

The spleen is mildly mottled. The significance of this is uncertain. Options moving forward would include continued monitoring or a fine-needle aspirate.







The information and recommendations provided are based on the images presented by the referring veterinarian/sonographer. No evaluation can be communicated regarding pathology that was not visible in the image/video clips provided.

Thank you for this referral. If the clinical or image interpretation does not parallel your findings or if I can be of any further assistance, please contact me.

Kathleen Sennello DVM, MS, Diplomate ACVIM (Small animal Internal Medicine)

[info@sonopath.com](mailto:info@sonopath.com)