



**DATE PRESENTING CLINICAL SIGNS**

04/10/26 Patient History: Referral for low platelets, eating less, losing weight.

**PATIENT** Current Medications: None listed.

Labwork Results: Labwork not attached.

Moto Connelly Date of Previous IntraPet Ultrasound: No previous.

Sedation: Not required to complete full diagnostic ultrasound.

Stat Report: STAT requested.

**SPECIES** Imaging Performed by: Rachel Brillhart, RDMS.

Canine

**ULTRASONOGRAPHIC EXAMINATION OF THE ABDOMEN**

**BREED**

**Urinary System**

Golden Retriever

The urinary bladder is moderately distended with anechoic urine. The bladder wall, trigone, ureteral papillae and visible urethra (to a depth of 2.0 cm) appear normal with no evidence of wall thickening, mucosal irregularities, masses or cystic calculi.

**SEX**

Neutered Male

The visualized areas of prostate and surrounding tissue appear normal. Unfortunately, the prostate is not fully visualized likely due to its intrapelvic location. Correlate with rectal exam findings.

**AGE**

04/10/20

The left kidney has a normal shape and size (7.71 cm). Overall echogenicity is normal with adequate corticomedullary distinction and a typical 1:3 cortex:medulla ratio. There is no evidence of perinephric inflammation or effusion. There is no evidence of pyelectasia, nephroliths, infarcts or hydroureter. Renal vasculature is normal.

**WEIGHT**

97.2 pounds

The right kidney has a normal shape and size (7.38 cm). Overall echogenicity is normal with adequate corticomedullary distinction and a typical 1:3 cortex:medulla ratio. There is no evidence of perinephric inflammation or effusion. There is no evidence of pyelectasia, nephroliths, infarcts or hydroureter. Renal vasculature is normal.

**INTERPRETED BY**

Kathleen Sennello  
DVM, MS, Diplomate  
ACVIM (Small animal  
Internal Medicine)

**Adrenal Glands**

The left adrenal gland is normal in size measuring 0.58 cm at the cranial pole and 0.60 cm at the caudal pole. It is observed in its normal position cranial to the left renal artery. It is normal in appearance (uniformly hypoechoic) and shape with no evidence of a mass effect.

**HOSPITAL NAME**

Animal Emergency  
Hospital

The right adrenal gland is normal in size measuring 0.62 cm at the cranial pole and 0.67 cm at the caudal pole. It is observed in its normal position between the cranial aspect of the right kidney and the caudal vena cava. It is normal in appearance (uniformly hypoechoic) and shape with no evidence of a mass effect.

**REFERRING VET**

Dr. Willer

**Spleen**

The spleen is subjectively large in size (3.96 cm width at the level of the hilus). The spleen echotexture is heterogenous and mildly mottled, the splenic capsule is smooth with no irregularities. The blood flow through the hilus and splenic parenchyma appears normal. There's an ill-defined hypoechoic nodule visualized in the parenchyma measuring 1.31 cm.

**INVOICE**

15002

**Liver**

The liver is subjectively large in size, and echogenicity with smooth peripheral margins. The parenchyma is heterogenous and hypoechoic in echotexture with subtle, indistinct focal mottling. The visible portions of the vasculature and biliary tract appear normal. No focal nodules or cystic lesions are observed.

The gall bladder lumen is moderately distended. The wall of the gall bladder is not thickened and has a smooth mucosal surface. There is a moderate amount of non-organized echogenic debris. The cystic and common bile ducts are normal/not visible.

### ***Gastrointestinal***

The stomach contains focal shadowing ingesta. It measures at a normal thickness of <0.7 cm with some variability due to the presence of rugal folds. The distinction of the gastric wall layers is adequate and there is no impression of reduced peristaltic activity. Shadowing ingesta likely represents ingesta in this non-fasted patient.

The visualized areas of duodenum, jejunum and ileum have a relatively uniform diameter with minimal fluid distension. Wall thickness is normal. Bowel loops follow a curvilinear path with distinct wall layering maintaining the typical 1:3 muscularis: mucosa layer ratio. The duodenum measured as normal (between 0.3 - 0.5 cm in wall thickness) and the jejunum measured as normal (between 0.2 - 0.47 cm) Visualized peristalsis appears appropriate. There were no focal lesions consistent with obstruction or a mass effect observed.

Sections of colon are visualized with formed fecal material and gas shadowing distally. There is no observed focal or generalized colon wall thickening or loss of layering.

### ***Pancreas***

The area of the pancreas is normal and isoechoic to surrounding mesentery. There is no evidence of nodules or cystic lesions. There is no evidence of regional mesenteric inflammation or fluid.

### ***Free Abdomen***

Evaluation of the peritoneal cavity did not reveal any evidence of effusion. There is significant cranial abdominal lymphadenopathy with large hypoechoic lymph nodes in the portal region. Examples measure 1.8 cm by 2.82 cm, 1.68 cm by 2.9 cm, and 2.94 cm by 5.04 cm. The omentum is generally of normal echogenicity.

The right auricle and pericardium were visualized and were unremarkable. No obvious pathology is visualized. If cardiac function evaluation is desired a full echocardiogram is warranted.

## **ULTRASONOGRAPHIC FINDINGS**

- Subjectively large mildly mottled spleen with an ill-defined hypoechoic nodule- The diffuse splenic changes are non-specific and could be consistent with lymphoid hyperplasia, extramedullary hematopoiesis, infiltrative neoplasia, inflammation, other. Cytology or histopathology would be necessary to get a definitive diagnosis.
- Large heterogeneous hypoechoic liver- The diffuse hepatic changes are non-specific and could be consistent with vacuolar hepatopathy, nodular hyperplasia, inflammatory/immune-mediated disease, infiltrative neoplasia (less likely) or other hepatopathy.

- Moderate gallbladder debris- The significance of the aggregated gallbladder debris is unclear. This could represent an early mucocele, cholestasis, or may be secondary to fasting but seems unlikely to be causing a current issue. Recommend continued monitoring.
- Large hypoechoic cranial abdominal lymph nodes- Findings are most consistent with portal lymph nodes. Findings are concerning for neoplastic lymph nodes although highly reactive lymph nodes could have this appearance.

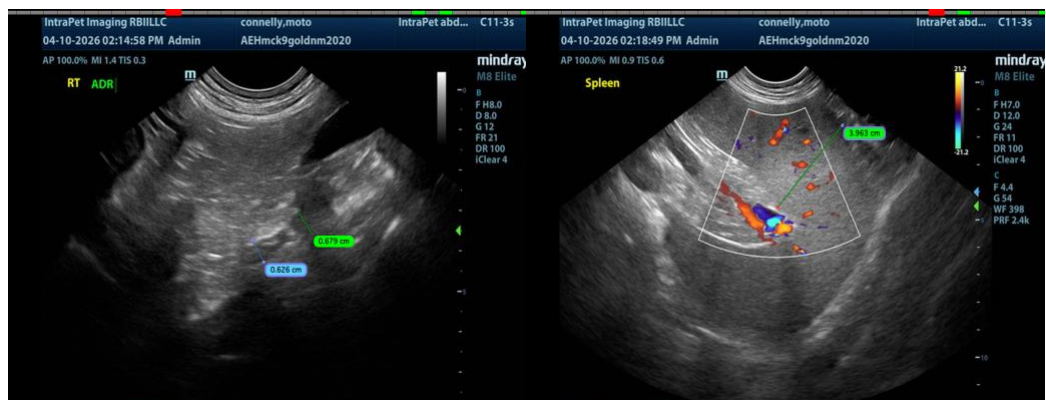
### INTERPRETATION OF THE FINDINGS & FURTHER RECOMMENDATIONS

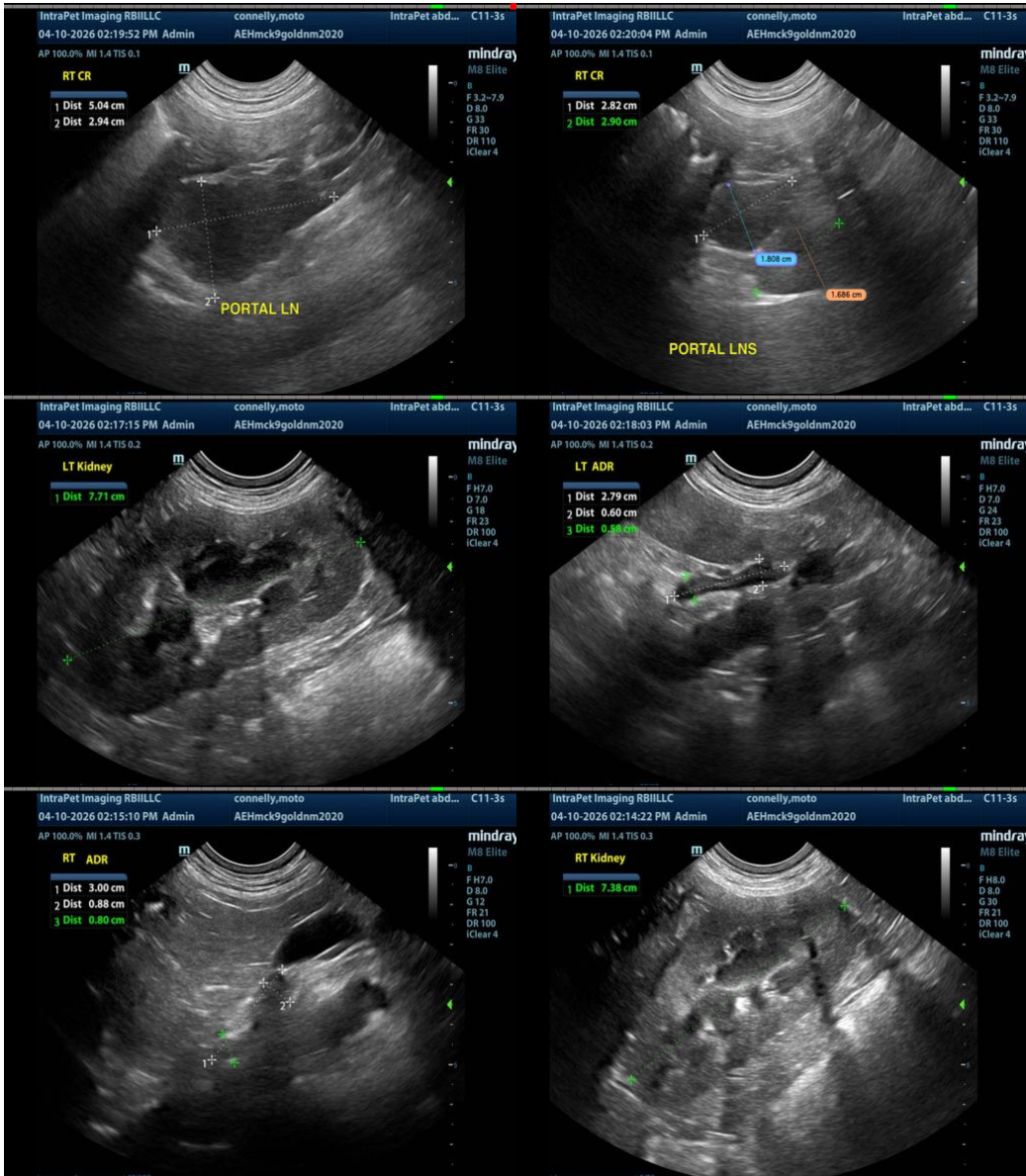
The liver is large and heterogeneous. Additionally, there are large lymph nodes in the portal region. These changes could be concerning for infiltrative disease to the liver. If platelet counts are above 75,000 and coagulation parameters are normal, consider fine needle aspirate of the liver.

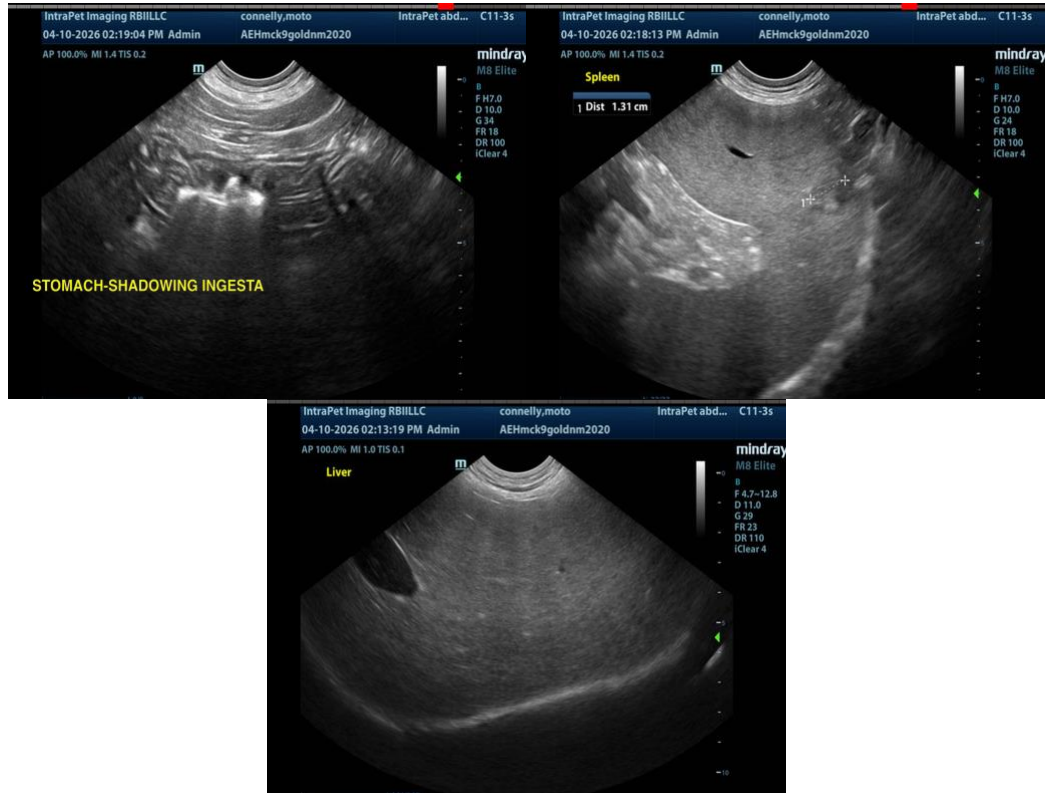
Additionally, the spleen appears large and somewhat heterogeneous with an ill-defined hypoechoic nodule. If platelet counts are adequate consider a fine needle aspirate.

The most likely differentials to consider would include an underlying neoplastic process, possibly vector-borne disease or autoimmune disease. Other differentials are possible. If aspirates cannot be performed, you could consider vector-borne disease testing and possibly a bone marrow aspirate if clinically appropriate (consider a pathologist review of the blood smear).

Recommend three view thoracic radiographs to evaluate for possible concurrent thoracic disease/involvement.







The information and recommendations provided are based on the images presented by the referring veterinarian/sonographer. No evaluation can be communicated regarding pathology that was not visible in the image/video clips provided.

Thank you for this referral. If the clinical or image interpretation does not parallel your findings or if I can be of any further assistance, please contact me.

Kathleen Sennello DVM, MS, Diplomate ACVIM (Small animal Internal Medicine)

info@sonopath.com