

**DATE PRESENTING CLINICAL SIGNS**

4/10/23 Recurrent UTI- has US on 3/21- uniform thickening- this scan is 1 week post Clavacillin and Carprofen (14 day course).

PATIENT

Maggie Mae Denning

Current Medications: Clavaxillin 250mg BID for 14 days, Carprofen 25mg BID for 14 days. (last dose was 4/4/23 for both).

Lab Results: UA- USG 1.029, pH 9, WBC, RBC >50 /hpf, bacteria (rods). Present struvite crystals. Urine C/S- pending.

SPECIES

Canine

Date of Previous IntraPet Ultrasound: 3/31/23. See attached.

Sedation: Not required to complete full diagnostic ultrasound.

Stat Report: Not requested.

BREED

Dachshund

Imaging Performed By: Rachel Brillhart, RDMS.

LIMITED ULTRASONOGRAPHIC EXAMINATION**SEX**

Spayed Female

Urinary System

The urinary bladder is mildly distended with anechoic urine. The Bladder wall is diffusely thickened and irregular, measuring 0.59 cm. Previous bladder wall measures from 3/21/23 was 0.81 cm. The area of the trigone and ureteral papillae appear relatively normal with no evidence of calculi or mass lesions. The urethra appears mildly thickened at 0.14 cm.

AGE

2/1/17

The left kidney has a normal shape and size (5.06 cm) with a small non-obstructive nephrolith measuring 0.70 cm. Overall echogenicity is slightly hyperechoic with poor corticomedullary distinction and a typical 1:3 cortex:medulla ratio. There is no evidence of focal perinephric inflammation or effusion. There is no evidence of pyelectasia, infarcts or hydroureter. Renal vasculature is normal.

WEIGHT

29.8 Pounds

The right kidney has a normal shape and size (5.55 cm). Overall echogenicity is slightly hyperechoic with poor corticomedullary distinction and a typical 1:3 cortex:medulla ratio. There is no evidence of focal perinephric inflammation or effusion. There is no evidence of pyelectasia, nephroliths, infarcts or hydroureter. Renal vasculature is normal.

INTERPRETED BY

Kathleen Sennello DVM,
MS, Diplomate ACVIM
(Small Animal Internal
Medicine)

Other

The sublumbar lymph node is isoechoic and prominent, measuring 0.64 cm in diameter (previous measurement was 0.44 cm)

HOSPITAL NAME

Eastern AH

ULTRASONOGRAPHIC FINDINGS**REFERRING VET**

Dr. Kaufman

- Diffusely thickened urinary bladder wall – The bladder wall appears slightly improved from the previous scan, but still significantly abnormal. Evidence of a persistent urinary tract infection is evident.
- Decreased corticomedullary distinction in both kidneys with a left-sided non-obstructive nephrolith – The bilateral renal findings are consistent with age-related change.
- Prominent sublumbar lymph node – This is most consistent with a reactive lymph node but continued monitoring is warranted.

INVOICE

46542

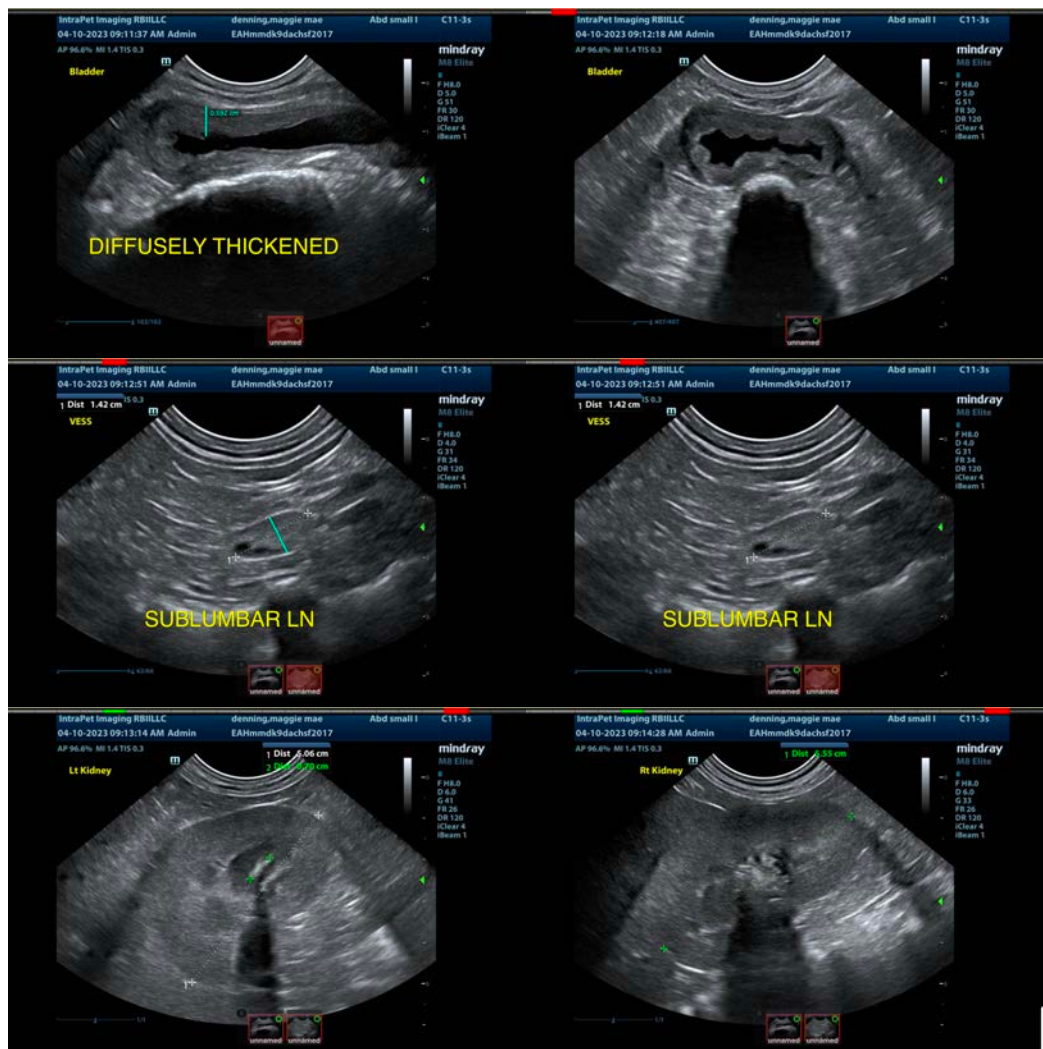
INTERPRETATION OF THE FINDINGS & FURTHER RECOMMENDATIONS

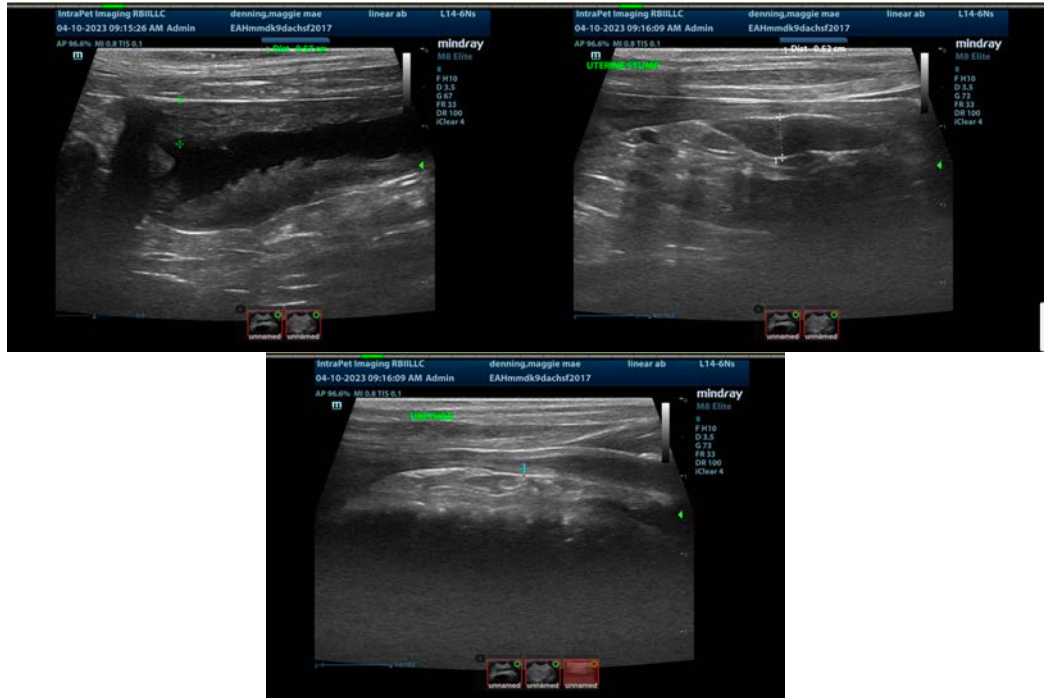
The urinary bladder wall appears slightly improved from the previous scan and more diffuse in appearance (no evidence of a focal mass effect). This patient should have a urinalysis and culture performed prior to treatment and a urinalysis and culture performed during treatment at two weeks while still on antibiotics if

the infection is still present, make any changes based on sensitivity results and continued treatment. Ideally, repeat this until the infection is clear and the urinary bladder wall appears normal on ultrasound, then consider reevaluation with a urinalysis and culture two weeks post-treatment. During this time, and likely at all times, this patient should be on chronic probiotic therapy, spaced out at least two hours from antibiotic therapy.

Based on these results, I suspect the urinary tract infection and bacterial cystitis is still present. There is concern that it can embed into the urinary bladder wall, so treatment should not be discontinued until you have a negative culture and the bladder wall appears normal. If these infections are unable to be cleared, then consider cystoscopy for further evaluation of possible anatomic causes and evaluation for systemic causes of recurrent urinary tract infection.

If the infection is cleared based on urinalysis and culture results (when off antibiotics), then my concern for an underlying neoplastic process would increase, and cytology from or biopsies from the bladder wall should be considered.





The information and recommendations provided are based on the images presented by the referring veterinarian/sonographer. No evaluation can be communicated regarding pathology that was not visible in the image/video clips provided.

Thank you for this referral. If the clinical or image interpretation does not parallel your findings or if I can be of any further assistance please contact me.

Kathleen Sennello DVM,MS, Diplomate ACVIM (Small animal Internal Medicine)
kathleen.sennello@sonopath.com