



PATIENT

Lewis Storey

SPECIES

Canine

BREED

Boston Terrier

SEX

Neutered Male

AGE

12

WEIGHT

24

INTERPRETED BY

Kathleen Sennello DVM,
MS, Diplomate ACVIM
(Small Animal Internal
Medicine)

IMAGING PERFORMED BY

Jenn

HOSPITAL NAME

Rockaway Animal
Hospital

REFERRING VET

Dr. Maniar

INVOICE

74108

DATE

4/1/26

PRESENTING CLINICAL SIGNS

Hx of diabetes, vomiting.

Abnormal PE/Chem/CBC/UA Results: Glu 504 Phos 8.5 K 142 ALT 154 ALP 321 T bili 1.2 Chol 321 Lipase 1313 U/A proteinuria Ketones present, RBCS present USG 1.036

ULTRASONOGRAPHIC EXAMINATION OF THE ABDOMEN

Urinary System

The urinary bladder is moderately distended with anechoic urine. The Bladder wall, trigone, ureteral papillae and visible urethra (to a depth of 2cm) appear normal with no evidence of wall thickening, mucosal irregularities, masses or cystic calculi.

The prostate is normal in size (0.80 cm) and shape for this neutered male dog. The parenchyma is homogenous and the external margins are smooth. The prostatic urethra appears normal with no evidence of irregularity, invasion, mass effect or calculi.

The left kidney has a normal shape and size (5.21 cm). Overall echogenicity is slightly hyperechoic with mildly reduced corticomedullary distinction and a typical 1:3 cortex:medulla ratio. There is no evidence of focal perinephric inflammation or effusion. There is no evidence of pyelectasia, nephroliths, infarcts or hydroureter. Renal vasculature is normal.

The right kidney has a normal shape and size (5.24 cm). Overall echogenicity is slightly hyperechoic with mildly reduced corticomedullary distinction and a typical 1:3 cortex:medulla ratio. There is no evidence of focal perinephric inflammation or effusion. There is no evidence of pyelectasia, nephroliths, infarcts or hydroureter. Renal vasculature is normal.

Adrenal Glands

The left adrenal gland is large, measuring 0.86 cm at the cranial pole and 0.83 cm at the caudal pole. It is observed in its normal position cranial to the left renal artery. It is normal in appearance (uniformly hypoechoic) and shape with no evidence of a mass effect.

The right adrenal gland is borderline "plump", measuring 0.85 cm at the cranial pole and 0.76 cm at the caudal pole. It is observed in its normal position between the cranial aspect of the right kidney and the caudal vena cava. It is normal in appearance (uniformly hypoechoic) and shape with no evidence of a mass effect.

Spleen

The spleen is subjectively normal in size (1.65 cm in width at the level of the hilus). The spleen echotexture is mildly mottled, the splenic capsule is smooth with no irregularities. The blood flow through the hilus and splenic parenchyma appears normal. No focal parenchymal abnormalities are visualized.

Liver

The liver is large in size, and normal in echogenicity with smooth peripheral margins. The parenchyma is heterogenous in echotexture with subtle, indistinct focal mottling. The visible portions of the vasculature and biliary tract appear normal. No focal nodules or cystic lesions are observed.



PATIENT

Lewis Storey

The gall bladder lumen is moderately distended. The wall of the gall bladder is not thickened and has a smooth mucosal surface. Luminal contents are mild and likely incidental at this time. The cystic and common bile ducts are normal/not visible.

SPECIES

Canine

Gastrointestinal

The stomach contains mild fluid. It measures at a normal thickness of <0.7cm with some variability due to the presence of rugal folds. The distinction of the gastric wall layers is adequate and there is no impression of reduced peristaltic activity. No masses or focal lesions were observed.

BREED

Boston Terrier

The visualized areas of duodenum, jejunum and ileum have a relatively uniform diameter with minimal fluid distension. Wall thickness is normal. Bowel loops follow a curvilinear path with distinct wall layering maintaining the typical 1:3 muscularis:mucosa layer ratio. Jejunum wall measures 0.25 cm. Visualized peristalsis appears appropriate. There were no focal lesions consistent with obstruction or a mass effect observed.

SEX

Neutered Male

AGE

12

Sections of colon are visualized with non-formed fecal material and gas shadowing distally. Descending colon wall is slightly prominent, measuring 0.21 cm with intact wall layering.

Pancreas

WEIGHT

24

The pancreas is prominent and hypoechoic as compared to the surrounding isoechoic mesentery. There is no evidence of nodules or cystic lesions. There is no evidence of regional mesenteric inflammation or fluid.

INTERPRETED BY

Kathleen Sennello DVM,
MS, Diplomate ACVIM
(Small Animal Internal
Medicine)

Free Abdomen

There is scant free fluid. No significant lymphadenopathy noted. The omentum is diffusely hyperechoic, particularly in the region of the spleen and pancreas.

ULTRASONOGRAPHIC FINDINGS

IMAGING PERFORMED BY

Jenn

- Borderline bilateral adrenomegaly – The bilateral adrenomegaly could be consistent with bilateral hyperplasia (e.g., secondary to pituitary-dependent hyperadrenocorticism), bilateral infiltrative neoplasia, inflammatory adrenal disease, other. Correlation with clinical findings is recommended.

HOSPITAL NAME

Rockaway Animal
Hospital

- Age related changes visualized associated with both kidneys.
- Mottled spleen – The diffuse splenic changes are non-specific and could be consistent with lymphoid hyperplasia, extramedullary hematopoiesis, infiltrative neoplasia, inflammation, other. Cytology or histopathology would be necessary to get a definitive diagnosis.

REFERRING VET

Dr. Maniar

- Pancreatic changes most consistent with chronic pancreatic remodeling +/- chronic pancreatitis.

INVOICE

74108

DATE

4/1/26

- Large, heterogeneous liver – The diffuse hepatic changes are non-specific and could be consistent with vacuolar hepatopathy, nodular hyperplasia, inflammatory/immune-mediated disease, fibrosis, extramedullary hematopoiesis, toxic hepatopathy (e.g., copper), infiltrative neoplasia (less likely) or other hepatopathy.



PATIENT

Lewis Storey

SPECIES

Canine

BREED

Boston Terrier

SEX

Neutered Male

AGE

12

WEIGHT

24

INTERPRETED BY

Kathleen Sennello DVM,
MS, Diplomate ACVIM
(Small Animal Internal
Medicine)

IMAGING PERFORMED BY

Jenn

HOSPITAL NAME

Rockaway Animal
Hospital

REFERRING VET

Dr. Maniar

INVOICE

74108

DATE

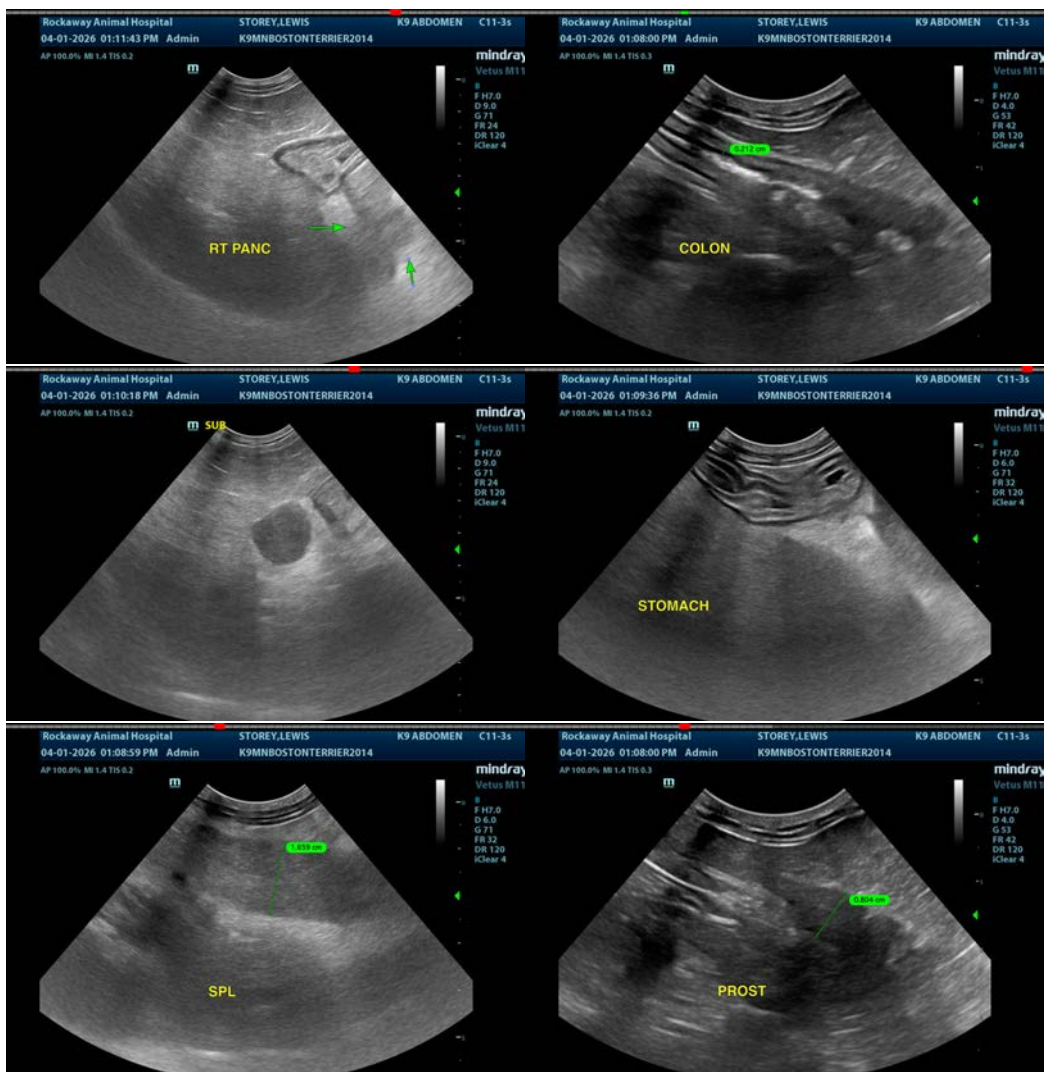
4/1/26

INTERPRETATION OF THE FINDINGS & FURTHER RECOMMENDATIONS

There is some evidence of generalized inflammation particularly in the cranial abdomen in the region of the spleen and pancreas. The spleen appears slightly mottled. Consider a fine needle aspirate for further evaluation and recommend concurrent treatment for pancreatitis and diabetic ketoacidosis.

The liver is large and heterogeneous. Findings are suggestive of a diabetic hepatopathy/vacuolar hepatopathy. Both adrenals are borderline large. This could be due to stress of current illness or possibly consistent with pituitary dependent hyperadrenocorticism. If symptoms consistent with Cushing's are present (insulin resistance, etc.), consider screening for Cushing's disease once the patient has recovered from this episode.

Treatment in this individual will likely require hospitalization for IV fluid support, injectable insulin, nutritional support, blood glucose monitoring, etc. Consider a urinalysis and culture, looking for any concurrent evidence of pyelonephritis/UTI.





PATIENT

Lewis Storey

SPECIES

Canine

BREED

Boston Terrier

SEX

Neutered Male

AGE

12

WEIGHT

24

INTERPRETED BY

Kathleen Sennello DVM,
MS, Diplomate ACVIM
(Small Animal Internal
Medicine)

IMAGING PERFORMED BY

Jenn

HOSPITAL NAME

Rockaway Animal
Hospital

REFERRING VET

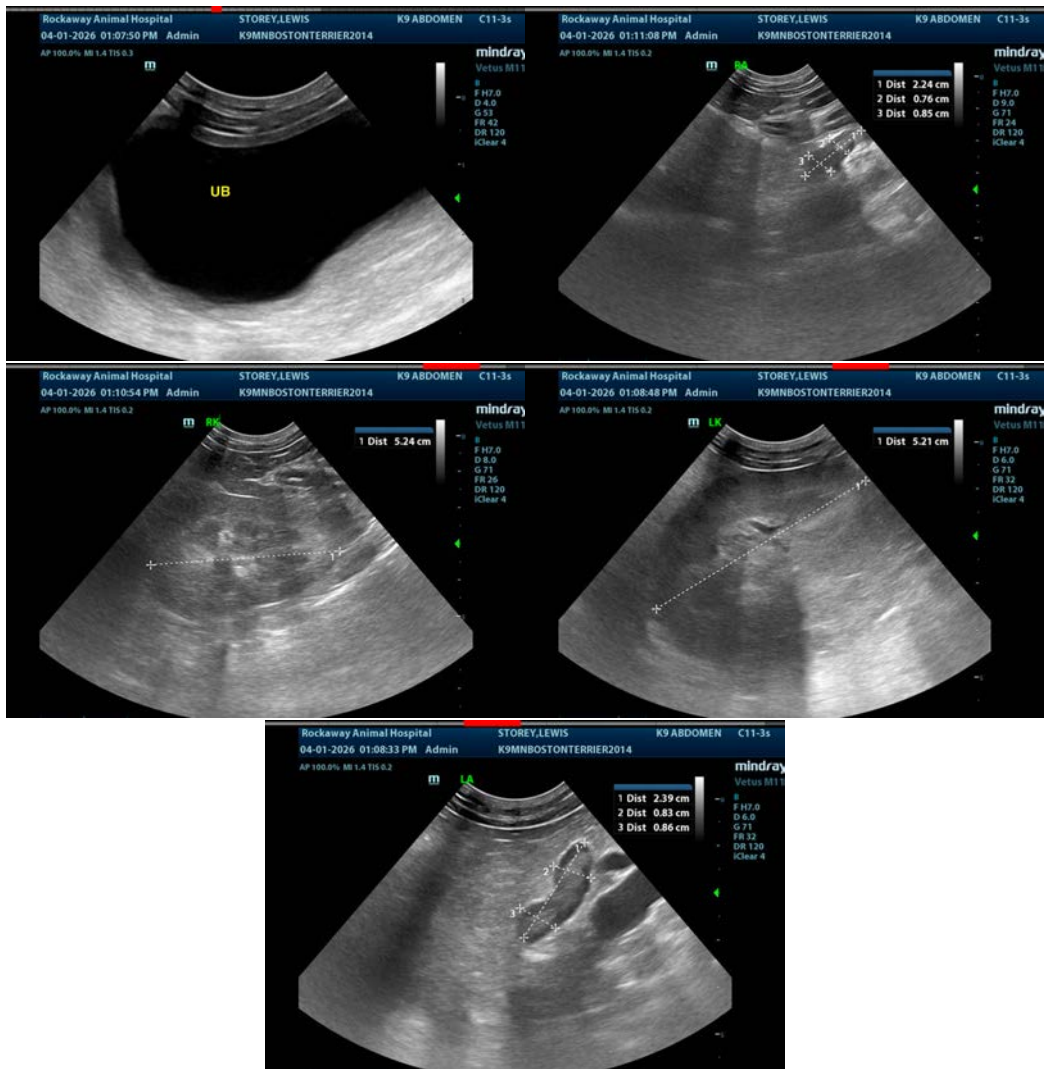
Dr. Maniar

INVOICE

74108

DATE

4/1/26



The information and recommendations provided are based on the images presented by the referring veterinarian/sonographer. No evaluation can be communicated regarding pathology that was not visible in the image/video clips provided.

Thank you for this referral. If the clinical or image interpretation does not parallel your findings or if I can be of any further assistance please contact me.

Kathleen Sennello DVM,MS, Diplomate ACVIM (Small animal Internal Medicine)

info@sonopath.com