



**PATIENT**

Benji Huffman

**SPECIES**

Canine

**BREED**

Shih Tzu

**SEX**

Neutered Male

**AGE**

1 Year

**WEIGHT**

23 lbs

**INTERPRETED BY**

Kathleen Sennello DVM,  
 MS, Diplomate ACVIM  
 (Small Animal Internal  
 Medicine)

**IMAGING PERFORMED BY**

Kathleen Byrnes

**HOSPITAL NAME**

Pet Care Clinic of the  
 High Country

**REFERRING VET**

Dr. Sturgill

**INVOICE**

74123

**DATE**

4/1/26

**PRESENTING CLINICAL SIGNS**

P sedated for US. P presented for US due to history of intermittent vomiting which has turned into daily vomiting over the past few days. Vomiting bile. Appetite and energy are normal. no diarrhea. Rads formed stool in colon. Food in stomach, no evidence of obstruction. Bloodwork unremarkable. Omeprazole 10mg, Drontal.

**ULTRASONOGRAPHIC EXAMINATION OF THE ABDOMEN**

**Urinary System**

The urinary bladder is moderately distended with anechoic urine. The Bladder wall, trigone, ureteral papillae and visible urethra (to a depth of 2cm) appear normal with no evidence of wall thickening, mucosal irregularities, masses or cystic calculi.

The prostate is normal in size (0.90 cm) and shape for this neutered male dog. The parenchyma is homogenous and the external margins are smooth. The prostatic urethra appears normal with no evidence of irregularity, invasion, mass effect or calculi.

The left kidney has a normal shape and size (4.79 cm) with mild pyelectasia at 0.14 cm. Overall echogenicity is normal with adequate corticomedullary distinction and a typical 1:3 cortex:medulla ratio. There is no evidence of focal perinephric inflammation or effusion. There is no evidence of nephroliths, infarcts or hydroureter. Renal vasculature is normal.

The right kidney has a normal shape and size (5.11 cm). Overall echogenicity is normal with adequate corticomedullary distinction and a typical 1:3 cortex:medulla ratio. There is no evidence of focal perinephric inflammation or effusion. There is no evidence of pyelectasia, nephroliths, infarcts or hydroureter. Renal vasculature is normal.

**Adrenal Glands**

The left adrenal gland is normal in size measuring 0.36 cm at the cranial pole and 0.40 cm at the caudal pole. It is observed in its normal position cranial to the left renal artery. It is normal in appearance (uniformly hypoechoic) and shape with no evidence of a mass effect.

The right adrenal gland is normal in size measuring 0.68 cm at the cranial pole and 0.33 cm at the caudal pole. It is observed in its normal position between the cranial aspect of the right kidney and the caudal vena cava. It is normal in appearance (uniformly hypoechoic) and shape with no evidence of a mass effect.

**Spleen**

The spleen is subjectively normal in size (1.53 cm), echotexture is homogenous, and the splenic capsule is smooth with no irregularities. The blood flow through the hilus and splenic parenchyma appears normal. No focal parenchymal abnormalities are visualized.

**Liver**

The liver is subjectively normal in size, and echogenicity with smooth peripheral margins. The parenchyma is homogenous echotexture. The visible portions of the vasculature and biliary tract appear normal. No focal nodules or cystic lesions are observed.



**PATIENT**

Benji Huffman

The gall bladder lumen is moderately distended. The wall of the gall bladder is not thickened and has a smooth mucosal surface. Luminal contents are mild and likely incidental at this time. The cystic and common bile ducts are normal/not visible.

**SPECIES**

Canine

***Gastrointestinal***

The stomach contains minimal luminal contents. It measures at a normal thickness of <0.23 cm with some variability due to the presence of rugal folds. The distinction of the gastric wall layers is adequate and there is no impression of reduced peristaltic activity. No masses or focal lesions were observed.

**BREED**

Shih Tzu

The visualized areas of duodenum, jejunum and ileum have a relatively uniform diameter with minimal fluid distension. Wall thickness is normal. Bowel loops follow a curvilinear path with distinct wall layering maintaining the typical 1:3 muscularis:mucosa layer ratio. Duodenum wall measures 0.45 cm. Jejunum wall measures 0.28 cm. Visualized peristalsis appears appropriate. There were no focal lesions consistent with obstruction or a mass effect observed.

**SEX**

Neutered Male

**AGE**

1 Year

The ileocecal junction was visualized and exhibited normal intact wall layering and is subjectively of normal thickness. Sections of colon are visualized with formed fecal material and gas shadowing distally. There is no observed focal or generalized colon wall thickening or loss of layering.

**WEIGHT**

23 lbs

***Pancreas***

The pancreas is normal and isoechoic to surrounding mesentery. There is no evidence of nodules or cystic lesions. There is no evidence of regional mesenteric inflammation or fluid.

**INTERPRETED BY**

Kathleen Sennello DVM,  
 MS, Diplomate ACVIM  
 (Small Animal Internal  
 Medicine)

***Free Abdomen***

Evaluation of the peritoneal cavity did not reveal any evidence of effusion. There are occasional prominent jejunal lymph nodes. An example measures 0.81 cm. The omentum is of normal echogenicity.

**IMAGING PERFORMED BY**

Kathleen Byrnes

**ULTRASONOGRAPHIC FINDINGS**

- Very mild left-sided pyelectasia – Findings could be consistent with anatomic variation, PU/PD, fluid therapy, pyelonephritis, less likely an obstructive process.
- Occasional prominent mesenteric lymph nodes – Findings are most consistent with mildly reactive lymph nodes.

**HOSPITAL NAME**

Pet Care Clinic of the  
 High Country

**INTERPRETATION OF THE FINDINGS & FURTHER RECOMMENDATIONS**

No focal lesions were visualized associated with the gastrointestinal tract to explain the chronic vomiting reported. Unfortunately, there are many causes for vomiting that cannot be definitively diagnosed by ultrasound alone. Consider the following:

**REFERRING VET**

Dr. Sturgill

- Recommend a diet trial with a hydrolyzed protein prescription diet.
- If not already done, recommend parasite screening and empirical deworming.
- Recommend a baseline cortisol to screen for atypical Addison's.
- Consider a GI panel to Texas A&M for evaluation of B12 levels, folate, PLI/TLI etc.. to further evaluate for pancreatic/small intestinal disease.

**INVOICE**

74123

**DATE**

4/1/26

If symptoms are persistent despite these measures, ultimately biopsies of the GI tract may be warranted (upper GI endoscopy?).



**PATIENT**

Benji Huffman

**SPECIES**

Canine

**BREED**

Shih Tzu

**SEX**

Neutered Male

**AGE**

1 Year

**WEIGHT**

23 lbs

**INTERPRETED BY**

Kathleen Sennello DVM,  
 MS, Diplomate ACVIM  
 (Small Animal Internal  
 Medicine)

**IMAGING  
 PERFORMED BY**

Kathleen Byrnes

**HOSPITAL NAME**

Pet Care Clinic of the  
 High Country

**REFERRING VET**

Dr. Sturgill

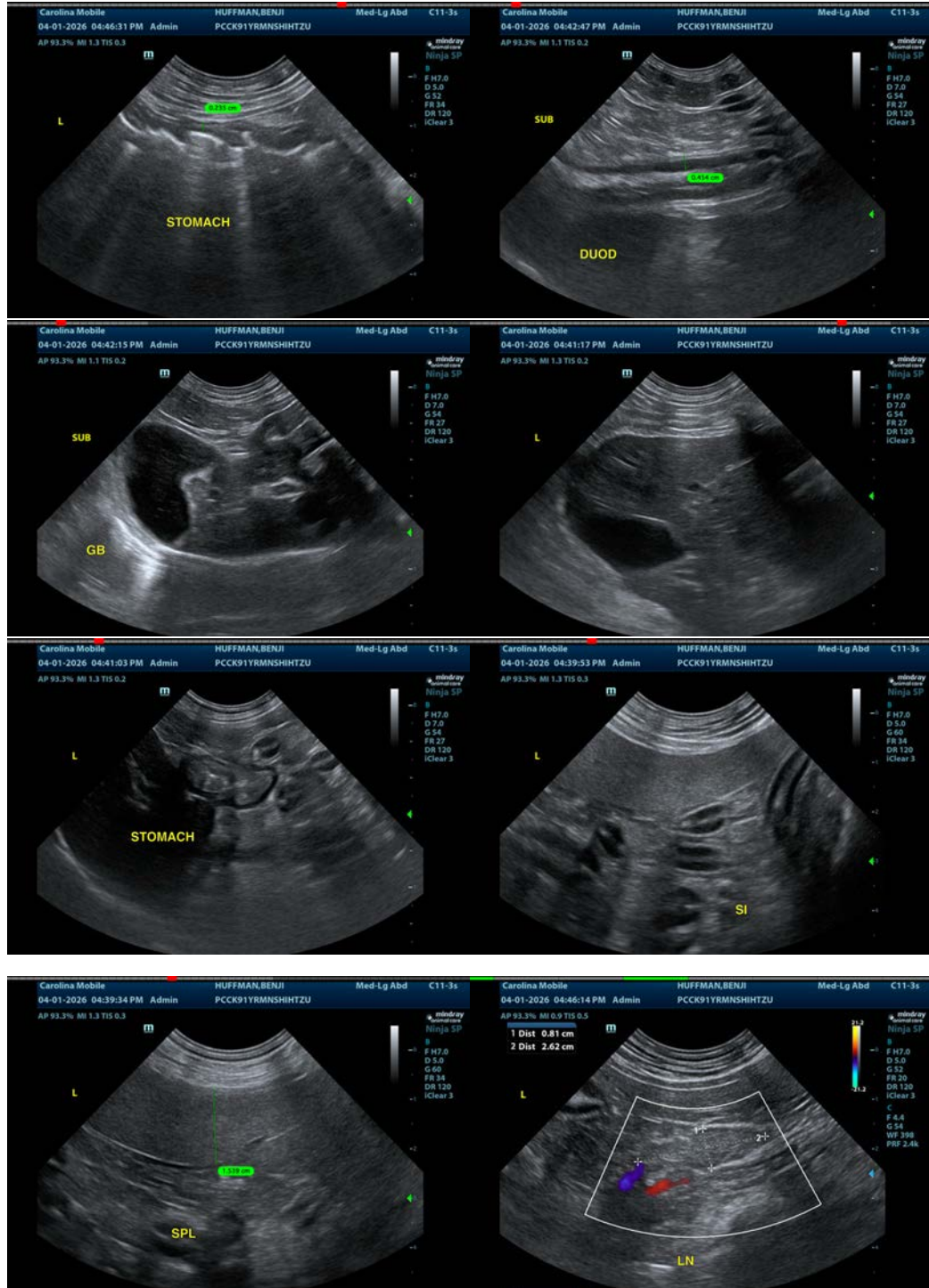
**INVOICE**

74123

**DATE**

4/1/26

There is very mild pyelectasia visualized associated with the left kidney. I suspect this is incidental. Correlate with urinalysis +/- culture results.





**PATIENT**

Benji Huffman

**SPECIES**

Canine

**BREED**

Shih Tzu

**SEX**

Neutered Male

**AGE**

1 Year

**WEIGHT**

23 lbs

**INTERPRETED BY**

Kathleen Sennello DVM,  
 MS, Diplomate ACVIM  
 (Small Animal Internal  
 Medicine)

**IMAGING  
 PERFORMED BY**

Kathleen Byrnes

**HOSPITAL NAME**

Pet Care Clinic of the  
 High Country

**REFERRING VET**

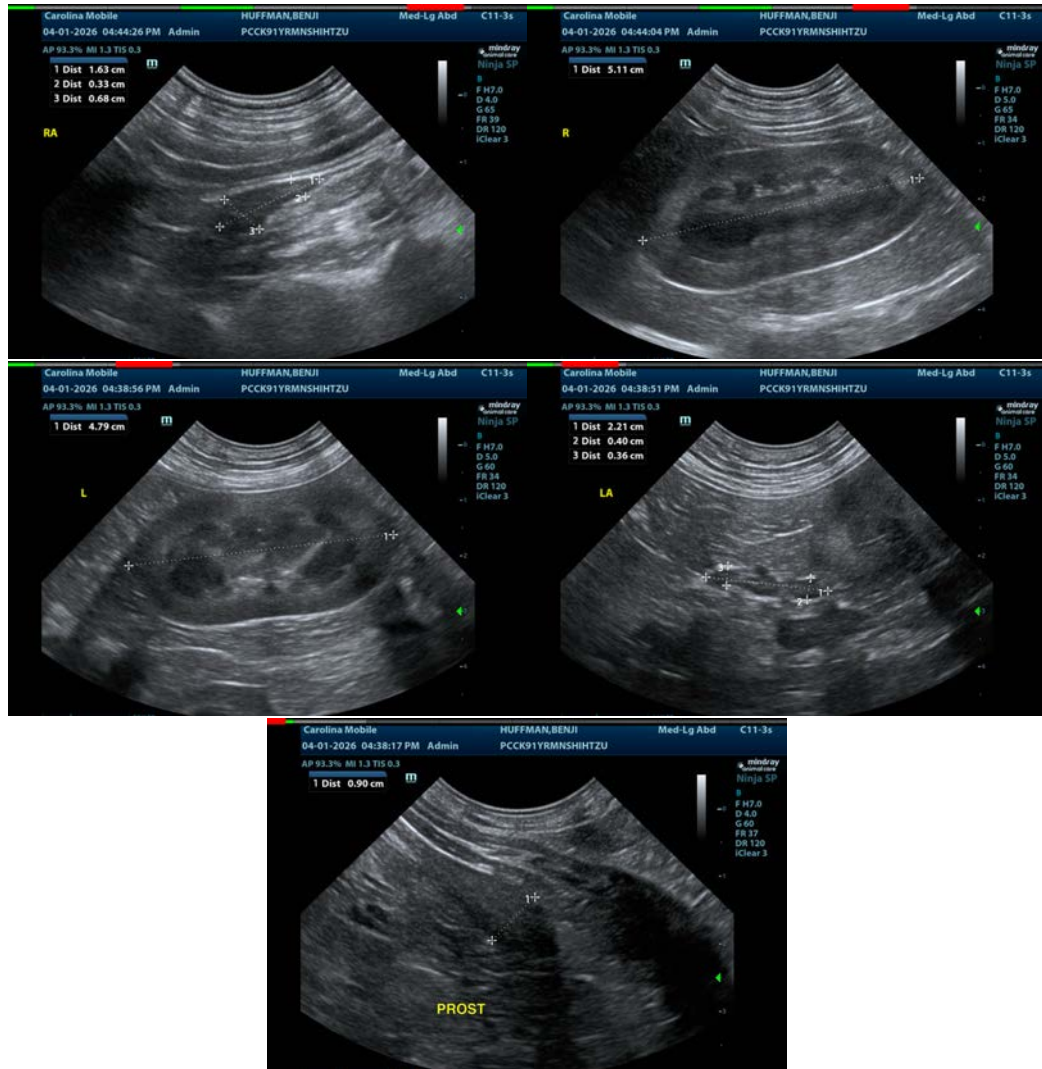
Dr. Sturgill

**INVOICE**

74123

**DATE**

4/1/26



The information and recommendations provided are based on the images presented by the referring veterinarian/sonographer. No evaluation can be communicated regarding pathology that was not visible in the image/video clips provided.

Thank you for this referral. If the clinical or image interpretation does not parallel your findings or if I can be of any further assistance please contact me.

Kathleen Sennello DVM,MS, Diplomate ACVIM (Small animal Internal Medicine)

info@sonopath.com