

**DATE PRESENTING CLINICAL SIGNS**

4/1/22

Urinary problems initially started last summer; in July was seen at ER (in NC; owners are in town visiting family currently); had ultrasound; owner thinks they saw thickening of bladder wall. Increased frequency of urination, stranguria symptoms have been worsening gradually since then. Last week (7 days ago) went back to ER for being unable to urinate. Would occasionally dribble urine but was not producing good stream. They suspect a urolith in urethra vs neoplasia; FNA was not conclusive. (showed suppurative inflammation) Owner believes full bloodwork was done last week as well as ultrasound but was not included in records sent over today; she will call tomorrow to get additional diagnostic results sent.

PATIENTZiggy Stardust
McCafferty**SPECIES**

Canine

Current Medications: Prazosin, Gabapentin, Vetoryl, Trazodone, Maropitant.

Lab Results: cytology from traumatic catheterization- chronic suppurative inflammation- no neoplastic cells seen

BREED

Shih Tzu

Radiographs: Echo 3/18/2022- mild cardiac changes- no heart medications needed. Ultrasound from ER clinic in NC 3/23/22 - pinpoint urethroliths (prostatic urethra), bilateral enlargement of the adrenals glands

Date of Previous IntraPet Ultrasound: No previous.

SEX

Neutered Male

Sedation: Not required to complete full diagnostic ultrasound.

Stat Report: Not requested.

ULTRASONOGRAPHIC EXAMINATION OF THE ABDOMEN**AGE**

10/28/09

Urinary System

On initial views, the urinary bladder is empty with an indwelling foley catheter in place. On these images, the urinary bladder wall is somewhat thickened diffusely and measures at 0.82 cm. On subsequent images, the urinary bladder is instilled with saline via the urinary catheter, providing moderate distention. In these images, there is still mild irregularity to the urinary bladder wall, and it measures at 0.52 cm. Additionally, the fluid/urine within the urinary bladder is highly echogenic, and there are some larger shadowing, hyperechoic densities, most consistent with mobile sandy debris and possibly small stones. The area of the urethra cannot be further evaluated due to the presence of an indwelling catheter. No mass lesions are visualized.

WEIGHT

22 Pounds

INTERPRETED BYKathleen Sennello DVM,
MS, Diplomate ACVIM
(Small Animal Internal
Medicine)

The prostate is somewhat difficult to evaluate due to the presence of an indwelling urinary catheter. With the urinary catheter in place within the prostatic urethra, the prostate measures at 1.2 cm in diameter when viewed in the sagittal view. It does not appear irregular or enlarged, but there is a small, non-shadowing hyperechoic focus visualized within the parenchyma.

IMAGING PERFORMED BY

Andi Parkinson RDMS

The left kidney has a normal shape and size (4.64 cm). Overall echogenicity is slightly hyperechoic with poor corticomedullary distinction and a typical 1:3 cortex:medulla ratio. There is no evidence of perinephric inflammation or effusion. There is no evidence of pyelectasia, nephroliths, infarcts or hydroureter. Renal vasculature is normal.

HOSPITAL NAMEAnimal Emergency
Hospital

The right kidney has a normal shape and size (4.8 cm). Overall echogenicity is slightly hyperechoic with poor corticomedullary distinction and a typical 1:3 cortex:medulla ratio. There is no evidence of perinephric inflammation or effusion. There is no evidence of pyelectasia, nephroliths, infarcts or hydroureter. Renal vasculature is normal.

REFERRING VET

Dr. Martinoli

Adrenal Glands

The left adrenal gland is large in size and irregular shape. It measures 1.51 cm at the cranial pole, 0.73 cm at the caudal pole, and 2.8 cm in length. It is located in its normal position cranial to the left renal artery. It is irregular in appearance in that the cranial pole is enlarged and hyperechoic due to a nodule in this location measuring 2.0 cm x 1.5 cm. Findings are most consistent with a nodule within the cranial pole of the left adrenal gland. There is no evidence of vascular invasion visualized.

INVOICE

36650

The right adrenal gland is normal/borderline enlarged in size measuring 0.94 cm at the caudal pole. It is observed in its normal position between the cranial aspect of the right kidney and the caudal vena cava. It is normal in appearance (uniformly hypoechoic) and shape with no evidence of a mass effect.

Spleen

The spleen is subjectively normal in size, echotexture is homogenous, and the splenic capsule is smooth with no irregularities. The blood flow through the hilus and splenic parenchyma appears normal. No focal parenchymal abnormalities are visualized.

Liver

The liver is subjectively normal in size, and echogenicity with smooth peripheral margins. The parenchyma is mildly heterogenous in echotexture with subtle, indistinct focal mottling. The visible portions of the vasculature and biliary tract appear normal. No focal nodules or cystic lesions are observed. There is a small hypoechoic nodule visualized measuring 0.72 cm x 0.61 cm.

The gall bladder lumen is significantly distended. Some areas of the wall appear mildly thickened with adherent debris. There is a large amount of primarily non-organized echogenic debris. There is no evidence of bile duct dilation. These changes can be consistent with an early gall bladder mucocele.

Gastrointestinal

The stomach contains minimal luminal contents. It measures at a normal thickness of <0.7cm with some variability due to the presence of rugal folds. The distinction of the gastric wall layers is adequate and there is no impression of reduced peristaltic activity. No masses or focal lesions were observed.

The visualized areas of duodenum, jejunum and ileum have a relatively uniform diameter with minimal fluid distension. Wall thickness is normal. Bowel loops follow a curvilinear path with distinct wall layering maintaining the typical 1:3 muscularis:mucosa layer ratio. Jejunum wall measured 0.26 cm. Visualized peristalsis appears appropriate. There were no focal lesions consistent with obstruction or a mass effect observed.

The ileocecal junction was visualized and exhibited normal intact wall layering and is subjectively of normal thickness. Sections of colon are visualized with formed fecal material and gas shadowing distally. There is no observed focal or generalized colon wall thickening or loss of layering.

Pancreas

The pancreas is prominent and mottled compared to the surrounding isoechoic mesentery. There is no evidence of nodules or cystic lesions. There is no evidence of regional mesenteric inflammation or fluid.

Free Abdomen

Evaluation of the peritoneal cavity did not reveal any evidence of effusion, or subjective lymphadenomegaly. The Medial iliac nodes appear normal and there was no evidence of a caudal aortic thrombus at the bifurcation. The omentum is of normal uniform echogenicity.

PRIMARY FINDINGS

- Thickened urinary bladder wall with mild mucosal irregularity, severely echogenic urine, and mobile sandy debris/small stones – Findings are most consistent with bacterial cystitis and sandy debris. No obvious large stones are visualized and no mass effects are seen. Evaluation of the urethra is impaired due to the presence of an indwelling urinary catheter.
- Hyperechoic nodule in the cranial pole of the left adrenal gland – Left adrenomegaly could be consistent with neoplasia (e.g., adenoma, carcinoma, pheochromocytoma), hyperplasia, inflammation, other.

- Decreased corticomedullary distinction in both kidneys – The bilateral renal findings are consistent with age-related change.
- Prominent, mottled pancreas – The pancreatic changes are most consistent with mild pancreatitis or a recent episode of pancreatic inflammation.
- Heterogeneous liver with small hypoechoic nodule – The diffuse hepatic changes are non-specific and could be consistent with vacuolar hepatopathy, nodular hyperplasia, inflammatory/immune-mediated disease, fibrosis, extramedullary hematopoiesis, toxic hepatopathy (e.g., copper), infiltrative neoplasia (less likely) or other hepatopathy.
- Large amount of gallbladder sludge – There is a large amount of debris in the gallbladder with some signs of early organization, consistent with an early developing mucocele.

SECONDARY FINDINGS

- Small, hyperechoic, non-shadowing focus in the prostatic parenchyma – The significance of this lesion is unclear. The prostate itself does not appear enlarged, but is difficult to evaluate due to the indwelling urinary catheter present.

INTERPRETATION OF THE FINDINGS & FURTHER RECOMMENDATIONS

Correlate these findings with radiographs taken at the time of obstruction, as it is possible that much of the debris and small stones could have been evacuated at the time of initial urinary catheter placement. Correlate with current abdominal radiographs. There is the possibility that there is enough of the sandy debris collected in the urethra to cause an obstruction. It is also possible that there is a urethral mass present, or some other issue.

- Recommend urinalysis and culture (hopefully this is pending).
- Consider flushing out the urinary bladder with the catheter in place to try to remove some of the debris present.
- Treat for bacterial cystitis.
- You could consider a urine BRAF test. If this test was positive, it would increase concern for possible underlying neoplastic process, although this is not a definitive test, and a negative BRAF test is inconclusive.

Additionally, there is a hyperechoic nodule visualized in the left adrenal gland. These nodules can be benign or malignant, and can secrete hormones or be non-active.

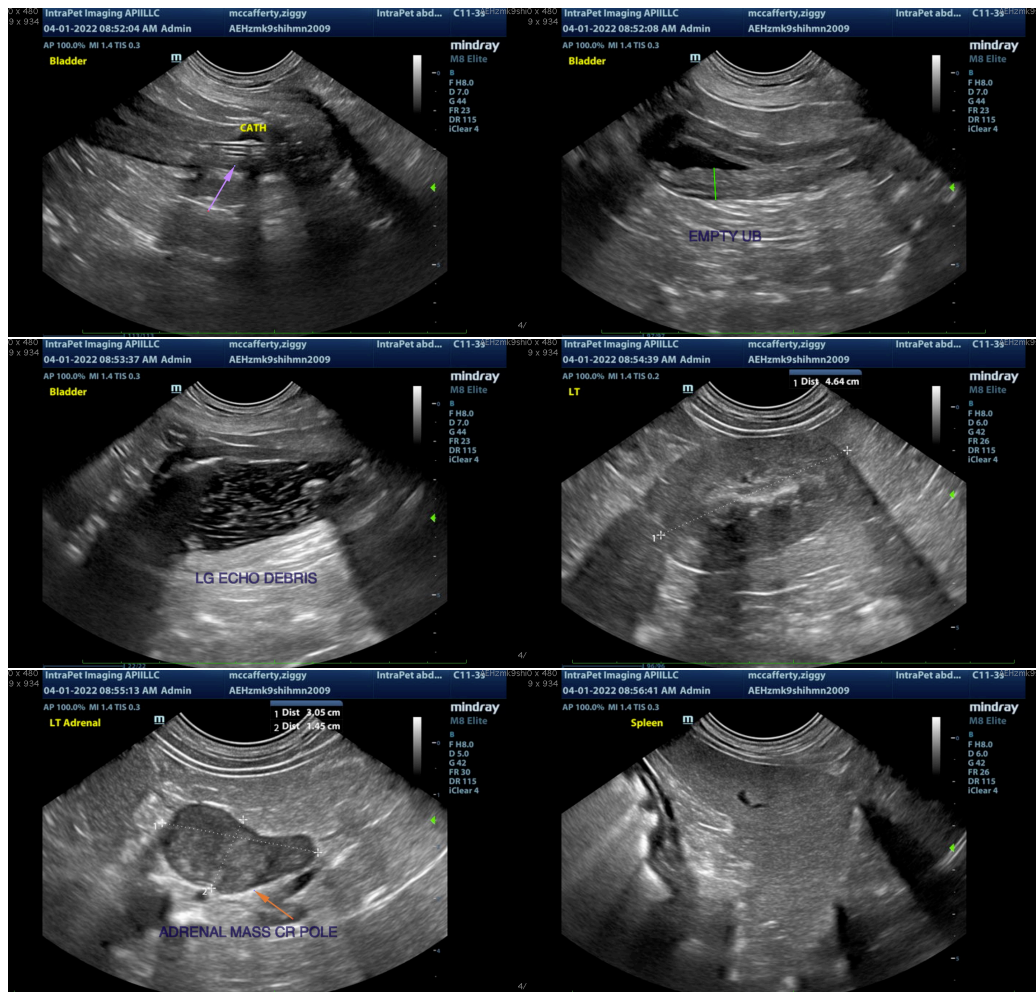
- If signs of cushings are present, consider adrenal function testing. I prefer an ACTH stimulation test combined with an adrenal panel to the University of Tennessee's endocrine lab to look for atypical adrenal hormones as well as cortisol. (other testing can suffice). Adrenal function testing should be done once this patient is feeling better, stabilized at home, and not stressed.
- If adrenal dependent cushings is suspected and supported by adrenal function testing consider medical therapy with lysodren or trilostane or consider surgical removal (recommend referral to a board certified veterinary surgeon and possible pre op CT)

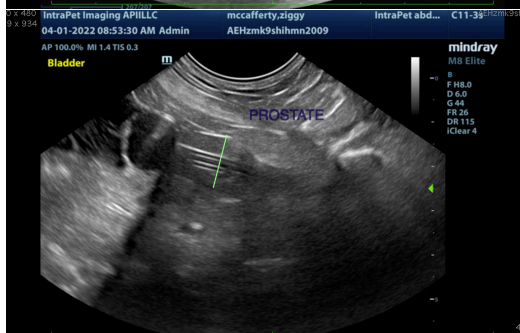
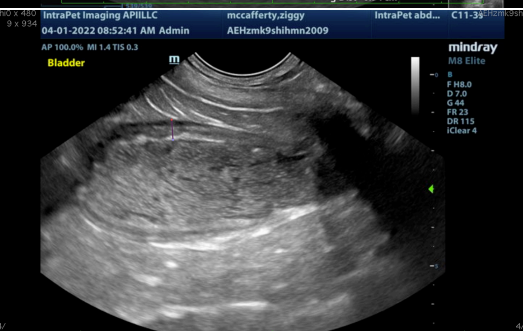
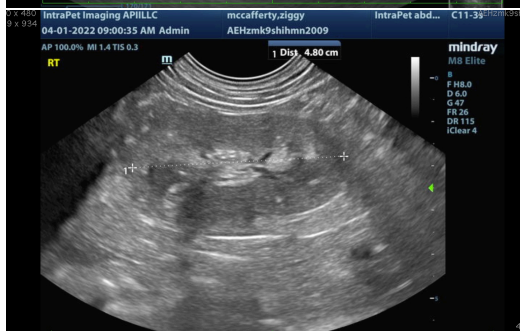
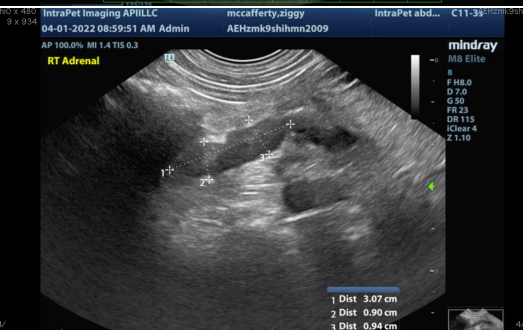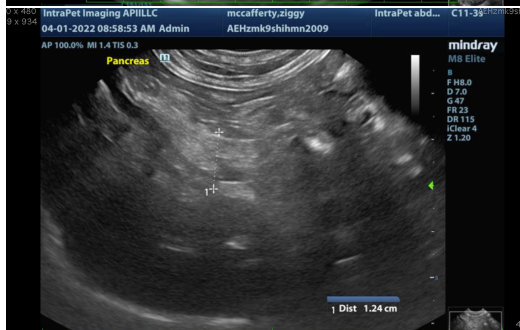
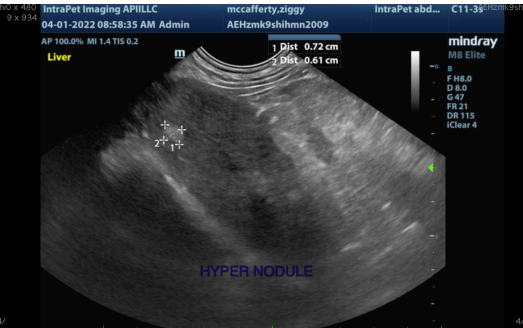
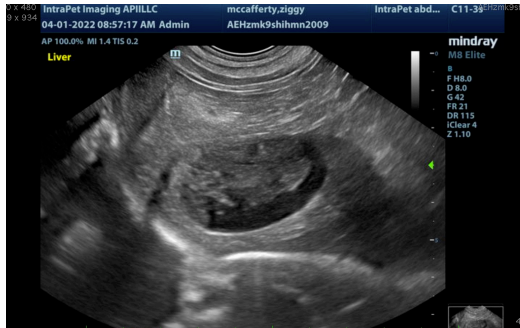- Recommend blood pressure evaluation-if hypertensive consider testing catecholamine levels for a possible pheochromocytoma
- If no symptoms of cushings are present, consider either referral for surgery or continued monitoring with ultrasound (in 6-8 weeks).
- Many of these nodules can be benign and incidental in nature, unfortunately others can be more aggressive with rapid growth, etc. Unfortunately, this is difficult to determine with a single ultrasound.

Consider three view thoracic radiographs to rule out concurrent thoracic disease/involvement.

The gallbladder has a large amount of early organizing sludge within its lumen. Consider starting Ursodiol and continue to monitor the gallbladder for progression of this lesion.

The liver is mildly heterogeneous and there is a small hypoechoic nodule visualized. This trends towards a more benign appearing nodule, but should continue to be monitored. Additionally, the pancreas is prominent. If signs of pancreatitis are present, then consider measuring a quantitative PLI test and initiating supportive treatment for pancreatitis.





The information and recommendations provided are based on the images presented by the referring veterinarian/sonographer. No evaluation can be communicated regarding pathology that was not visible in the image/video clips provided.

Thank you for this referral. If the clinical or image interpretation does not parallel your findings or if I can be of any further assistance please contact me.

Kathleen Sennello DVM,MS, Diplomate ACVIM (Small animal Internal Medicine)
kathleen.sennello@sonopath.com