

**DATE PRESENTING CLINICAL SIGNS**

3/9/23

History: 3/1/23- lethargic and anorexic for 3 days with vomiting. Xrays- no obvious cause for clinical signs. 3/2/23- o returns for BW d/t concern for lepto. All normal and negative blood and urine PCR for lepto. Fecal parasite test- neg. O reports no more vomiting but persistent lethargy and having to hand feed.

PATIENT

Jolene Kramer

Current Medications: None.

Lab Results: See attached.

SPECIES

Radiographs: See attached.

Canine

Date of Previous IntraPet Ultrasound: No previous.

Sedation: Telazol IV.

BREED

Stat Report: Not requested.

Imaging Performed By: Stephanie Warga RDCS, RVT.

Hound Mix

ULTRASONOGRAPHIC EXAMINATION OF THE ABDOMEN**SEX****Urinary System**

Spayed Female

The urinary bladder is moderately distended with anechoic urine. The bladder wall, trigone, ureteral papillae and visible urethra (to a depth of 2.0 cm) appear normal with no evidence of wall thickening, mucosal irregularities, masses or cystic calculi.

AGE

10/17/2021

The left kidney has a normal shape and size (5.63 cm). Overall echogenicity is normal with adequate corticomedullary distinction and a typical 1:3 cortex:medulla ratio. There is no evidence of perinephric inflammation or effusion. There is no evidence of pyelectasia, nephroliths, infarcts or hydroureter. Renal vasculature is normal.

WEIGHT

46 Pounds

The right kidney has a normal shape and size (5.39 cm). Overall echogenicity is normal with adequate corticomedullary distinction and a typical 1:3 cortex:medulla ratio. There is no evidence of perinephric inflammation or effusion. There is no evidence of pyelectasia, nephroliths, infarcts or hydroureter. Renal vasculature is normal.

INTERPRETED BY

Kathleen Sennello DVM,
MS, Diplomate ACVIM
(Small Animal Internal
Medicine)

Adrenal Glands

The left adrenal gland is normal in size measuring 0.45 cm at the caudal pole. It is observed in its normal position cranial to the left renal artery. It is normal in appearance (uniformly hypoechoic) and shape with no evidence of a mass effect.

HOSPITAL NAME

Alexander AH

The right adrenal gland is normal in size measuring 0.48 cm at the caudal pole. It is observed in its normal position between the cranial aspect of the right kidney and the caudal vena cava. It is normal in appearance (uniformly hypoechoic) and shape with no evidence of a mass effect.

REFERRING VET

Dr. Alexander

Spleen

The spleen is subjectively normal in size. The spleen echotexture is heterogenous and subjectively mildly mottled, the splenic capsule is smooth with no irregularities. The blood flow through the hilus and splenic parenchyma appears normal. No focal parenchymal abnormalities are visualized.

INVOICE

21536

Liver

The liver is subjectively normal in size, and echogenicity with smooth peripheral margins. The parenchyma is homogenous echotexture. The visible portions of the vasculature and biliary tract appear normal. No focal nodules or cystic lesions are observed.

The gall bladder lumen is moderately distended. The wall of the gall bladder is not thickened and has a smooth mucosal surface. Luminal contents are primarily anechoic. The cystic and common bile ducts are normal/not visible.

Gastrointestinal

The stomach contains a moderate volume of fluid and ingesta. It measures at a normal thickness of <0.7 cm with some variability due to the presence of rugal folds. The distinction of the gastric wall layers is adequate and there is no impression of reduced peristaltic activity. No masses or focal lesions were observed.

The visualized areas of duodenum, jejunum and ileum have a relatively uniform diameter with minimal fluid distension. Wall thickness is normal. Bowel loops follow a curvilinear path with distinct wall layering maintaining the typical 1:3 muscularis:mucosa layer ratio. The duodenum measured as normal (between 0.3-0.5 cm in wall thickness) and the jejunum measured as normal (0.36 cm) Visualized peristalsis appears appropriate. There were no focal lesions consistent with obstruction or a mass effect observed.

The ileocecal junction was visualized and exhibited normal intact wall layering and is subjectively of normal thickness. Sections of colon are visualized with formed fecal material and gas shadowing distally. There is no observed focal or generalized colon wall thickening or loss of layering.

Pancreas

The pancreas is normal and isoechoic to surrounding mesentery. There is no evidence of nodules or cystic lesions. There is no evidence of regional mesenteric inflammation or fluid.

Free Abdomen

Evaluation of the peritoneal cavity did not reveal any evidence of effusion. There are clusters of prominent hypoechoic lymph nodes at the root of the mesentery, measuring 0.73, 0.56, 0.41, 0.83, and 0.39 cm in diameter. The omentum is generally of normal echogenicity.

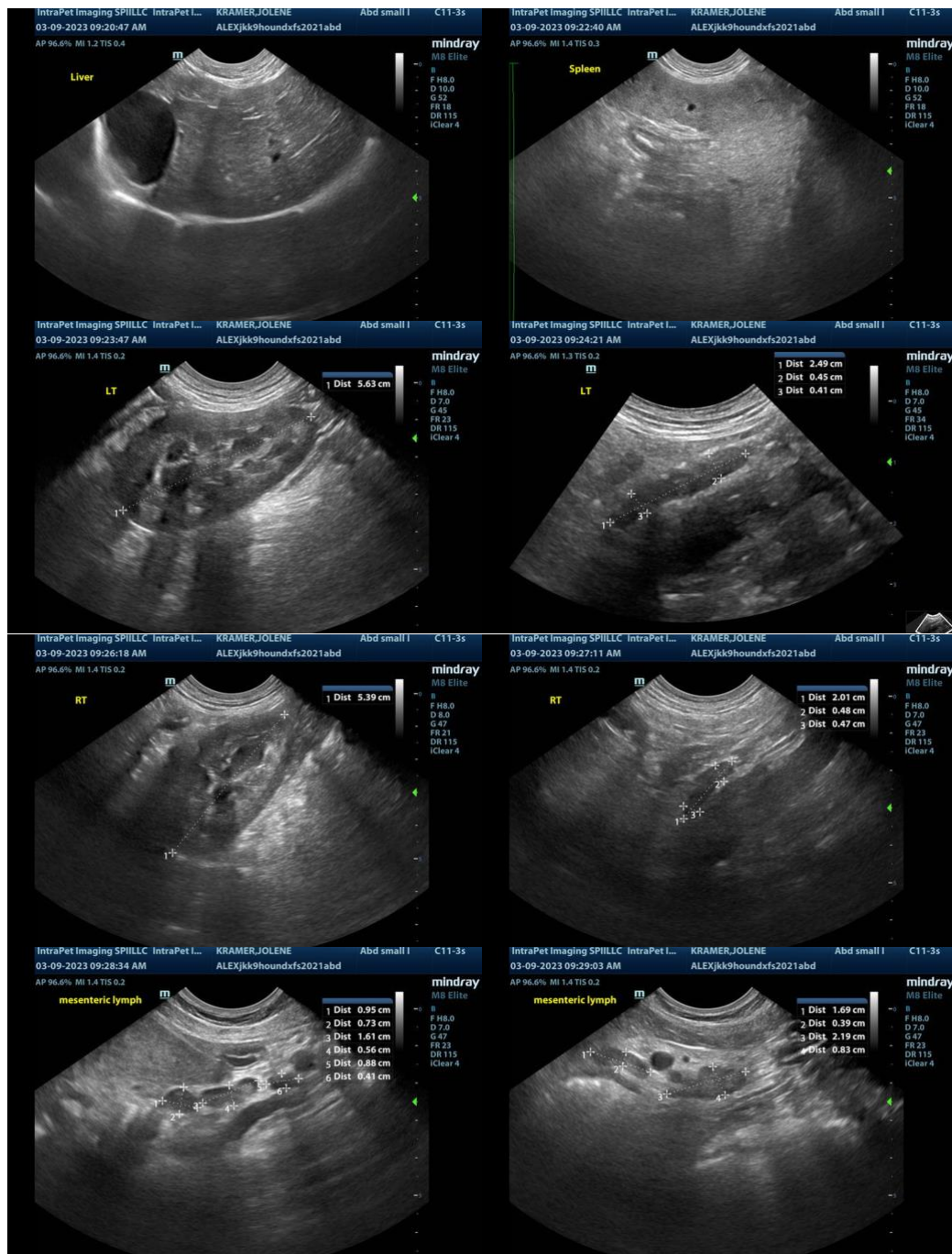
ULTRASONOGRAPHIC FINDINGS

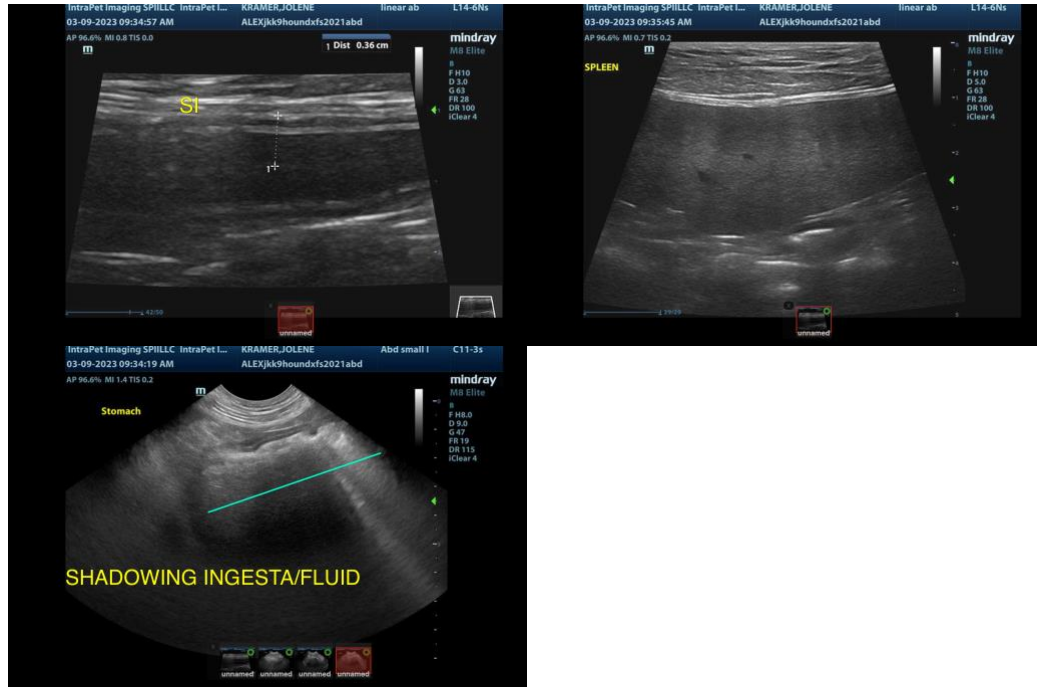
- Mildly mottled spleen. The diffuse splenic changes are non-specific and could be consistent with lymphoid hyperplasia, extramedullary hematopoiesis, infiltrative neoplasia, inflammation, other. Cytology or histopathology would be necessary to get a definitive diagnosis.
- Moderate fluid/ingesta visualized within the gastric lumen. Correlate with the feeding history and abdominal radiographs. If the patient was adequately fasted consider such differentials as delayed gastric emptying, a partial outflow tract obstruction (none seen) or ingested foreign material.
- Mild mesenteric lymphadenopathy. The prominent abdominal lymph nodes are most consistent with reactive lymphadenitis or lymphoid hyperplasia. Neoplastic infiltration is considered less likely.

INTERPRETATION OF THE FINDINGS & FURTHER RECOMMENDATIONS

Most of the lesions visualized are somewhat mild and/or subjective. A definitive cause for the symptoms described is not visualized. The spleen appears subjectively mildly mottled. A fine needle aspirate could be considered. Additionally, there are clusters of large mesenteric lymph nodes at the root of the mesentery. If a safe window, away from major vessels, can be obtained, consider a fine needle aspirate. There is a moderate amount of shadowing ingesta/fluid visualized within the gastric lumen, correlate this with the feeding history. If the patient was adequately fasted, then consider such differentials as delayed gastric emptying or partial outflow tract obstruction (none observed).

Consider such differentials as food allergy/dietary intolerance, GI parasitism, acute pancreatitis, dietary indiscretion, non-specific gastroenteritis, ingested foreign material, IBD and less likely neoplasia, etc. Recommend continued care for acute gastroenteritis with serial imaging, looking for any evidence of progressive foreign body obstruction, etc. If symptoms persist, GI biopsies may be recommended with evaluation for any foreign material.





The information and recommendations provided are based on the images presented by the referring veterinarian. No evaluation can be communicated regarding pathology that was not visible in the image/video clips provided.

Thank you for this referral. If the clinical or image interpretation does not parallel your findings or if I can be of any further assistance please contact me.

Kathleen Sennello DVM,MS, Diplomate ACVIM (Small animal Internal Medicine)
kathleen.sennello@sonopath.com