



**PATIENT**

Onyx Wadas

**SPECIES**

Canine

**BREED**

Husky

**SEX**

Neutered male

**AGE**

13 years

**WEIGHT**

79.2 lbs

**INTERPRETED BY**

Kathleen Sennello  
DVM, MS, Diplomate  
ACVIM (Small Animal  
Internal Medicine)

**IMAGING  
PERFORMED BY**

Jessica Miller, RDMS

**HOSPITAL NAME**

Summit Dog and Cat  
Hospital

**REFERRING VET**

Dr. Traci

**INVOICE**

96693

**DATE**

3/9/22

**PRESENTING CLINICAL SIGNS**

History: Abdominal mass. Current meds: cerenia, mirtazapine, gabapentin  
Abnormal PE/Chem/CBC/UA Results: WBC 5.87, Lym 0.76, PLT 572, MPV 6.8, Ca 13.1, TP 8.6,  
Albumin 4.4, Glob 4.2, Amylase 1971, K 6.0

**ULTRASONOGRAPHIC EXAMINATION OF THE ABDOMEN**

**Urinary System**

The urinary bladder is moderately distended with anechoic urine. The Bladder wall, trigone, ureteral papillae and visible urethra (to a depth of 2cm) appear normal with no evidence of wall thickening, mucosal irregularities, masses or cystic calculi.

The prostate is normal in size and shape for this neutered male dog. The parenchyma is homogenous and the external margins are smooth. The prostatic urethra appears normal with no evidence of irregularity, invasion, mass effect or calculi.

The left kidney has a normal shape and size (8.26 cm). Overall echogenicity is slightly hyperechoic with poor corticomedullary distinction and a typical 1:3 cortex:medulla ratio. There is no evidence of perinephric inflammation or effusion. There are too numerous to count small cortical cysts. There is no evidence of pyelectasia, nephroliths, infarcts or hydroureter. Renal vasculature is normal.

The right kidney has a normal shape and size (8.54 cm). Overall echogenicity is slightly hyperechoic with poor corticomedullary distinction and a typical 1:3 cortex:medulla ratio. There is no evidence of perinephric inflammation or effusion. There are too numerous to count small cortical cysts. There is no evidence of pyelectasia, nephroliths, infarcts or hydroureter. Renal vasculature is normal.

**Adrenal Glands**

The left adrenal gland is normal in size measuring 0.81 cm at the caudal pole It is observed in its normal position cranial to the left renal artery. It is normal in appearance (uniformly hypoechoic) and shape with no evidence of a mass effect.

The right adrenal gland is normal in size measuring 0.88 cm at the caudal pole It is observed in its normal position between the cranial aspect of the right kidney and the caudal vena cava. It is normal in appearance (uniformly hypoechoic) and shape with no evidence of a mass effect.

**Spleen**

The spleen is subjectively normal in size. The spleen echotexture is heterogenous and mottled, the splenic capsule is smooth with no irregularities. The blood flow through the hilus and splenic parenchyma appears normal. No focal parenchymal abnormalities are visualized.

**Liver**

The liver is subjectively normal in size, and echogenicity with smooth peripheral margins. The parenchyma is heterogenous in echotexture with subtle, indistinct focal mottling. The visible portions of the vasculature and biliary tract appear normal. There is a very large, solid, hyperechoic mass effect arising from the left side of the liver measuring > 16.89 x 15.8 cm. The gallbladder lumen is moderately



<b>PATIENT</b>	distended. The wall of the gallbladder is not thickened and has a smooth mucosal surface. Luminal contents are primarily anechoic. The cystic and common bile ducts are normal/not visible.
Onyx Wadas	
<b>SPECIES</b>	<b>Gastrointestinal</b>
Canine	The stomach contains minimal luminal contents. It measures at a normal thickness of <0.7cm with some variability due to the presence of rugal folds. The distinction of the gastric wall layers is adequate and there is no impression of reduced peristaltic activity. No masses or focal lesions were observed.
<b>BREED</b>	
Husky	The visualized areas of duodenum, jejunum and ileum have a relatively uniform diameter with minimal fluid distension. Wall thickness is normal. Bowel loops follow a curvilinear path with distinct wall layering maintaining the typical 1:3 muscularis:mucosa layer ratio. The duodenum measured as normal (between 0.3-0.5cm in wall thickness) and the jejunum measured as normal (between 0.2-0.47cm.)
<b>SEX</b>	Visualized peristalsis appears appropriate. There were no focal lesions consistent with obstruction or a mass effect observed.
Neutered male	
<b>AGE</b>	The ileocecal junction was visualized and exhibited normal intact wall layering and is subjectively of normal thickness. Sections of colon are visualized with formed fecal material and gas shadowing distally. There is no observed focal or generalized colon wall thickening or loss of layering.
13 years	
<b>WEIGHT</b>	<b>Pancreas</b>
79.2 lbs	The pancreas is normal and isoechoic to surrounding mesentery. There is no evidence of nodules or cystic lesions. There is no evidence of regional mesenteric inflammation or fluid.
<b>INTERPRETED BY</b>	<b>Free Abdomen</b>
Kathleen Sennello DVM, MS, Diplomate ACVIM (Small Animal Internal Medicine)	Evaluation of the peritoneal cavity did not reveal any evidence of effusion, or subjective lymphadenomegaly. The Medial iliac nodes appear normal and there was no evidence of a caudal aortic thrombus at the bifurcation. The omentum is of normal uniform echogenicity.
<b>IMAGING PERFORMED BY</b>	<b>Heart</b>
Jessica Miller, RDMS	A brief view of the heart was submitted. No pericardial effusion was seen.
<b>HOSPITAL NAME</b>	<b>ULTRASONOGRAPHIC FINDINGS</b>
Summit Dog and Cat Hospital	<b>PRIMARY FINDINGS:</b>
<b>REFERRING VET</b>	<ul style="list-style-type: none"> <li>• Large, hyperechoic, solid liver mass. The findings are suggestive of a primary hepatic tumor. These lesions can be benign or malignant.</li> </ul>
Dr. Traci	<ul style="list-style-type: none"> <li>• Mildly mottled spleen. The spleen is subjectively (normal or large) in size The spleen echotexture is heterogenous and mottled, the splenic capsule is smooth with no irregularities. The blood flow through the hilus and splenic parenchyma appears normal. No focal parenchymal abnormalities are visualized.</li> </ul>
<b>INVOICE</b>	
96693	
<b>DATE</b>	
3/9/22	



**PATIENT**

Onyx Wadas

**SPECIES**

Canine

**BREED**

Husky

**SEX**

Neutered male

**AGE**

13 years

**WEIGHT**

79.2 lbs

**INTERPRETED BY**

Kathleen Sennello  
DVM, MS, Diplomate  
ACVIM (Small Animal  
Internal Medicine)

**IMAGING  
PERFORMED BY**

Jessica Miller, RDMS

**HOSPITAL NAME**

Summit Dog and Cat  
Hospital

**REFERRING VET**

Dr. Traci

**INVOICE**

96693

**DATE**

3/9/22

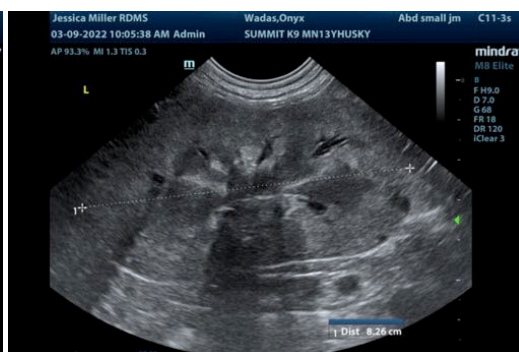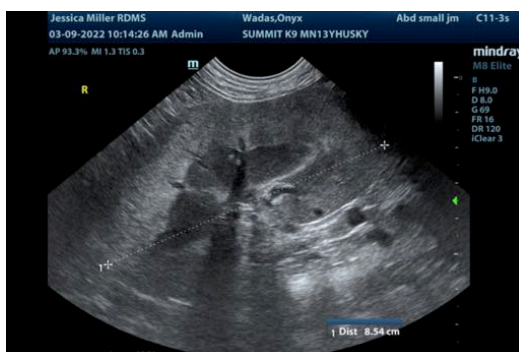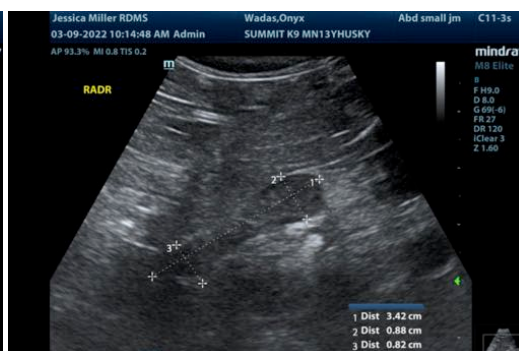
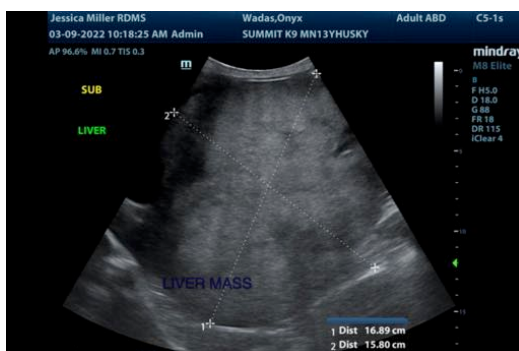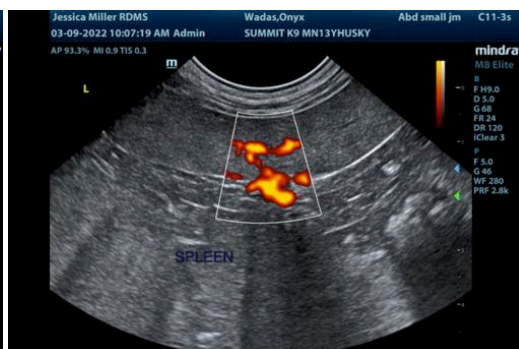
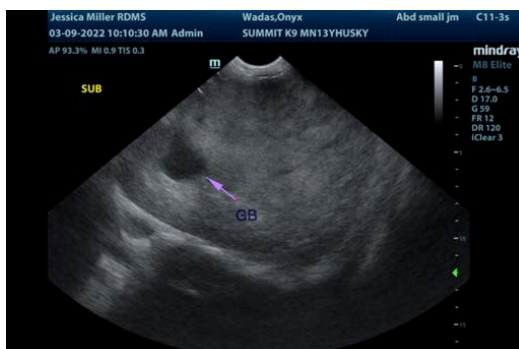**SECONDARY FINDINGS:**

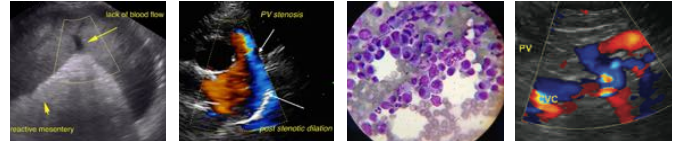
- Decreased corticomedullary distinction in both kidneys. The bilateral renal findings are consistent with age-related change.

**INTERPRETATION OF THE FINDINGS & FURTHER RECOMMENDATIONS**

A large mass effect is visualized from the left side of the liver. This is likely most consistent with a primary liver mass. These lesions can be very large and are slow to grow and can have a relatively favorable prognosis if they are able to be surgically removed and have not spread.

- Consider contrast CT scan to further evaluate the extent of this mass lesion. A FNA can be considered at the same time or prior to this procedure.
- Consider three view thoracic radiographs to rule out concurrent thoracic disease/involvement.





**PATIENT**

Onyx Wadas

**SPECIES**

Canine

**BREED**

Husky

**SEX**

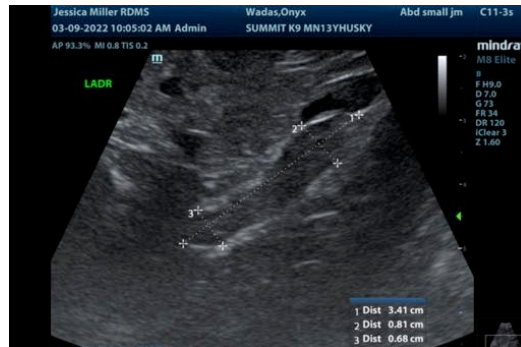Neutered male

**AGE**

13 years

**WEIGHT**

79.2 lbs



The information and recommendations provided are based on the images presented by the referring veterinarian/sonographer. No evaluation can be communicated regarding pathology that was not visible in the image/video clips provided.

Thank you for this referral. If the clinical or image interpretation does not parallel your findings or if I can be of any further assistance please contact me.

Kathleen Sennello DVM,MS, Diplomate ACVIM (Small animal Internal Medicine)

kathleen.sennello@sonopath.com

**INTERPRETED BY**

Kathleen Sennello  
DVM, MS, Diplomate  
ACVIM (Small Animal  
Internal Medicine)

**IMAGING  
PERFORMED BY**

Jessica Miller, RDMS

**HOSPITAL NAME**

Summit Dog and Cat  
Hospital

**REFERRING VET**

Dr. Traci

**INVOICE**

96693

**DATE**

3/9/22