

**DATE PRESENTING CLINICAL SIGNS**

3/9/22

P started having GI disturbance late October 2021 after consuming an everlasting treat. At that time, p was treated with metro and Provable. P responded well to treatment. O called back 1/2022 stating that p had diarrhea again. Was treated with Metro and Provable again. On 3/3/22 p diarrhea returned once again.

**PATIENT**

Landon Rizzo

Current Medications: Provable DC caps SID.

Lab Results: 10/29/21 fecal negative. 3/7/22 TP 4.5, Alb 2.2, Glo 2.3.

Date of Previous IntraPet Ultrasound: No previous.

Sedation: Not required to complete full diagnostic ultrasound.

Stat Report: Not requested.

**SPECIES**

Canine

**BREED**

Yorkshire Terrier

**SEX**

Neutered Male

**AGE**

8/16/16

**WEIGHT**

12.8 Pounds

**INTERPRETED BY**

Kathleen Sennello DVM,  
MS, Diplomate ACVIM  
(Small Animal Internal  
Medicine)

**IMAGING PERFORMED BY**

Andi Parkinson RDMS

**HOSPITAL NAME**

Northwind AH

**REFERRING VET**

Dr. Wilson

**INVOICE**

35964

**ULTRASONOGRAPHIC EXAMINATION OF THE ABDOMEN****Urinary System**

The urinary bladder is minimally distended with anechoic urine. Bladder wall, trigone, ureteral papillae and visible urethra (to a depth of 2cm) appear normal with no evidence of wall thickening, mucosal irregularities, masses or cystic calculi.

The visualized areas of prostate and surrounding tissue appear normal. Unfortunately, the prostate is not fully visualized likely due to its intrapelvic location. Correlate with rectal exam findings.

The left kidney has a normal shape and size (3.94 cm). Overall echogenicity is normal with adequate corticomedullary distinction and a typical 1:3 cortex:medulla ratio. There is no evidence of perinephric inflammation or effusion. There is no evidence of pyelectasia, nephroliths, infarcts or hydroureter. Renal vasculature is normal.

The right kidney has a normal shape and size (3.61 cm). Overall echogenicity is normal with adequate corticomedullary distinction and a typical 1:3 cortex:medulla ratio. There is no evidence of perinephric inflammation or effusion. There is no evidence of pyelectasia, nephroliths, infarcts or hydroureter. Renal vasculature is normal.

**Adrenal Glands**

The left adrenal gland is normal in size measuring 0.49 cm at the caudal pole. It is observed in its normal position cranial to the left renal artery. It is normal in appearance (uniformly hypoechoic) and shape with no evidence of a mass effect.

The right adrenal gland is normal in size measuring 0.40 cm at the caudal pole. It is observed in its normal position between the cranial aspect of the right kidney and the caudal vena cava. It is normal in appearance (uniformly hypoechoic) and shape with no evidence of a mass effect.

**Spleen**

The spleen is subjectively normal in size, echotexture is homogenous, and the splenic capsule is smooth with no irregularities. The blood flow through the hilus and splenic parenchyma appears normal. No focal parenchymal abnormalities are visualized.

**Liver**

The liver is subjectively normal in size, and echogenicity with smooth peripheral margins. The parenchyma is homogenous echotexture. The visible portions of the vasculature and biliary tract appear normal. No focal nodules or cystic lesions are observed.

The gallbladder lumen is moderately distended. The wall of the gall bladder is not thickened and has a smooth mucosal surface. Luminal contents are primarily anechoic. The cystic and common bile ducts are normal/not visible.

### ***Gastrointestinal***

The stomach contains minimal luminal contents. It measures at a normal thickness of <0.7cm with some variability due to the presence of rugal folds. The distinction of the gastric wall layers is adequate and there is no impression of reduced peristaltic activity. No masses or focal lesions were observed.

The visualized areas of duodenum, jejunum and ileum have a uniform diameter with minimal fluid distension. Wall thickness is normal to slightly increased. Bowel loops follow a typical curvilinear path with distinct wall layering, but some areas display a prominent muscularis layer which does not display the typical 1:3 muscularis:mucosa layer ratio. Duodenum wall measured 0.43 cm. Jejunum wall measured 0.33 cm. There is mucosal fogging evident in the duodenum. Visualized peristalsis appears appropriate. There were no focal lesions consistent with obstruction or a mass effect observed.

The ileocecal junction was visualized and exhibited normal intact wall layering and is subjectively of normal thickness. Sections of colon are visualized with formed fecal material and gas shadowing distally. There is no observed focal or generalized colon wall thickening or loss of layering.

### ***Pancreas***

The pancreas is normal and isoechoic to surrounding mesentery. There is no evidence of nodules or cystic lesions. There is no evidence of regional mesenteric inflammation or fluid.

### ***Free Abdomen***

Evaluation of the peritoneal cavity did not reveal any evidence of effusion, or subjective lymphadenomegaly. The Medial iliac nodes appear normal and there was no evidence of a caudal aortic thrombus at the bifurcation. The omentum is of normal uniform echogenicity.

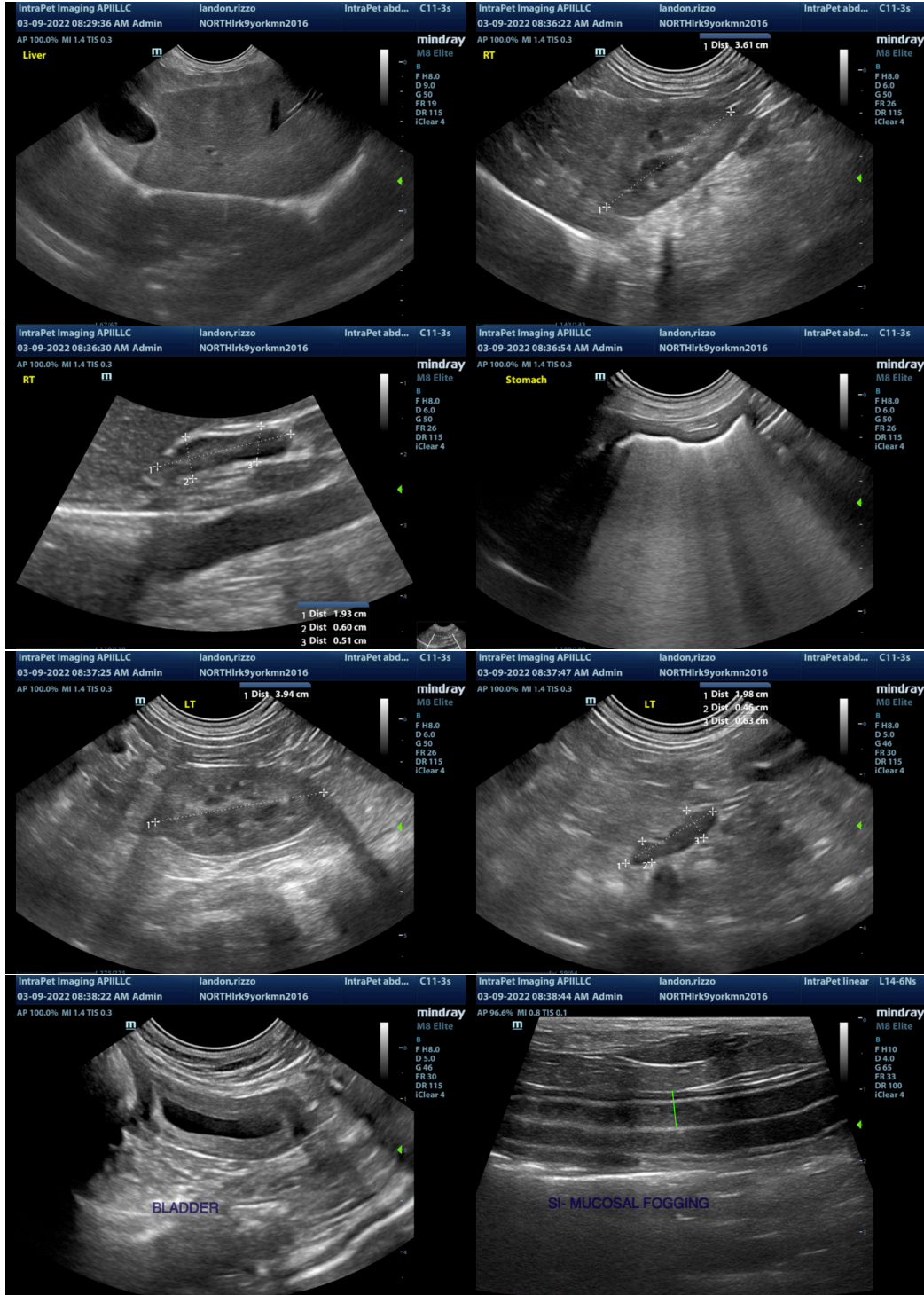
## **ULTRASONOGRAPHIC FINDINGS**

- Moderately thickened small intestine with some mucosal fogging – The bowel wall thickening could be consistent with inflammation, edema, or infiltrative neoplasia.

## **INTERPRETATION OF THE FINDINGS & FURTHER RECOMMENDATIONS**

Based on the history and lab work provided, the ultrasound findings are most consistent with a protein losing enteropathy, although typically in this breed I would recommend pre- and post-prandial bile acids to screen for any hepatic dysfunction and urine protein/creatinine ratio to look for any evidence of concurrent proteinuria.

- Consider a GI panel to Texas A&M for qualitative PLI, TLI, cobalamin and folate to further evaluate the small intestine and pancreas.
- Recommend chronic probiotic therapy.
- Consider three view thoracic radiographs to rule out concurrent thoracic disease/involvement.
- In a patient this age with hypoalbuminemia and chronic GI disease, I would recommend obtaining GI biopsies to obtain diagnosis and try to differentiate from such disease processes as IBD, lymphangiectasia, and much less likely intestinal neoplasia.
- Dietary recommendations would be based on the diagnosis, either ultra low-fat or a novel protein/hydrolyzed protein prescription diet.



The information and recommendations provided are based on the images presented by the referring veterinarian/sonographer. No evaluation can be communicated regarding pathology that was not visible in the image/video clips provided.

Thank you for this referral. If the clinical or image interpretation does not parallel your findings or if I can be of any further assistance please contact me.

Kathleen Sennello DVM,MS, Diplomate ACVIM (Small animal Internal Medicine)  
kathleen.sennello@sonopath.com